


Date: 15.06.2022

Dear B.B. Khasanov, F.Kh. Azizova, D.R. Sobirova, A.N. Otajonova, P.Kh. Azizova

Title: **TOXIC HEPATITIS OF THE FEMALE AND THE STRUCTURAL AND FUNCTIONAL FORMATION OF THE LEAN INTESTINE OF OF THE OFFSPRING IN THE PERIOD BREASTFEEDING**

We pleased to inform you that your above mentioned article has been accepted for publication in **NeuroQuantology**.

Regards



Editor  
NeuroQuantology



# Toxic Hepatitis of the Female and the Structural and Functional Formation of the Lean Intestine of the Offspring in the Period Breastfeeding

B.B. Khasanov<sup>1\*</sup>, F.Kh. Azizova<sup>2</sup>, D.R. Sobirova<sup>3</sup>, A.N. Otajonova<sup>4</sup>, P.Kh. Azizova<sup>5</sup>

## Abstract

Despite ongoing therapeutic and preventive measures, chronic hepatitis of viral etiology still makes up a significant proportion of extra genital pathology among women of childbearing age. On sexually mature female white outbred rats before pregnancy, chronic heliothrine intoxication was created, leading to the development of chronic aggressive hepatitis. The influence of maternal hepatitis on the structural and functional development and enzymatic activity of the jejunum of the lean intestine of the offspring during breastfeeding was researched. Morphological studies have established that a decrease in the average number of villi on a transverse section of the intestine, a decrease in the height of the villi, a decrease in the average number of enterocytes (EC) on a transverse section of the crypt, a decrease in the thickness of the mucous membrane and muscular-serous membranes progressing up to 15 days and a decrease in the height of the EC of the middle third of the crypts to 7 days of development of rat pups. It was also established a decrease in the average number of EC on a longitudinal section of the crypt and villus, and a decrease in the number of mitotically dividing cells up to 21 days of development. That is, structurally revealed a lag in the development of the jejunum in the period of early postnatal ontogenesis, progressing to the transition of rat pups to mixed and definitive nutrition. In functional researches in the offspring of females with chronic toxic hepatitis, a delay in the natural age-dependent induction of the basal level of enteral enzymes: maltase,  $\gamma$ -amylase, sucrose and inhibition of lean intestine lactase during lactation was established. The authors believe that chronic maternal hepatitis leads to lactase deficiency in the offspring, which can lead to widespread diarrhea and other diseases of the gastrointestinal tract in children worldwide.

3489

**Key Words:** Hepatitis, Milk, Lactation, Proteins, Carbohydrates, and Offspring, and Lean Intestine, Enzymes: Maltase,  $\gamma$ -amylase, Sucrose, and Lactase.

DOI Number: 10.14704/nq.2022.20.6.NQ22354

NeuroQuantology 2022; 20(6):3489-3496

## Introduction

It is known that the neonatal period is especially important for the development of the body, since after birth, babies are immediately exposed to a large number of microorganisms. High rates of morbidity and mortality observed in the first months of life due to infectious diseases such as otitis media, infections of the upper and lower respiratory tract, gastroenteritis, sepsis and meningitis are due, among other things, to significant quantitative and qualitative deficiencies in various components of the immune system. To compensate for this immunological immaturity

inherent in the period of the fetus and newborn, as well as the first months of life, nature has developed ideal adaptive defense mechanisms provided by the mother, represented by the transplacental transfer of antibodies, anti-infection resistance factors in the amniotic fluid, and after birth, in colostrum and milk. Nevertheless, unfortunately, this whole system of harmonious genetically determined processes, inherent in the physiological course of pregnancy and the postpartum period, ceases to work in the event of the influence of unfavorable factors, infectious effects, and extra genital pathology of the mother.

Corresponding author: B.B. Khasanov

Address: <sup>1\*,2,3,4,5</sup>Tashkent Medical Academy, Tashkent, Uzbekistan.



In particular, it was found that one of the most frequently reported diseases of the digestive system among women of childbearing age are diseases of the hepatobiliary system. In most works, including our previous studies, it has been shown that chronic hepatitis in pregnant female has an adverse effect on offspring - it delays its physical development, reduces resistance, and inhibits the formation of its structural and cytochemical properties of the stomach, immune organs, intestines, and kidneys [1, 2, 3, 4, 5, 6, 7]. Based on the foregoing, it follows that the research of the structural and functional features of the digestive organs in offspring born and fed by hepatitis mothers is a very relevant medical and biological problem for modern pediatric gastroenterology. At the same time, the structural and functional condition of the digestive organs in postnatal hepatitis is still poorly understood. Meanwhile, without detailed knowledge of the mechanisms of influence of a particular pathology on the processes of formation of the digestive system of a developing organism, it is difficult to develop methods for diagnosing and treating childhood diseases, including hepatitis, acquired during the period of placental-amniotrophic and lactotrophic nutrition.

Due to this, the purpose of our research was to study the structural and functional features of the development of the lean intestine in the offspring of rats born from females with toxic hepatitis during breastfeeding (early postnatal ontogenesis).

### Materials and Research Methods

The experiments were carried out on 120 adult white outbred rats - females weighing 120-150 g. The animals were kept on a standard diet in vivarium conditions. A model of heliothrin hepatitis was obtained by weekly administration of 0.05 mg of heliothrin per gram of animal weight for 6 weeks [8, 9]. 10 days after the last inoculation, the rats were mated to produce offspring. The experimental group consisted of rats born to mothers with chronic toxic hepatitis (CTH). The control was rat pups born to mothers who received an appropriate amount of isotonic solution at the same time instead of heliothrin. The animals were kept in separate cages, for the reliability of the results obtained; the litter was left at the rate of eight cubs per lactating female. For the study, rat pups obtained from the control and experimental groups of females, which were decapitated, after

preliminary euthanasia under ether anesthesia, on days 1, 3, 7, 15, 21 and 30 after birth, were used to research the enzymatic activity of the jejunum intestine (1 daily rats after breastfeeding). After decapitation, the animal's abdominal cavity was opened, then the small intestine was separated, and samples of the jejunum of the small intestine were used for further studies. When determining the activities of intestinal enzymes proper, biochemical methods were used, which are widely used in modern experimental gastroenterology.  $\alpha$ -amylase activity in the contents of the lean intestine was determined by the Smith and Roy method modified by A.M. Ugolev [10]. The principle of the method was to quantify the starch remaining after enzymatic hydrolysis and forming a blue complex compound with iodine. The concentration of the latter was quantitatively measured calorimetrically. Enzymatic activity was expressed in milligrams of substrate digested in 1 min. The activity of all intestinal enzymes maltase, sucrose, lactase and  $\gamma$ -amylase was determined by the glucose oxidase method. For the first three enzymes, the Dahlquist method [11] was used, and for the last one, the method of Auricio and Rubino [12]. The method is based on the quantitative determination of glucose released from the corresponding substrates after enzymatic hydrolysis. For morphological and morphometric studies, samples of the jejunum of rat pups were fixed in a 10% solution of neutral formalin and Bouin's liquid. The pieces were dehydrated in alcohol and xylene of increasing concentration, and then they were embedded in paraffin. Histological sections 5-8  $\mu$ m thick were stained with hematoxylin and eosin. Morphometric study was performed on serial sections using an eyepiece micrometer. All data were statistically processed using computer programs to calculate the arithmetic mean (M), mean error of the mean (m) and fidelity indicators (P) according to Fischer and Student.

### Results

The results of our morphological researches have shown that the lean intestine of newborn rat pups has its own characteristic features. Particularly, the intestines of 1day old rat pups have a thin wall, in which the mucosa, submucosa, internal and external muscular membranes are clearly distinguished. The inner muscle layer of the latter is more developed than the outer, covered with a serous membrane. It is characteristic that the



mucous membrane of the lean intestine is formed by villi, which are at different stages of formation and can be triangular, finger-like, filiform. With elongation, their epithelial layer on them becomes single-row. Basically, the emerging villi retain the multi-row arrangement of nuclei in the basal part of the epithelial cells. The crypts in the jejunum are still being formed. Formed villi of the correct finger-shaped form, without folding on the lateral surfaces. The characteristic relief of the mucous membrane increases its surface and creates favorable conditions for digestion and absorption.

In the future, on the 3-7th day of postnatal development, the most significant changes in the mucous membrane of the lean intestine occur due to an increase in its thickness, as well as the thickness of the muscle layer, the growth of the resulting villi and crypts, the redistribution of their relative number depending on the linear parameters, a sharp decrease over time in low villi and shallow crypts.

Subsequently, on the 15th day of postnatal development, all structures of the lean intestine in rat pups of the control group were practically formed (see Fig. A and B). Their morphometric parameters are presented in the table. Bordered epithelial cells covering the villi had a highly prismatic shape, their brush border appeared as a thin, clearly visible, brightly oxyphilic strip. Oval-shaped nuclei with a clearly manifested structure were placed very compactly at the same level, closer to the basal pole. The nuclear chromatin is small-lumpy, evenly distributed throughout the karyoplasm. 1-2 nucleoli were clearly visible, usually located in the center. It was observed that the nuclei, as well as the epitheliocytes themselves, decreased in the direction of the tops of the villi, the cytoplasm was subjected to microvacuolization, its oxyphilic properties decreased, which indicated the physiological renewal of the epithelium.

For the period of transition of rats to definitive nutrition, that is, starting from 21 days after birth, the morphological structure of the mucous membrane of the small intestine became almost similar to that in mature animals. At the same time, an increase in the length and diameter of the small intestine was noted. While maintaining the overall architectonics of the mucous membrane, this contributed to a proportional increase in the number of villi and crypts and, consequently, the same sensitivity to the stimulating effect of food on the digestive-absorptive surface of the organ. An even greater development of the structural

components of the jejunum occurred on the 30th day of postnatal development.

The research of the lean intestine in the offspring of females with CTH made it possible to establish that, although at first glance, pronounced morphological changes were not established that would sharply contrast with the lean intestine of the rat pups of the control group. At the same time, the conducted morphometric researches indicate that in the offspring obtained from the females of the experimental group, during the period of early postnatal ontogenesis, there was a delay in the development of the jejunum. In particular, it was found: a decrease in the average number of villi on the transverse section of the intestine, a decrease in the height of the villi, a decrease in the average number of enterocytes (EC) on the transverse section of the crypt, a decrease in the thickness of the mucous membrane and muscular-serous membranes up to 15 days and a decrease in the height of the EC in the middle third of the crypts up to 7 days development of rat pups. It was also found to decrease: the average number of EC on the longitudinal section of the villus, the height of EC in the middle third of the villus, the number of EC on the longitudinal section of the crypt, the depth of the crypts and a decrease in the number of mitotically dividing cells up to 21 days of development. Along with this, there was an increase in the relative number of goblet cells in the villi of the lean intestine of rats born and fed by females with chronic toxic hepatitis up to 21 days of development (see Table 1).

In the research of the morphological features of the lean intestine of 15-day-old rat pups, from the females of the experimental group, a delay in the development of the jejunum was noted (see Fig. C and D). A decrease in wall thickness than in the control, a pronounced polymorphism of the villi and a decrease in their height, for crypts that looked like short tubes, a more rare arrangement was characteristic. The bordered epithelial cells lining the villi were lower, with reduced oxyphilic properties of the cytoplasm, with a thinned brush border, which was hardly visible. With reduced nuclei of rounded epitheliocytes, located at a greater distance from each other relative to the control. At the same time, there was a large number of goblet cells, cylindrical in shape with weakly basophilic cytoplasm. The villi were characterized by an edematous stroma with a slight leukocyte infiltration, where tissue basophils were determined much more often than in the control.

Hemocapillaries were moderately dilated. A loose arrangement of underdeveloped crypts was observed, having the form of short tubular formations, lined with epitheliocytes smaller in height than in the control, with weakly basophilic reduced nuclei.

In the next 21-30 days of development, there was a stabilization of the structural components of the jejunum of the rat pups of the experimental group.

In addition, we found that rat pups born from females with CTH in the early periods of milk feeding, in particular, on the 3rd day after birth, have a lower specific activity of not only a number of  $\alpha$ -glucosidases (enteral maltase,  $\gamma$ -amylase, sucrose), but also lactase, responsible for membrane hydrolysis of the only carbohydrate present in milk: 23% lower than control. Therefore, we can state with some certainty that chronic toxic hepatitis of the mother leads to lactase deficiency in the offspring, which is the cause of diarrhea and other diseases of the gastrointestinal tract in children that are widespread in the world. In other words, by the time of the transition to solid food, about 50% of which consists of poly and oligosaccharides [13, 14, 10], growing offspring are faced with the fact of weakened or reduced activity, the corresponding enzymatic activities. Such an enzymatic deficiency is usually accompanied by maldehystia and / or malabsorption in relation to "definitive" carbohydrates, starch, maltose, sucrose, etc. [15, 16], with all the serious diseases resulting from them, leading to high infant mortality.

## Discussion

Analyzing the results obtained, it is necessary to point out that for the full development of the baby, starting from the first day after birth, protein components are needed: the "basic plastic material", and, of course, easily digestible carbohydrates of mother's milk. The enzymes of colostrum and milk that enter the body of a newborn during breastfeeding also have a beneficial effect on the processes of its adaptation, affecting the metabolism of proteins and carbohydrates in the intestine [10, 13, 14, 15]. In addition, a certain dynamic of the level of hormones in milk is revealed, associated with their participation in the process of metabolic adaptation of newborns to extra uterine existence and causing the restructuring of protein, carbohydrate and fat metabolism in the postnatal period [16, 17]. As we noted in our previous studies, chronic toxic

hepatitis of the mother has a negative effect on lactation processes, where there is a decrease in the amount of protein, carbohydrates and a decrease in the enzymatic activity of milk, there is a decrease in the number of cellular components that also come with mother's milk to the baby [18, 19]. The decrease in cellular components, apparently, is one of the factors characterizing the decrease in the immunomodulatory function of milk. It is possible that the above reasons contribute to the steady decrease in body weight gain, established by many studies, and the lag in the structural and functional development of the small intestine, immune organs, liver, and kidneys in the offspring of rats with chronic hepatitis [20, 21, 22, 23, 24, 1, 2]. In addition, a decrease in the number of macrophages, monocytes and lymphocytes, contributing to the disruption of the transfer of adoptive immunity. Also, as indicated in our previous studies, the supply of lysosomes, lipid droplets, present in these cells, is significantly reduced. As a result, the trophic influence and immunobiological properties of breast milk are significantly reduced, allowing the child to adapt and survive in the "world of microbes", which he enters immediately after birth [25, 26, 27].

Along with the above, with hepatitis, profound changes in metabolic processes occur, including a violation of protein metabolism, which naturally affects the hormonal balance, and, consequently, the development of the placenta and mammary gland, as well as developing offspring. It is also necessary to take into account the immunodeficient condition of the mother in hepatitis, it becomes clear what is the reason for the lag in the development of the digestive and immune systems of the offspring, established by many researchers [28, 29, 30, 31, 32, 33, 34]. In addition, it has been shown that the process of chronic heliotrine hepatitis is accompanied by profound morphological changes in the body's immune system. These changes lead to an imbalance between the T and B systems of the immune system and the development of an autoimmune process [35]. Summarizing all the above causal relationships, we can assume that they could contribute to the morphological changes in the small intestine of the offspring of mothers with chronic toxic hepatitis.

The results obtained by us also allow us to discuss another very important issue related to the assessment of the functional maturity of the small intestine in offspring that have undergone



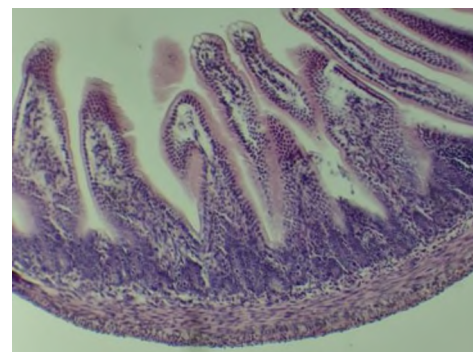


intrauterine exposure to toxic maternal hepatitis. In the modern literature on pediatric gastroenterology and nutrition, there is now a very convincing opinion that the ratio of lactase activity to  $\alpha$ -glucosidases, in particular, to maltase, is one of the objective indicators of the functional maturity of the small intestine. It is believed that the higher the degree of organ maturity, the lower the value of the lactase:maltase activity index [10, 13,14]. In our experiments, in rat pups born and fed by hepatitis females, the gradual decrease in lactase activity somewhat slowed down with age and, as a result, at 21 days of age, that is, by the time they switched to adult food, lactase activity was  $5.4 \pm 0.53$   $\mu\text{mol}/\text{min}/\text{g}$  in the experiment against  $3.6 \pm 0.33$  in the control, while maltase activity at this age was  $9.2 \pm 0.88$   $\mu\text{mol}/\text{min}/\text{g}$  in the experiment against  $16.9 \pm 1.11$  in control. In other words, it is clearly seen here that the ratio of lactase to maltase in rat pups from females with CTH is significantly higher (0.57) than in rat pups of the control group (0.21). Therefore, maternal CTH leads to a slowdown in the functional maturation of the small intestine in offspring during late pre- and early postnatal ontogenesis.

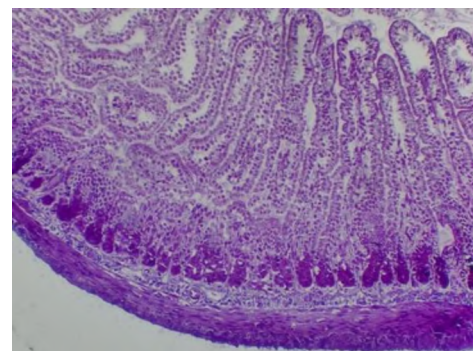
Therefore, based on the literature data on the increase in the permeability of the placenta in pregnant women in pathological conditions, the low barrier function of the gastrointestinal tract in fetuses, and analyzing our results, we believe the following. Hepatotoxins introduced into the mother's body before pregnancy, and possibly endotoxins formed during hepatitis, enter the blood of the fetus through the placenta and / or amniotic fluid, that is, through the digestive organs and have an inhibitory effect on its growth and development, as well as on the formation of the morphology and function of the digestive system. As shown by the observations and experiments of numerous authors, endotoxins formed in the body of a sick mother, as well as exogenous toxins, are transmitted to offspring during breastfeeding through mother's milk. Illustrative examples are the detection in breast milk of a number of peptides, hormones, enzymes, as well as various kinds of anthropogenic substances (herbicides, fungicides, insecticides and other toxins). Therefore, it should be assumed that the shifts that we found in growing animals are somehow mediated by the influence of both local and general regulatory systems in the body. This is all the more likely because, judging by modern data, organs during intrauterine life are very sensitive to the

influence of various exogenous and endogenous factors (hormonal status of the body, stress effects, changes in blood supply, etc.) [36, 37, 38, 39, 40].

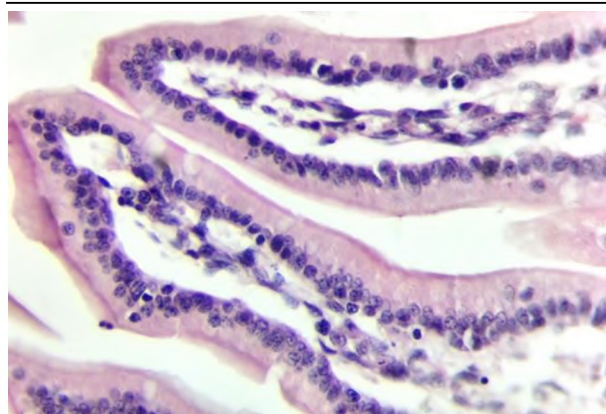
In this way, it can be concluded that maternal toxic hepatitis during breastfeeding has a negative effect on the development of the lean intestine of rat pups, which is expressed in the lag of the structural and functional development of the jejunum, a pronounced lag in the development of structural components, "crypt-villous" relationships, delays natural age dependent induction of the basal level of intestinal maltase,  $\gamma$ -amylase and sucrose and inhibition of lactase activity during lactation. Therefore, it can be argued that chronic maternal hepatitis leads to lactase deficiency in the offspring, which is the cause of widespread diarrhea and other diseases of the gastrointestinal tract in children worldwide. Such an enzymatic deficiency is usually accompanied by malabsorption and/or malabsorption in relation to "definitive" carbohydrates, starch, maltose, sucrose, etc., with all the resulting severe diseases leading to high infant mortality. Therefore, for children born from mothers with hepatitis, it would be more appropriate to start preventive therapeutic measures to prevent the pathology of the gastrointestinal tract of newborns from the period of breastfeeding.



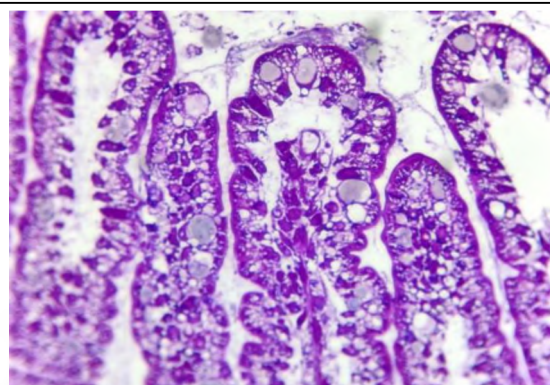
A



B



C



D

Figure: A. The lean intestine of a 15 day old rat of the control group. Hematoxylin-eosin staining, Magnification: x 100; B. The lean intestine of a 15 day old rat in the experimental group. Hematoxylin-eosin staining. Magnification: x 100; C. Villus of lean intestine of a 15-day old rat of the control group. Hematoxylin-eosin staining, Magnification: x 200; D. Villus of lean intestine of a 15-day old rat in the experimental group. Hematoxylin-eosin staining, Magnification: x 200

**Table 1.** Structural and functional formation of the lean part of the small intestine of offspring born to females rats with chronic toxic hepatitis in the dynamics of early postnatal ontogenesis

Investigated parameters	A group of animals	Rat pups age (in days)					
		1	3	7	15	21	30
The number of villi on a transverse section of the intestine	Contr.	25,4±0,72	28,3±0,86	31,5±0,78	38,2±0,65	46,7±2,4	50,8±1,76
	Exper.	<b>21,6±0,67</b>	<b>24,8±0,56</b>	<b>26,3±0,75</b>	<b>32,8±0,87</b>	42,4±1,41	48,8±1,66
Number of ECs. on 1 side of the longitudinal section of the villi	Contr.	47,2±0,24	51,2±1,88	65,2±2,48	73,2±2,62	78,5±3,62	91,4±4,82
	Exper.	<b>31,4±0,24</b>	<b>34,8±1,36</b>	<b>41,6±1,46</b>	<b>60,8±1,38</b>	<b>67,0±2,56</b>	88,6±3,65
The height of villus	Contr.	292,5±3,35	302,4±3,11	361,0±2,82	444,2±6,13	461,4±4,12	485,3±11,33
	Exper.	<b>265,6±2,26</b>	<b>273,4±2,12</b>	<b>318,2±4,18</b>	<b>363,5±3,54</b>	452,6±4,22	472,5±9,33
ECs height (µm) in the middle third of the villi	Contr.	21,5±0,95	22,0±0,82	22,3±0,94	23,8±0,93	26,1±0,43	37,6±0,62
	Exper.	<b>18,4±0,65</b>	<b>18,8±0,65</b>	<b>19,3±0,62</b>	<b>20,5±0,82</b>	<b>21,8±1,11</b>	36,6±1,43
Refers to the number of gobl. cl. on the villi (per 100 cells)	Contr.	1,6±0,06	5,8±0,18	7,6±0,26	9,1±0,17	10,8±0,19	14,4±0,26
	Exper.	—	<b>10,0±0,18</b>	<b>13,2±0,21</b>	<b>14,6±0,21</b>	<b>13,9±0,23</b>	<b>23,5±0,28</b>
The number of crypts on a transverse section of the intestine	Contr.	45,2±0,98	49,2±1,34	59,6±1,45	84,3±3,90	126,4±6,20	135,4±9,32
	Exper.	<b>38,6±0,81</b>	<b>43,2±0,91</b>	<b>50,1±1,28</b>	<b>72,7±1,86</b>	118,9±8,45	131,1±6,55
Number of ECs of the longitudinal section of the crypt	Contr.	6,7±0,61	7,5±0,33	9,2±0,43	12,2±0,45	35,8±1,23	42,2±0,86
	Exper.	<b>4,8±0,14</b>	<b>5,2±0,21</b>	<b>6,0±0,12</b>	<b>10,2±0,43</b>	<b>29,8±1,30</b>	41,7±0,65
Number of ECs on the cross section of the crypt	Contr.	7,7±0,61	8,9±0,11	14,6±0,93	19,4±0,92	20,1±1,32	21,7±0,65
	Exper.	<b>5,6±0,13</b>	<b>6,4±0,12</b>	<b>9,9±0,15</b>	<b>15,9±0,75</b>	18,7±0,94	19,9±0,34
Depth of crypts	Contr.	21,5±0,21	28,4±0,22	43,8±0,62	74,1±0,55	189,3±3,33	202,4±4,06
	Exper.	<b>16,4±0,12</b>	<b>22,8±0,56</b>	<b>32,4±1,08</b>	<b>65,3±0,62</b>	<b>148,3±2,65</b>	196,2±3,13
Height (µm) in the middle third of crypts	Contr.	16,2±0,31	16,1±0,65	16,0±0,51	15,6±1,05	15,7±1,30	17,3±0,95
	Exper.	<b>13,0±0,26</b>	<b>13,1±0,32</b>	<b>13,3±0,43</b>	13,9±0,95	14,6±1,25	16,8±0,23
The number of mitoses (per 1000 cells)	Contr.	14,4±0,43	21,6±0,78	23,4±0,98	26,4±0,83	21,6±0,62	18,4±0,92
	Exper.	<b>10,4±0,28</b>	<b>13,6±0,61</b>	<b>14,4±0,52</b>	<b>14,2±0,48</b>	<b>16,2±0,37</b>	15,9±0,38
Mucosal thickness	Contr.	306,4±4,11	318,2±2,13	375,6±9,46	462,4±11,34	498,8±16,22	507,6±13,85
	Exper.	<b>288,4±2,56</b>	<b>293,6±3,44</b>	<b>346,2±4,18</b>	<b>383,6±7,06</b>	473,2±13,11	505,3±15,18
Serous-muscular thickness	Contr.	76,2±1,45	82,3±2,45	94,5±4,32	116,4±3,82	124,6±5,65	136,6±7,55
	Exper.	<b>68,2±1,66</b>	<b>72,8±2,21</b>	<b>77,4±3,22</b>	<b>103,2±3,21</b>	114,8±4,54	125,4±6,65

**Note:** 1) Contr. and Exper. – Control and Experimental group of animals; ECs - enterocytes; Gl. cl.- goblet cells.

2) The values where the differences are significant relative to the control at P <0.05 are highlighted in bold.



**Table 2.** Influence of toxic hepatitis on the specific activity of enteral carbohydrases in the lean intestine is reflected in the dynamics of early postnatal ontogenesis ( $X \pm X_m$ , for enzymes in  $\text{mkmol} / \text{min} / \text{gram protein}$ , at  $n \pm 10$ )

Carbohydrases	A group of animals	Rat pups age (in days)					
		1	3	7	15	21	30
Maltase	Contr.	3,5±0,26	3,2±0,25	2,6±0,22	4,9±0,35	16,9±1,11	19,5±1,80
	Exper.	2,9±0,32	2,5±0,18	1,9±0,15	<b>2,8±0,21</b>	<b>9,2±0,88</b>	18,3±1,65
γ-amylase	Contr.	1,8±0,16	1,6±0,10	1,5±0,25	2,3±0,19	9,5±0,76	17,2±1,34
	Exper.	1,4±0,08	1,1±0,10	<b>0,9±0,08</b>	<b>0,7±0,08</b>	6,5±0,68	<b>10,6±0,16</b>
Saharaza	Contr.	—	—	—	—	4,0±0,32	6,2±0,45
	Exper.	—	—	—	—	<b>2,0±0,11</b>	<b>3,4±0,28</b>
Laktase	Contr.	7,9±0,72	7,5±0,54	7,3±0,61	6,4±0,62	3,6±0,33	1,2±0,08
	Exper.	5,2±0,65	<b>5,4±0,51</b>	7,2±0,63	6,4±0,56	<b>5,4±0,53</b>	<b>3,0±0,18</b>

**Note:** 1) Contr. and Exper. – Control and Experimental group of animals;

2) The values where the differences are significant relative to the control at  $P < 0.05$  are highlighted in bold.

## References

- Abdullayeva, A.A. (2019). The influence of chronic toxic hepatitis of the mother on the formation of the offspring liver in early postnatal ontogenesis (pilot study). In *Aktual'nyye problemy eksperimental'noy i klinicheskoy meditsiny* (pp. 405-405).
- Adilbekova D.B. Postnatal formation of vascular tissue structures of the stomach and intestines of offspring in conditions of chronic toxic hepatitis in the mother. Abstract. Autoref. dis... doctor of medical Sciences. TMA. Tashkent. -2018.-26 p.
- Bryukhin G.V. Rol' khronicheskogo eksperimental'nogo porazheniya pecheni materi v narushenii generativnoy funktsii potomstva. *Vestnik YUURGU*, № 8, 2012. – S. 98-102.
- Drayton D.L. Lymphoid organ development: from ontogeny to neogenesis. / Drayton D.L., Liao S., Mounzer R.H. & Ruddle N.H.// *Natural Immunology*. 2006. Vol.7, N4.- Nature Publishing Group.  
<http://www.nature.com/natureimmunology> - P. 344-353.
- Singh J., Singh A.K. Age-related changes in human thymus *Clin. exp. Immunol.* (1979) 37, 507-511.
- Kapitonova M.YU. i dr. Development of the spleen in early postnatal ontogenesis. *Vestnik VOLGMU*. 2007. - №4 (24). – S. 56-58.
- A.G. Kvaratskheliya. Morphological characteristics of the thymus and spleen under the influence of factors of various origins. Review. *Zhurnal anatomii i gistopatologii*. – 2016. – T. 5, № 3 – C. 77-83.
- Abdullayev N.KH., Karimov KH.YA. Liver in case of intoxication with hepatotropic poisons. - T.: *Meditsina*. -1989. - 140 s.
- Aripov A.N., Akhunjanova L.L., Khamroev T.T. Differential analysis of chronic toxic hepatitis caused chronic toxic hepatitis caused by the introduction of heliotrin solution heliotrin solution in various ways. *Texas Journal of Medical Science*. 2021. – P.58-62. ISSN NO: 2770-2936, <https://zienjournals.com>.
- Ugolev A.M., Timofeyeva N.M. Study of the piuevaritel'nogo tract in humans L.: Nauka, 1969. – 386 s.
- Dahgvist A. // *Analytical Biochem.* – 1968. – Vol. 22. – P. 99-107.
- Auricchio S., Rubio A. // *Clinical Biochemistry principles and methods*. – 1974. – Vol. 1, 2 – P. 1260-1275.
- Berdiyoroova S., Nuritdinova D., Kucharova L.S. The influence of malnutrition during the period of lactotrophic nutrition on the formation of digestion in growing rats // *Infection, immunity and pharmacology*. - 2019. - No. 2. - p. 311-312.
- Parfenov A.I. i dr. Enteropathy with impaired membrane digestion and prospects for cytoprotective therapy. *Terapevticheskiy arkhiv* 2, 2021. – S 129-137. DOI: 10.26442/00403660.2021.02.200602
- Shahani K.M., Kwan A.J., Friend B.A. Role and significance of enzymes in human milk. *Am J Clin Nutr.* 1980 Aug;33(8):1861-8. doi: 10.1093/ajcn/33.8.1861.
- Prikhod'ko Ye.A., Belyayeva I.A., Kruglyakov A.Yu., Mikheyeva A.A., Gorev V.V. / Factors associated with exclusive breastfeeding of late preterm infants in the neonatal hospital: a cross-sectional study // *Current pediatrics*. – 2022, V. 21, № 1. – P. 18-24.16
- Gates, A., Marin, T., De Leo, G., Waller, J.L., & Stansfield, B.K. (2021). Nutrient composition of preterm mother's milk and factors that influence nutrient content. *The American journal of clinical nutrition*, 114(5), 1719-1728.
- Stelwagen K., Bruckmaier R. M. Lactation biology. *Animal* (2012), 6:3, pp 353-354 & *The Animal Consortium* 2011. doi:10.1017/S1751731111002291
- Witkowska-Zimny M., Kaminska-El-Hassan E. Cells of human breast milk. *Cellular & Molecular Biology Letters* (2017) 22:11.
- Gherghiceanu, M., & Popescu, L.M. (2005). Interstitial Cajal-like cells (ICLC) in human resting mammary gland stroma. Transmission electron microscope (TEM) identification. *Journal of cellular and molecular medicine*, 9(4), 893-910.
- Sultanova, D. (2021). The influence of mother's extragenital pathology on the formation spleens of offspring in the early period postnatal ontogenesis. *The Scientific Heritage*, (81-2), 47-49.
- Bryukhin G.V., Fedosov A.A. Kharakteristika proliferativnoy aktivnosti timotsitov i limfotsitov perifericheskoy krovi potomstva samok s khronicheskim eksperimental'nym porazheniyem pecheni razlichnoy etiologii. *Morfologiya*. 2006. – Tom 129, №1. – S. 57-59.





- Yuldashev A. YU., Rakhmatova M. KH., Tarinova M.V. Functional morphology of the mucous membrane of the small intestine and features of its adaptation. International Scientific and Practical Conference "WORLD SCIENCE" ISSN 2413-1032. № 4(20), Vol.6, April 2017 <http://ws-conference.com/> - C. 38-43.
- Grigorenko D.Ye., Sapin M.R., Khrebtovskiy A.M. Morpho-functional state of hepatic lymph nodes in experimental hepatitis. Vestnik novykh meditsinskikh tekhnologiy - 2006 - T. KHIII, № 1 - S. 30-33.
- Onori P., et all. Peyer's Patches Epithelium in the Rat A Morphological, Immuno-histochemical, and Morphometrical Study. Digestive Diseases and Sciences, Vol. 46, No. 5 (May 2001), pp. 1095-1104.
- Petrenko, V.M. O Constitution of the Immune (lymphoid) systems (literature review) / V.M. Petrenko // Izvestiya vysshikh uchebnykh zavedeniy. Povolzhskiy region. Meditsinskiye nauki. - 2019. - № 2 (50). - S. 89-99. - DOI10.21685/2072-3032-2019-2-9.
- Protecting the Newborn and Young Infant from Infectious Diseases: Lessons from Immune Ontogeny. Immunity Review. Immunity 46, March 21, 2017 <sup>a</sup> 2017 Elsevier Inc. P/ 350-363.
- Senn V.et all. Microbial colonization from the fetus to early childhood—a comprehensive Review / Front. Cell. Infect. Microbiol., 30 October 2020. <https://doi.org/10.3389/fcimb.2020.573735>
- Hassiotou F., Geddes D.T. Immune cell-mediated protection of the mammary gland and the infant during breastfeeding // Adv. Nutr. 2015. V. 6, No. 3. P. 267-275.
- Donovan S.M. The Role of Lactoferrin in Gastrointestinal and Immune Development and Function: A Preclinical Perspective. The journal of pediatrics. www.jpeds.com Vol. 173S June, 2016. - P. 16-28. <http://dx.doi.org/10.1016/j.jpeds.2016.02.072>
- Kiseleva Ye.S., Mokhova YU.A. Breast milk and its components: impact on the child's immunity. Pediatriya. - 2010. - Tom 89, № 6. - S. 62-70.29.
- Perrin, M.T., Friend, L.L., & Sisk, P.M. Fortified donor human milk frequently does not meet sodium recommendations for the preterm infant. The Journal of Pediatrics.
- Parker, M.G., Stellwagen, L.M., Noble, L., Kim, J.H., Poindexter, B.B., & Puopolo, K.M. (2021). Promoting human milk and breastfeeding for the very low birth weight infant. Pediatrics, 148(5).
- Chernyshevich YU.N. Morphofunctional analysis of the jejunum of rat pups developing under conditions of maternal cholestasis. Zhurnal Grodnenskogo gosudarstvennogo meditsinskogo universiteta № 3, 2014 g. C. 33-37.
- Yaglova N.V., Obernikhin S.S. Influence of activation of the immune system of the maternal organism in early pregnancy on the postnatal morphogenesis of the organs of the immune system of the offspring. Problemy reproduktivnoy, 1, 2013. - C. 73-77.
- Azizov, Ye.Kh. Structural and functional basis of the reaction of mesenteric lymph nodes in experimental chronic toxic hepatitis and ways of its correction: avtoreferat dis. ... kandidata meditsinskikh nauk : 14.00.23. - Tashkent, 1996. - 19 c. : il.
- Georgountzou A., and Papadopoulos N.G. (2017) Postnatal innate immune development: from birth to adulthood. Review. Frontiers in Immunology. www.frontiersin.org - published: 11 August 2017, doi: 10.3389/fimmu.2017.00957.P.16.
- Eberl G. A new vision of immunity: homeostasis of the superorganism. Mucosal Immunology. Vol. 3 N 5. September 2010. doi: 10.1038/mi.2010.20 - P 450-460.
- Kazmirchuk V.Ye., Koval'chuk L.V., Mal'tsev D.V. Clinical immunology and allergology with age-related features: uchebnik — 2-ye izd., pererabot. i dopol. — K. : VSI «Meditsina», 2012. — 520 s.
- Taranushenko T.E. Unity of bowel-lung axis and the role of beneficial microbiota in anti-infectious protection. Review Articles. Russian Journal of Woman and Child Health. 2021;4(4):355-361 (in Russ.). DOI: 10.32364/2618-8430-2021-4-4-355-361.
- Drayton D.L. Lymphoid organ development: from ontogeny to neogenesis. / Drayton D.L., Liao S., Mounzer R.H. & Ruddle N.H.// Natural Immunology. 2006. Vol.7, N4.- Nature Publishing Group <http://www.nature.com/natureimmunology> - P. 344-353.

