

**TOSHKENT TIBBIYOT AKADEMIYASI
«O'QUV VA ILMIY TIBBIYOT JURNALI»**

**TASHKENT MEDICAL ACADEMY
«JOURNAL OF EDUCATIONAL AND SCIENTIFIC MEDICINE»**

IXTISOSLASHUVI: «TIBBIYOT SOHASI»

(ISSN 2181-3175)

Berilgan sanasi: 31-01-2022

Mazkur hujjat Vazirlar Mahkamasining 2017 yil 15 sentabrdagi 728-son qarori bilan tasdiqlangan O'zbekiston Respublikasi Yagona interaktiv davlat xizmatlari portali to'g'risidagi nizomga muvofiq shakllantirilgan elektron hujjatning nusxasi hisoblanadi.

№ 1 (05), 2022 (Том 1)

**BOSH MUHARRIR – Shadmanov A.K.
BOSH MUHARRIR O'RINBOSARI – Oxunov A.O.**

MA'SUL KOTIB:
Boboqulova Sh.A.
TAHRIRIYAT JAMOASI:

Azizova F.L.
Alyavi A.L.
Boymurodov Sh.A.
Karimov N.F.
Karimov Sh.I.
Tuychiev L.N.
Shayxova G.I.

TAHRIRIYAT KENGASHI:
Abdullaeva R.M.
Azizova F.X.
Ahmedov X.S.
Ashurov Z.Sh.
Irisqulov B.Y.



Karimjonov I.A.
Mamatqulov B.M.
Meliboeva R.N.
Mirahmedova X.T.
Mirtazaev O.M.
Navro'zov B.S.
Norqulov S.D.
Rahimboyeva G.S.
Salomova F.I.
Tashkenbayeva U.A.
Tursunov X.Z.
Usmonxo'jayeva A.A.
Xudayqulova G.K.
Xjanazarov I.E.
Yo'ldosheva D.Yu.

Публикации в журнале учитываются как опубликованные работы при защите диссертаций на соискание ученых степеней Узбекистана и зарубежья.

К публикации принимаются статьи, ранее нигде не опубликованные и не представленные к печати в других изданиях. Статьи, поступившие в редакцию, рецензируются. За достоверность сведений, изложенных в статьях, ответственность несут авторы публикаций. При использовании материалов ссылка на журнал и авторов статей обязательна.

Материалы публикуются в авторской редакции.

Tahririyat manzili:

Tashkent Medical Academy 100109, Tashkent, Uzbekistan
Farabi street 2 Helpline: +99878-150-7825:
Fax: +998 78 1507828 Email:info@tma.uz

<i>Khasanov Kh., Alikhodjayeva G., Yakubov J., Babakhanov B., Jurakulov E., Takeuchi K.</i> Expanded endonasal transsphenoidal surgery for the resection of tuberculum sellae meningioma. Description of surgical technique and review of literature	93
<i>Alikhodjayeva G.A., Akhmediev T.M.</i> Clinical characteristics of intramedullary spinal cord tumors of various histological structures (literature review)	105
<i>Navruzov S.N., Navruzov B.S., Khodzhimukhamedova N.A., Khakimov A.M. Rakhmonov S.T., Vokhidov U.G.</i> Modern minimally invasive approaches in the surgical treatment of hemorrhoids (literature review)	112
<i>Bobokulova Sh.A.</i> Treatment of acute purulent-destructive lung diseases considering the assessment of the degree of impairment of non-respiratory lung function.....	122
<i>Bilalov E.N., Oripov O.I.</i> Ophthalmology: yesterday, today and tomorrow.....	127
<i>Khudaibergenova N.Sh.</i> Long-term results of patients with deformation of the anterior abdominal wall after abdominoplasty	133
<i>Matmurotov K.J., Sattarov I.S.</i> Critical ischemic attack of arterial basin in type 2 diabetes mellitus.....	137
<i>Alikhodjayeva G.A., Akhmediev T.M.</i> State-of-the-art in the treatment of extradural spinal tumors.....	142
<i>Okhunov A.O., Khudaibergenova N.Sh., Kasimov U.K., Atakov S.S., Bobabekov A.R., Boboev K., Abdurakhmanov F.M.</i> Optimization of the educational process at the department of general surgery.....	148

UDC: 616.379-008.64+616-002.3-08

CRITICAL ISCHEMIC ATTACK OF ARTERIAL BASIN IN TYPE 2 DIABETES MELLITUS

*Matmurotov K. J., Sattarov I. S.
Tashkent Medical Academy*

Objective: to determine the nature and frequency of arterial pool damage in patients with type 2 diabetes mellitus.

Research material and methods: The research method was a survey, anamnesis and study of documents from other clinics in 154 patients. The results of treatment and anamnestic data were analyzed in 154 patients for the first quarter of 2021 with purulent-necrotic foot lesions on the background of type 2 diabetes mellitus during the initial visit to the purulent department at the multidisciplinary clinic of the Tashkent Medical Academy.

Results and discussion: the data obtained showed that in most cases the main type of blood flow was preserved on the hip at the level of the femoral-popliteal segment (in 73%), but there was a decrease in its speed characteristics (main-altered blood flow). When analyzing the data obtained on the timing of diabetes mellitus, it was revealed that the largest number of patients with critical ischemic attacks on the myocardium of the heart were observed in patients suffering from diabetes for 9-12 years (35.7%), brain damage in these terms was noted in 42.8% (12 patients) cases.

Conclusions: in type 2 diabetes mellitus, there is a multifocal lesion of arterial pools with the development of ischemic damage to the corresponding organs and systems. In patients with diabetic gangrene of the lower extremities on the background of type 2 diabetes mellitus lasting more than 10 years, critical ischemic events from the heart were observed in 27.3% of cases, brain in 18.2 % of cases.

Key words: diabetes mellitus, arterial lesion, purulent-necrotic process.

Information about authors: Matmurotov Kuvondik Jumaniyozovich.

Tel+99897. 430-53-53 E-mail: mqj_80@mail.ru

КРИТИЧЕСКАЯ ИШЕМИЧЕСКАЯ АТАКА АРТЕРИАЛЬНЫХ БАССЕЙНОВ ПРИ САХАРНОМ ДИАБЕТЕ 2 ТИПА

*Матмуратов К.Ж., Саттаров И.С.
Ташкентская медицинская академия*

Цель: определить характер и частоту поражения артериальных бассейнов у больных сахарным диабетом 2 типа.

Материал и методы исследования: Методом исследования являлись опрос, анамнез и изучение документов из других клиник у 154 больных. Проанализированы результаты лечения и анамнестические данные у 154 пациентов за I квартал 2021 года с гнойно-некротическими поражениями стоп на фоне сахарного диабета 2 типа при первичном обращении в гнойное отделение при многопрофильной клинике Ташкентской медицинской академии.

Результаты и их обсуждение: полученные данные показали, что в большинстве наблюдений магистральный тип кровотока был сохранен на бедре на уровне бедренно-подколенного сегмента (у 73%), однако наблюдалось снижение его скоростных характеристик (магистрально-измененный кровоток). При анализе полученных данных по срокам сахарного диабета выявлено, что наибольшее количество больных критическими ишемическими атаками на миокард сердца наблюдались у пациентов страдающих диабетом течение 9-12 лет (35,7%), поражение мозга в эти е сроки отмечались в 42,8% (12 больных) случаях.

Выводы: при сахарном диабете 2 типа имеет место мультифокальное поражение артериальных бассейнов с развитием ишемических повреждений соответствующих органов и систем. У больных с диабетической гангреной нижних конечностей на фоне сахарного диабета 2 типа продолжительностью свыше 10 лет критические ишемические явления со стороны сердца отмечались в 27,3% случаев, мозга в 18,2 % случаев.

Ключевые слова: сахарный диабет, артериальное поражение, гнойно-некротический процесс.

Сведения об авторах: Матмуротов Кувондик Жуманиезович.

Тел.(моб) +99897. 430-53-53

E-mail: mqj_80@mail.ru

QANDLI DIABET 2 TURIDA ARTERIAL HOVUZLARNING KRITIK ISHEMIK Hujumi

Matmurotov K. J., Sattarov I. S.

Tashkent Tibbiyotl Akademysi

Maqsad: qandli diabeti bo'lgan bemorlarda arterial zararlanishlar chastotasini o'ziga xosligi va chastotasini o'rganish.

Material va tekshirish usullari: tekshirish usullariga boshqa davolash muassasalarida tekshirilgan va davolangan 154 ta bemorning anamnezi va xujjatlarini o'rganib chiqildi. Toshkent tibbiyot akademiyasi yiringli jarroxlilik bo'limiga 2021 yilning birinchi choragida murojaat qilgan 154 ta bemorlar natijalari taxlil qilindi.

Natijalar va ularining taxlili: olingan natijalar shuni ko'rsatdiki, ko'pchilik xollarda bemorlarda (73%) son-taqim osti segmentida magistral qon aylanish mavjudligini ko'rsatdi, biroq qon tomirlarda qon oqishining sekinlashishi kuzatildi (magistral-o'zgargan qon aylanishi). Taxlillar natijasida ma'lum bo'ldiki, qandli diabeti 9-12 yil muddat bo'lgan bemorlarda yurak miokardida ko'p xollarda ishemiya belgilari kuzatildi (35,7%), shu muddatda bosh miyada 42,8% (12 ta bemor) xolda kritik ishemiya belgilari kuzatildi.

Xulosalar: qandli diabetning 2 turi bilan xastalangan bemorlarda arterial tomirlarning umumiy o'zgarishi natijasida tegishli a'zolarida ishemik xolatlariga olib keladi. Diabetik gangrenasi bo'lgan va 10 yildan ortiq qandli diabet bilan xastalangan bemorlarda yurak va bosh miya kritik ishemiya xurujlari bir necha marta oshishi kuzatildi.

Kalit so'zlar: qandli diabet, arterial zararlanish, yiringli-nekrotik jarayon.

Avtor haqida ma'lumot: Matmurotov Kuvondik Jumaniozovich.

Тел.(моб) +99897. 430-53-53

E-mail: mqj_80@mail.ru

Relevance. The leading factors in the formation of purulent-necrotic lesions in diabetic foot syndrome (DFS) are neuropathy and ischemia, but in most cases, the malicious course of the purulent-necrotic process on the foot complicates the situation much more. Many authors recommend paying special attention to the detection of diabetic angiopathy and its correction for the prevention of further complications [1]. This is an occlusive-stenotic atherosclerotic lesion of the main and peripheral arteries of the lower extremities, which has

a number of significant features in patients with diabetes mellitus (DM), especially those who develop diabetic foot syndrome: distal localization, young age of patients, multisegmental and bilateral lesions, relatively frequent occurrence in women [3, 5]. Ischemia in diabetic patients can be difficult to determine due to neuropathy, when there is often no pain syndrome, intermittent lameness or neuropathic pain prevails [4]. The prevalence of asymptomatic chronic arterial insufficiency of the lower extremities (CAILE) among patients

with type 2 diabetes is at least 2 times higher than in the general population, and is 23.5-73.8% [6,7]. There is information in the literature about the frequency of ischemic attacks of the brain (12.3%) and heart (21.7%) in patients with diabetic foot syndrome [6,7]. The peripheral arterial flow as a whole reacts to external and internal factors in the body, regardless of localization. At the same time, the functional and morphological structure of small arteries is disrupted simultaneously, thereby leading to larger-scale changes associated with impaired blood circulation of tissues [1, 2, 4]. Unfortunately, at present, there is extremely insufficient information about the frequency, development and features of arterial damage to various organs in patients with type 2 diabetes mellitus.

In this regard, the purpose of our study is to study the nature and frequency of arterial pool lesions in patients with type 2 diabetes mellitus.

Material and methods of research

The research method was a survey, anamnesis and examination of documents from other clinics in 154 patients. The results of treatment and anamnestic data were analyzed in 154 patients for the first quarter of 2021 with purulent-necrotic foot lesions on the background of type 2 diabetes mellitus during the initial visit to the purulent department at the multidisciplinary clinic of the Tashkent Medical Academy. The overwhelming number of patients (96.1%) had type 2 diabetes mellitus. The average duration of diabetes mellitus was 9.6 ± 2.3 years. The age of the patients ranged from 23 to 88 years (on average, 65.2 ± 2.7 years). There were 95 (61.6%) men and 59 (38.4%) women among the patients. Neuropathic form of diabetic foot syndrome was diagnosed in 51 (33.1%) patients, neuroischemic - in 78 (50.6%), ischemic - in 25 (16.2%). The main instrumental method for assessing the state of macrocirculation was ultrasound duplex scanning of the lower extremities, brachycephalic and carotid arteries, performed on an ultrasound duplex system. Acuson-128 XP/10 ("Acuson", USA) according to the standard method with a linear sensor with a frequency of 7-15 MHz. The qualitative assessment was based on determining the presence and type of

blood flow in the arteries of the lower leg and foot, while the blood flow was evaluated as main altered, main unchanged and collateral. The presence and level of arterial stenoses and occlusions, the degree of narrowing of the artery, the prevalence of the lesion and the exact location of atherosclerotic plaques were determined.

Results and their discussion

In most cases, the main type of blood flow was preserved on the thigh at the level of the femoral-popliteal segment (in 73%), but there was a decrease in its speed characteristics (main-altered blood flow). At the level of the popliteal-tibial segment, the main and main-altered blood flow was preserved in 81 (52.7%), along the anterior and posterior tibial arteries – in 94 (61.4%) and was not detected in 45 (29.5%), on the back artery of the foot it occurred in 75 (48.6%) and was not established in 71 (46.1%). The following quantitative parameters of blood flow were determined in the distal sections of the lower leg arteries: peak systolic velocity (PSV), average diastolic velocity (MDV), time-averaged maximum blood flow velocity (TAM), volumetric blood flow velocity (VF), resistivity index (RI), pulsation index (PI). There were no quantitative and qualitative disorders of the main blood flow in patients with neuropathic form. In the presence of compensated ischemia in 42 (27.3%) patients, the shape of the blood flow spectrum retained "gothic" systolic peaks. Quantitative parameters of peripheral blood flow: PSV- 36 ± 5.3 ; MDV- 19.1 ± 3.2 ; TAM- 13.1 ± 0.6 ; VF- 47.2 ± 5.1 ; RI- 0.49 ± 0.02 ; PI- 0.76 ± 0.03 . In critical limb ischemia in 56 (36.3%) patients, the form of the blood flow spectrum was characterized by the absence of acute systolic peaks, was smoothed with low systolic and high diastolic components. Quantitative parameters of blood flow were significantly reduced: PSV- 5.4 ± 0.4 ; MDV- 3.01 ± 0.3 ; TAM- 1.38 ± 0.4 ; VF- 3.8 ± 0.3 ; RI- 0.18 ± 0.01 ; PI- 0.26 ± 0.02 . In 31 (20.1%) patients, thickening and increased echogenicity of the distal artery walls were detected due to calcification, pronounced diffuse thickening of the intima-media complex until complete loss of differentiation into layers. The X-ray picture revealed the presence of mediocalcinosis in 16% of patients (additional re-

search methods are required to determine the treatment tactics). During ultrasound, the ankle-shoulder index (ASI) was also determined, but its reliability for assessing the degree of ischemia in diabetes mellitus due to the preva-

lence of mediocalcinosis is questionable. Of 154 patients with type 2 diabetes mellitus lasting more than 10 years, a critical ischemic attack on the heart was in 42 (27.2%) cases, on the brain in 28 (18.2%) cases.

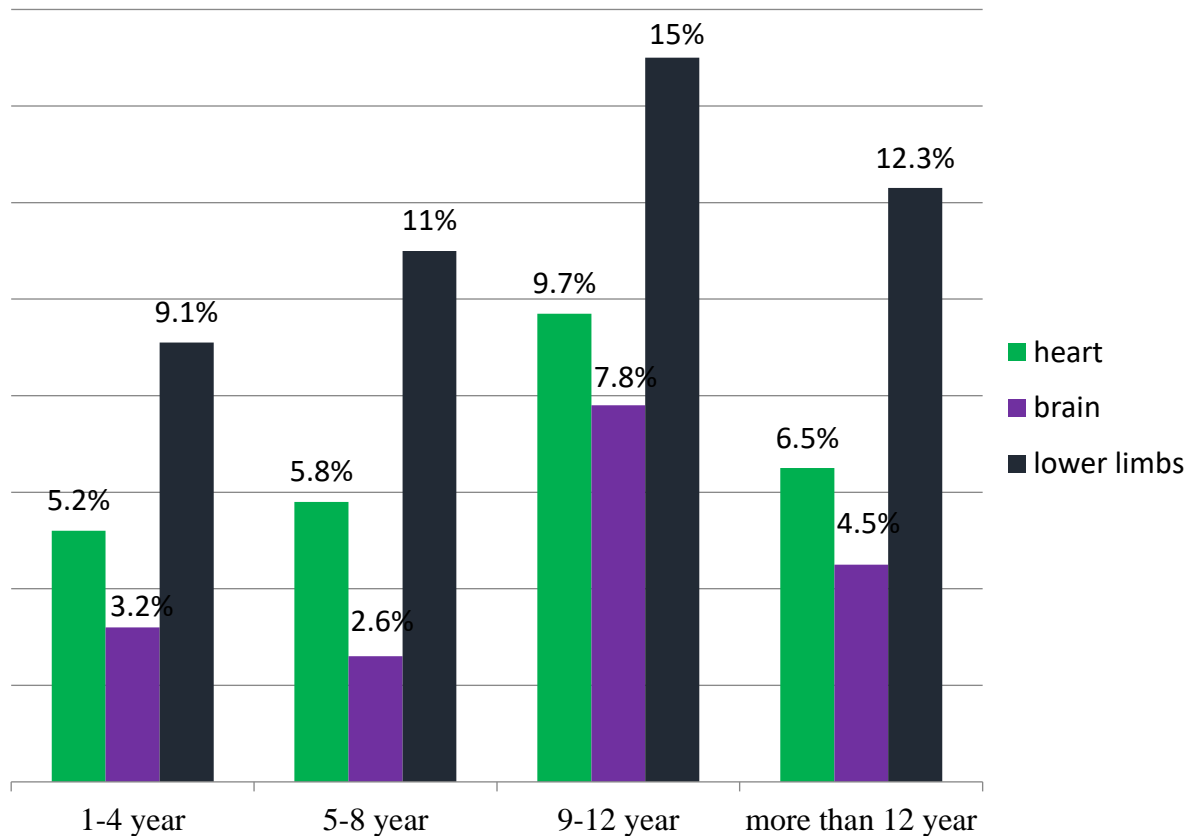


Fig. 1. Analysis of the chronology of arterial pool lesions in type 2 diabetes mellitus (abs %)

A duplex scan of the carotid and brachycephalic arteries was performed in 88 (57.1%) patients, in which occlusive-stenotic changes of various degrees and localization were detected in 71 (80.1%). According to ECG data, these patients showed signs of coronary heart disease in 53 (60.2%) cases.

When analyzing the data obtained on the timing of diabetes mellitus, it was revealed that the largest number of patients with critical ischemic attacks on the myocardium of the heart were observed in patients suffering from diabetes for 9-12 years (35.7%), brain damage in these terms was noted in 42.8% (12 patients) cases (Fig. 1.). Due to trophic disorders on the foot against the background of severe ischemia or neuropathy of the lower extremities, 84 out of 154 patients (54.5%) had a history of seeing doctors or received inpatient treatment before admission to our clinic. It should be noted that

of the patients who suffered an acute myocardial infarction or acute coronary syndrome for the entire period of diabetes mellitus, 4.6% (7 patients) of cases had a repeated cardiac ischemic attack in the anamnesis before the appearance of trophic changes on the foot. In patients treated with purulent-necrotic processes on the foot, repeated ischemic brain attacks were detected in 6 (0.9%) cases at the same time. During the analysis of the obtained data, it was revealed that critical limb ischemia was observed in 67 (43.2%) patients who made up the "critical" group with the threat of limb loss. Of the patients with critical and subcompensated ischemia, 23 (14.9%) patients were admitted to the hospital with gangrene of the foot (5th degree according to Wagner). From the data obtained, it was revealed that the number of patients with trophic changes on the foot against the background of neuroischemia in-

creases with the duration of the course of diabetes mellitus. At the same time, in 15% (23 patients) who applied to the hospital, the duration of diabetes mellitus was about 10 years and these patients were mainly a neuroischemic form of diabetic foot syndrome (Fig. 1.). This, in turn, shows that during these periods, patients with diabetes mellitus most often experience a decompensated violation of peripheral arterial circulation with the addition of pronounced polyneuropathy.

Thus, the analysis of arterial pool lesions in patients with purulent-necrotic lesions of the lower extremities against the background of type 2 diabetes mellitus showed that very often (51.6%) critical ischemic attacks on the lower extremities are preceded by critical ischemic attacks of other vital organs and systems. In particular, with the duration of type 2 diabetes mellitus over 10 years in 154 patients, a retrospective analysis of anamnestic data revealed the presence of ischemic clinical phenomena from the heart in 42 (27.3%) cases, the brain in 28 (18.2%) cases. According to the terms of development of these critical ischemic attacks, the most threatening were 9-12 years.

Discussion

The analysis of the results obtained in patients with arterial lesions of organs and systems showed that the largest number of patients with purulent-necrotic lesions of the lower extremities had a history of ischemic attacks from the myocardium. Repeated coronary ischemic attacks occurred in 4.9% of cases. Analysis of the causes of arterial damage from organs and systems in patients with purulent-necrotic lesions of the lower extremities against the background of type 2 diabetes mellitus allowed us to offer a thorough examination and correction of glycemic levels. In our opinion, an adequate assessment and identification of the frequency with the level of lesion of occlusive-stenotic changes for predicting the lesion of arterial basins from other organs and systems is possible only by conducting a comprehensive examination of patients taking into account a number of modern objective data.

Conclusions:

1. In type 2 diabetes mellitus, there is a multifocal lesion of arterial pools with the development of ischemic clinical signs from the relevant organs and systems.

2. In patients with gangrene of the lower extremities on the background of type 2 diabetes mellitus lasting more than 10 years, simultaneous damage to the arterial pools was noted - 27.3% of cases from the heart, brain in 18.2%.

3. These data indicate the need for an in-depth study of the nature, severity and localization of occlusive-stenotic lesions of arterial basins in type 2 diabetes mellitus.

REFERENCES

1. Bregovskiy V.B., Zaytsev A.A., Zalevskaya A.G. Porazheniya nizhnikh konechnostey pri sakharnom diabete. - M. - SPb: Izd-vo «Dilya», 2009. - 272 s.
2. Dedov I.I., Antsiferov M.B., Galstyan G.R. Sindrom diabeticheskoy stopy. - M., 2011. - 138 s.
3. Mezhdunarodnoye soglasheniye po diabeticheskoy stopy. - M: Izd-vo «Bereg».- 2012.- 96 s.
4. Shor N.A. Khirurgicheskaya taktika pri diabeticheskoy angiopatii nizhnikh konechnostey s gnoyno-nekroticheskimi porazheniyami.// Khirurgiya. - 2014.- №6. - S. 29 - 32.
5. Shul'ts A.A. Aktual'nyye problemy diabetologii // Mir farm. i med. - 2010. - №18 (215) - S. 22.
6. Faglia E. Angiographic Evaluation of Peripheral Arterial Occlusive Disease and Its Role as a Prognostic Determinant for Major Amputation in Diabetic Subjects with Foot Ulcers// Diab. Care, 2012. - Vol. 21 (4). - P. 625-630.
7. Walters D., Galling W., Mullee M. The prevalence, detection and epidemiological correlates of peripheral vascular disease: a comparison of diabetic and non-diabetic subjects in an English community.// Diab. Med. - 2010. - Vol. 9 - P. 710-715.

STATE-OF-THE-ART IN THE TREATMENT OF EXTRADURAL SPINAL TUMORS

G.A. Alikhodjayeva, T.M. Akhmediev

Tashkent Medical Academy

Tashkent, Uzbekistan

RESUME

Introduction. Timely diagnosis of tumors of the thoracic spine at an early stage of the disease creates conditions for the choice of adequate tactics of surgical treatment with the preservation of vital anatomical structures.

The purpose of the study: to analyze the results of surgical treatment of extradural tumors of the thoracic spine, depending on the choice of surgical treatment tactics.

Materials and methods. The material of the study are patients with extradural tumors of the thoracic spine aged 10 to 50 years who were treated at the Republican Specialized Scientific and Practical Medical Center of Neurosurgery in the period 2019-2021. The following methods were used in the investigation: clinical neurological, X-ray, MRI, MSCT studies, scintigraphic research. Methods of surgical intervention:

1. Laminectomy with removal of an extradural tumor of the thoracic spine without stabilization of the vertebral-motor segment

2. Laminectomy with removal of an extradural tumor of the thoracic spine with stabilization of the vertebral-motor segment

All patients were divided into 2 groups:

1. The main group, patients underwent removal of an extradural tumor of the thoracic spine with stabilization of the spine (stabilizing);

2. Control group, patients underwent removal of an extradural tumor of the thoracic spine without spinal stabilization (decompressive).

We used the following scales: determination of the general condition of patients according to the Karnovsky scale, the pain intensity scale (Dennis, 1989), the scale of motor and sensory functions according to Frankel (1992), assessment of sensitivity disorders.

Results. In the surgical treatment of tumors of the thoracic spine, we applied 2 main types of interventions: stabilizing and decompressive operations. In decompression-stabilizing operations, posterior-median access is very convenient in terms of decompression and removal of the tumor.

Conclusion. Indications for surgical treatment of extradural spinal cord tumors were the presence of intense pain syndrome, compression of the spinal cord, progressive neurological disorders, gross instability of the spinal-motor segment. The best results were noted in the group of patients who underwent spinal-motor segment stabilization.

Keywords: *extradural tumors of the spinal cord, surgical treatment, outcome.*

EKSTRADURAL UMURTQA POG'ONASI O'SMALARINI DAVOLASHDA ZAMONAVIY AMALIYOTLAR

G.A. Alixodjayeva¹, J.O. Sobirov², T.M. Axmediyev¹

Toshkent tibbiyot akademiyasi¹

Respublika ixtisoslashtirilgan neyroxirurgiya ilmiy-amaliy tibbiyot markazi²,

Toshkent, O'zbekiston

XULOSA

Kirish. Umurtqa pog'onasi ko'krak qismi o'smalarini erta bosqichda tashxislash muhim anatomik tuzilmalarni saqlagan xolda jarrohlik o'tkazish uchun shart-sharoitlar yaratadi.