

Abstracts for the UIP XIX World Congress of Phlebology, 12–16 September 2022, Istanbul, Turkey

Phlebology
2022, Vol. 37(2S) 3–276
© The Author(s) 2022
Article reuse guidelines:
sagepub.com/journals-permissions
DOI: 10.1177/02683555221110363
journals.sagepub.com/home/phl


Mitochondrial DNA Impairments Affect Mitochondria's Functional State in Varicose Veins

Mariya Smetanina¹, Valeria Korolenya², Ksenia Sevostyanova³, Konstantin Gavrilov³, Andrey Shevela³, Maxim Filipenko⁴

¹(a) Laboratory of Pharmacogenomics, Institute of Chemical Biology and Fundamental Medicine, and (b) Department of Fundamental Medicine, Novosibirsk State University, Novosibirsk, 630090, Russia

²(a) Laboratory of Pharmacogenomics, Institute of Chemical Biology and Fundamental Medicine, and (b) Department of Natural Sciences, Novosibirsk State University, Novosibirsk, 630090, Russia

³(a) Center of New Medical Technologies, Institute of Chemical Biology and Fundamental Medicine, and (b) Department of Surgical Diseases, Novosibirsk State University, Novosibirsk, 630090, Russia

⁴(a) Laboratory of Pharmacogenomics, Institute of Chemical Biology and Fundamental Medicine, and (b) Department of Clinical Biochemistry, Novosibirsk State University, Novosibirsk, 630090, Russia

Background: Molecular pathogenesis of varicose vein disease is far from being understood. In our previous studies we showed the decreased mitochondrial DNA (mtDNA) copy number and its impaired integrity in varicose veins. There is an evidence of the link between mtDNA copy number, mitochondrial membrane potential, oxygen consumption, and ATP synthesis. Varicose veins are characterized by endothelial dysfunction and reduction of smooth muscle cells' contractile function. We aimed at investigating possible alterations of mitochondria functions (in terms of mitochondrial membrane potential of the vein wall constituents: endothelial cells (ECs) and smooth muscle cells (SMCs) of t. intima and t. media layers, correspondingly) in varicose veins.

Methods: The study was conducted according to the principles written in the Declaration of Helsinki and approved by our institutional committee. Post-operation material of paired GSV samples (varicose (VV) and non-varicose (NV) vein segments left after surgery from a corresponding patient, C2-C4 CEAP classes) was placed in cell culture media and subjected to live-staining with mitochondrion-selective fluorescent probes: mitochondrial membrane potential-dependent TMRM and -independent MitoTracker Deep Red, as well as with nucleus-selective probe NucBlue. To visualize a particular vein wall layer, images were taken at different z-axis series using laser scanning confocal microscopy. Measurements of signal intensities were performed using ZEN 3.1 (blue edition) software (Zeiss, Germany). Relative levels of mitochondrial membrane potential were calculated as the [mitochondrial membrane potential-dependent/mitochondrial membrane potential-independent intensities] ratios within each cell/image field/sample. Statistical analysis was performed in Excel and STATISTICA packages, using Student's t-test (for comparison between multiple cells/image fields within a subgroup) and Wilcoxon-signed rank test (for comparison between paired NV and VV segments).

Results: We found that that mitochondrial membrane potential was decreased in ECs and SMCs of VV compared to NV segments 2.98- and 5.08-fold, correspondingly (n=5, p<0.05). The representative images are shown in [Figure 1](#). More thorough analysis will be performed in the nearest future.

Conclusion: Though preliminary, these findings provide a possible link between vascular ECs and SMCs functional activity and their mtDNA content in varicose veins. The work was supported by the Russian Science Foundation (project No. 22-25-00832).

Keywords: varicose veins, endothelial cells, smooth muscle cells, mitochondrial membrane potential

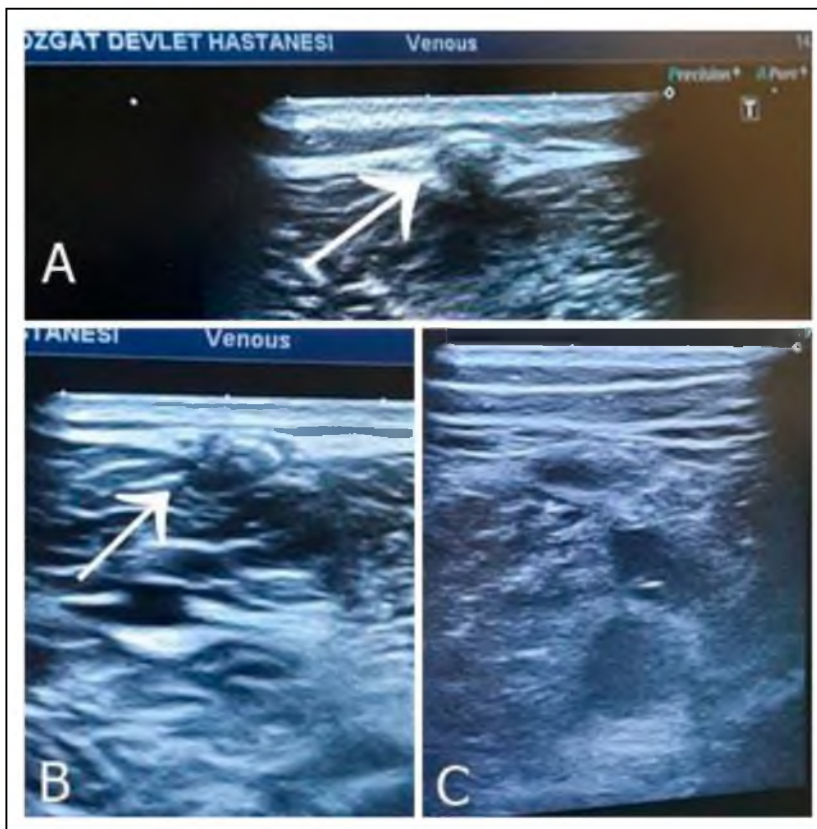


Figure 1. (A and B) CDUS images of occluded small saphenous vein treated with cyanoacrylate closure. (C) Patent popliteal vein after treatment with NBCA.

the literature in order to reveal potential benefits and risks for IJVA management in the adults.

Methods: A systematic review was performed by searching Pubmed and Google Scholar databases from 1946 up to the 2022. All case reports and case series including patients older than 18 years old who had IJVA and reported in English language were included. Study selection and reference search were performed by two reviewers.

Results: A total of 60 patients who had IJVA and older than 18 years were evaluated. The patients included 22 males (36,6 %) and 38 females (63,3%) with a mean age of 50 years. IJVAs are often seen on the right side of the patients. (34 patients, %56). 6 patients (10 %) had neurofibromatosis and they tend to have larger IJVAs and more complex surgeries. 27 patients (45 %) had undergone surgery for aneurysm. Patients preference is the leading cause for surgery due to anxiety and cosmetic outcomes. (5 patients, 18% of patients who have had surgery) Risk of rupture, risk of thrombus detachment and ongoing symptoms are among the other causes of surgery.

Conclusion: Internal jugular vein aneurysm is an infrequent disease of the neck vessels. Although commonly seen in pediatric population and has a benign nature, rarely it may have devastating complications such as pulmonary

embolism or rupture in the adults. Although most patients have cosmetic anxiety or anxiety of rupture of aneurysm, a thorough and comprehensive communication with patient about the benign nature of the disease would help to avoid unnecessary surgeries.

Keywords: aneurysm, jugular vein, phlebectasia, review

Venous Thrombosis Of The Lower Extremities In Pregnant Women

Akmal Irnazarov¹, Dilchekhira Yuldasheva¹, Ilhom Beknazarov¹, Dinara Irnazarova¹

¹Tashkent Medical Academy

Background: Venous failure affects a third of women during their first pregnancy, and venous thromboembolism ranks first in maternal mortality. The purpose of the study was to evaluate the results of the treatment of venous thrombosis in pregnant women.

Methods: In the multidisciplinary clinic of Tashkent Medical Academy, from 2015 to 2022, 137 pregnant women with lower limb vein thrombosis (LVT) were treated. Mean

age 31.6±5.8 years. The anamnesis of onset of the disease was 1-8 days. The tactics of treating pregnant women with acute TVL, both surgical and obstetric, were developed collegially by obstetrician-gynecologists and vascular surgeons. Various types of surgical interventions were used to prevent thromboembolic complications.

Results: Venous thrombosis developed in the I trimester - in 27 (19.7%) patients, in the II trimester - in 37 (22.3%) patients, in the III trimester - in 73 (53.3%) patients. According to ultrasound (US) data, deep vein thrombosis of the shin occurred in 14 (10.2%) patients, of which 1 (0.7%) had a floating thrombus, popliteal vein (PV) thrombosis - 11 (8%), femoral vein thrombosis - in 10 (7.3%), iliofemoral venous thrombosis was detected in 15 (11%). Acute thrombophlebitis in the system of the great saphenous vein was detected in 76 (55.5%) and in system of the small saphenous vein was 11 (8%) women. Installation of cava filter was used in 4 (3%) patients, cava filter installation with thrombolysis and thromboaspiration - 1 (0.7%), thrombectomy from the common femoral vein (CFV) + ligation of the superficial femoral vein (SFV) - 6 (4%), SFV ligation - 8 (6%), crossotomy in 57 (41.6%) cases, small saphenous vein ligation in 8 (6%). No lethal outcomes and thromboembolism were observed in early postoperative period. During 1-3 months after operation on CFV and CIV, we found a partial restoration of blood flow in US. Thrombosis of the popliteal and SFV of the contralateral lower limb without flotation was diagnosed. After discharge, methods of delivery and termination of pregnancy were determined according to obstetric indications. In 2 cases, the pregnancy was terminated for obstetric indications. In the remaining 135 patients, the pregnancy was prolonged and ended in delivery without complications in 120 women, delivery by Caesarean section was performed in 15 cases.

Conclusion: Operation of the main veins and implantation of a cava filter avoids thromboembolic complications in pregnant patients with floating venous thrombosis. Dynamic US monitoring of the proximal part of the thrombus in magisterial veins of lower extremities in the first 8-10 days after the onset of thrombosis help to identify the growth and possible transformation of a fresh thrombus into a floating thrombus.

Keywords: venous thrombosis, pregnancy

Advantages and disadvantages of the CLaCS method in aesthetic phlebology

Svetlana Kulagina¹, Evgeniy Ozherelyev¹

¹Center of Phlebology

Background: CLaCS-therapy is a modern method of treating reticular varicose veins. It's based on the combined effect of injection sclerotherapy and transdermal

neodymium laser combined with skin cooling. Objective: The main goal was to research immediate clinical effects of CLaCS-therapy in patients with reticular varicose veins.

Methods: Our research included 536 patients (516 women and 20 men) with reticular varicose veins. Aged groups was 18 to 75 years. Results was evaluated using retrospective analyze. All patients were undergoing CLaCS therapy. The study was conducted from January to December 2021. A transdermal long-pulse neodymium laser Harmony XL Pro (Almalasers, Israel) was used, the working spot size was 6.2 mm, the pulse duration was 10, 12, 15, 45 ms, fluence rate was 100-140, 200-240 J/sq.cm.). We used Veinviever (Cristie Medical, USA) as additional visualizing method. After treatment with a transdermal laser, non-closed vessels were injected with 40% dextrose and 3% ethoxysclerol at a 3:1 dilution. For local skin cooling, cold air (-15°C) produced by Lasertech (USA) was used. Each patient was undergoing 3 to 5 sessions with 4 weeks interval.

Results: All patients were followed up for up to 1 year. The results were evaluated clinically. A follow-up examination was carried out after 3 months: the regression of the treated reticular veins was assessed. The best cosmetic effect was achieved in 527 (98.3%) patients after 3 sessions of CLaCS therapy, 2 (0.4%) patients after 4 sessions and 7 (1.3%) patients after 5 sessions. The necessity to puncture coagula was absent in all cases. Complications after the first session of CLaCS therapy were registered in 3 patients - in 2 cases it was secondary matting, 1 patient developed a cold allergy. Secondary matting was corrected with a Harmony XL Pro transdermal neodymium laser after 6 months.

Conclusion: CLaCS-therapy is a modern effective method for the varicose veins treatment in aesthetic phlebology with low-risk of complications and early rehabilitation without wearing compression stockings and without changing the patient's lifestyle.

Keywords: PHLEBOLOGY, CLaCS METHOD, reticular varicose veins

Pharmaco-Mechanic Thrombectomy and Rivaroxaban for Treatment of Ilio-Femoral Deep Vein Thrombosis with Enoxaparin-Induced Thrombocytopenia

Mert Dumantepe¹, Cuneyt Ozturk²

¹Uskudar University School of Medicine, Department of Cardiovascular Surgery

²Florence Nightingale Hospital, Department of Cardiovascular Surgery

Background: Heparin-induced thrombocytopenia (HIT) is a life-threatening complication, affecting the morbidity and mortality of the patient if not properly treated. We