

ISSN-0973-9122 (Print) • ISSN-0973-9130 (Electronic)

Volume 14

Number 4

October-December 2020



Indian Journal of Forensic Medicine & Toxicology

Website: www.ijfmt.com



Official Organ of Indian Association of Medico-Legal Experts (Regd.)

Some Features of Hemorrhagic Syndrome in Chronic Diffuse Liver Diseases

Zumrad Ch. Kurbonova¹, Shaira A. Babadjanova²,
Zulfiya S. Islamova³, Abdumurat S. Babadjanov⁴, Nargiza B. Musayeva⁵

¹MD, PhD, Associate Professor, Department of Hematology, Transfusiology and Laboratory Studies, Tashkent Medical Academy, 2 Farobiy Str., Tashkent, Uzbekistan, 100109, ²MD, Professor, Department of Hematology, Transfusiology and Laboratory, Studies, Tashkent Medical Academy, 2 Farobiy Str., Tashkent, Uzbekistan, 100109, ³MD, Senior lecturer, Department of Hematology, Transfusiology and Laboratory, Studies, Tashkent Medical Academy, 2 Farobiy Str., Tashkent, Uzbekistan, 100109, ⁴MD, Professor, Head of the department of GP therapy and Clinical Pharmacology, Tashkent Pediatric Medical Institute, 223 Bogishamol Str., Tashkent, Uzbekistan, ⁵MD, Senior lecturer, Department of Hematology, Transfusiology and Laboratory, Studies, Tashkent Medical Academy, 2 Farobiy Str., Tashkent, Uzbekistan, 100109

Abstract

Objective of the Study: To characterize the hemorrhagic syndrome in patients with chronic hepatitis and liver cirrhosis of viral cause.

Materials and Method: 80 patients with liver cirrhosis of viral cause have been studied, 20 patients with liver cirrhosis of non-viral cause and 62 patients with chronic viral hepatitis.

Results of the Study: Hemorrhagic syndrome was pronounced in patients with liver cirrhosis of viral cause, and much less pronounced in the group of patients with liver cirrhosis of non-viral cause. In patients with chronic viral hepatitis B and C, bleeding symptoms were much less common.

Conclusions: Severe hemorrhagic syndrome with liver cirrhosis of viral cause requires a detailed study of coagulation and vascular-platelet hemostasis for the prevention and treatment of bleeding.

Keywords: Hemorrhagic syndrome, liver cirrhosis, chronic hepatitis, hemostasis.

Introduction

Hemostasis is an evolutionarily developed, multicomponent protective function of the body. Its physiological significance is mainly to ensure the formation of a fibrin clot and maintain blood in the liquid state¹.

The liver plays an important role in hemostasis; therefore, diffuse lesions of the liver parenchyma are the cause of complex disorders of hemostasis⁷. In liver cirrhosis, changes in the hemostasis system are complex and multidirectional. In the occurrence of hemostasis disorders in liver diseases, complex mechanisms of interaction of platelets, coagulation factors, and the fibrinolysis system are involved¹⁴. Therefore, chronic or acute liver diseases, including viral hepatitis, alcoholic

hepatitis, chronic hepatitis and cirrhosis, often have a profound effect on the hemostatic system¹².

Many liver diseases lead to thrombocytopenia, since protein coagulation factors and hematopoietic platelet growth factor thrombopoietin are produced in the liver⁸. According to many researchers, one of the reasons for the development of thrombocytopenia is an increase in antiplatelet antibodies in liver diseases¹⁰. Thrombocytopenia in liver diseases leads to an increased risk of bleeding, which may be a contraindication for antiviral therapy, liver biopsy and surgery⁵.

Decreased synthesis of coagulation factors by liver cells plays a key role in changes in hemostasis. It also leads to an altered fragile⁶ balance of blood coagulation factors, which is the reason for the development of

coagulopathy and the occurrence of hemorrhagic syndrome in liver diseases¹³.

Bleeding is the most common clinical manifestation, due to thrombocytopenia and thrombocytopathy, to impaired synthesis of clotting factors, and activation of fibrinolysis. Other actual clinical problems are bleeding in patients with liver cirrhosis³, bleeding esophageal varices, hematomas, hemorrhagic purpura, nasal hemorrhage, gingival hemorrhage and menorrhagia².

Timely diagnosis of hemostatic disorders in patients with chronic viral hepatitis and liver cirrhosis and appropriate hemostatic therapy will reduce the risk of hemorrhagic complications. It is noteworthy that previous researches concerned with the bleeding in chronic hepatitis and liver cirrhosis are few, and their results are contradictory. This explains interest in further research in this area.

Objective of the study: To characterize the hemorrhagic syndrome in patients with chronic hepatitis and liver cirrhosis of viral cause.

Materials and Method

Clinical studies were performed in the departments of Hematology and Hepatobiliary Pathology of the multidisciplinary clinic of the Tashkent Medical Academy, since 2016 to 2019. The study included 162 patients with chronic diffuse liver diseases, including 80 patients with decompensated liver cirrhosis of viral cause (Child-Pugh Class B), 20 patients with decompensated liver cirrhosis of non-viral cause (Child-Pugh Class B), and 62 patients with chronic viral hepatitis of moderate activity.

When establishing a diagnosis of liver cirrhosis and chronic hepatitis of viral cause, past medical history of the patients was taken into account (transfusion of blood components, dental treatment, etc.), as well as characteristic clinical syndromes (hemorrhagic, anemic, astheno-neurotic, icteric, etc.) and laboratory and instrumental studies data. The detection of hepatitis virus markers by ELISA and PCR, blood analysis, the determination of hepatitis B virus DNA (HBV) and hepatitis C virus RNA (HCV) and D (HDV) with the determination of genotypes was mandatory. In patients with chronic hepatitis and liver cirrhosis of viral cause, the viral load was more than 1,000,000 IU/ml.

The diagnosis of liver cirrhosis and the degree of hepatic cell failure has been established with the

consideration of WHO recommendations (2008), according to the Child-Pugh classification, and based on diagnostic criteria. In order to establish the degree of fibrosis in patients with liver cirrhosis, an ultrasound scan (US), MSCT, and liver fibroscan have been performed. The survey included patients with chronic hepatitis and liver cirrhosis who did not undergo antiviral therapy.

All patients examined by us were divided into 6 groups: group 1 included 30 patients with HBV liver cirrhosis, group 2 - patients with HBV+HDV liver cirrhosis, group 3 - 30 patients with HCV liver cirrhosis, group 4 - 20 patients with liver cirrhosis with negative results for markers of viral hepatitis. Group 5 included 32 patients with chronic viral hepatitis B of moderate activity, and group 6 - 30 patients with chronic viral hepatitis C of moderate activity.

Among 162 patients included in the study, there were 92 males (56.79%) and 70 females (43.21%). The age of patients ranged from 21 to 69 years, the average age was 48.2±12.1 years. Number of patients of working age accounted for 43.97%.

In order to determine the type of hemorrhagic syndrome, we studied patients' complaints, their past medical history and objective data: gingival hemorrhage, nasal hemorrhage, menorrhagia, bleeding esophageal varices and hematomas.

Research Result

The study included patients with liver cirrhosis of viral and non-viral cause, and chronic viral hepatitis B and C of medium activity. Liver cirrhosis in these patients was classified as decompensated (Child-Pugh Class B).

In order to determine the type of hemorrhagic syndrome, we studied the patients' complaints, their past medical history and objective data. Patient complaints were divided into the following types: anemic syndrome, sideropenia, symptoms of funicular myelosis, icteric syndrome, hemorrhagic syndrome and symptoms of liver failure. In order to identify hemorrhagic syndrome, in addition to patients' complaints, we paid special attention to objective data and a medical history.

The patients' main complaints were divided by the following hemorrhagic symptoms: nasal bleeding, gingival bleeding, skin petechiae, hemorrhoidal bleeding, bleeding esophageal varices, menorrhagia and gastrointestinal bleeding.

Analysis of the clinical manifestations of bleeding according to complaints, medical history and objective data of the patients showed that the hemorrhagic symptoms were very diverse during the examination. For example, epistaxis occurred in 59 (34.3%), gingival

hemorrhages in 52 (30.2%), skin petechiae in 46 (26.7%), hemorrhoidal bleeding in 36 (20.9%), bleeding esophageal varices in 35 (20.4%), gastrointestinal bleeding in 29 (16.9%) and menorrhagia in 20 (11.6%) patients (Fig. 1).

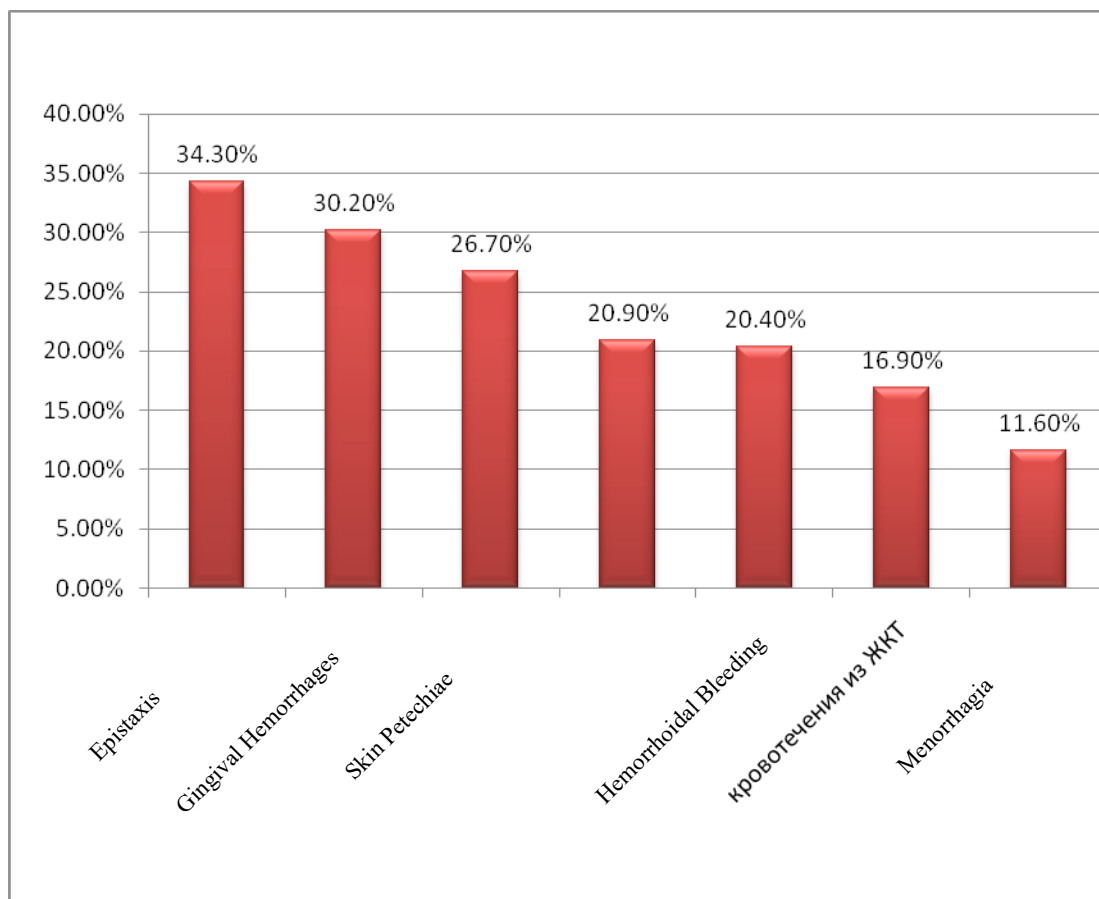


Fig. 1. Degree of incidence of hemorrhagic syndrome in patients with liver cirrhosis and chronic viral hepatitis

Hemorrhagic syndrome with large fluctuations has been found in different patient groups. For example, it was more pronounced in groups 1 and 2. In group 1, symptoms of bleeding occurred in 19 (63.3%) patients, including nasal hemorrhage in 17 (56.7%), gingival bleeding in 17 (56.7%), skin petechiae in 13 (43.3%), hemorrhoidal bleeding in 12(40.0%), bleeding esophageal varices in 12 (40.0%), gastrointestinal bleeding in 10 (33.3%)and menorrhagia in 8 (26.7%) patients.

In group 2, the incidence of hemorrhagic syndrome was highest and was observed in 14 (70.0%) patients. Nasal hemorrhage occurred in 12 (60.0%), gingival bleeding in 13 (65.0%), skin petechiae in 11 (55.0%),

hemorrhoidal bleeding in 8 (40.0%), bleeding esophageal varices in 9 (45.0%), gastrointestinal bleeding in 7 (35.0%), and menorrhagia in 5 (25.0%) patients.

In group 3, symptoms of bleeding occurred in 16 (53.3%) patients. Nasal hemorrhage were observed in 16 (53.3%), gingival bleeding in 13 (43.3%), skin petechiae in 12 (40.0%), hemorrhoidal bleeding in 10 (33.3%), bleeding esophageal varices in 9 (30.0%), gastrointestinal bleeding in 7 (23.3%)and menorrhagia in 4 (13.3%) patients.

Group 4 consisted of patients with liver cirrhosis with negative results for markers of viral hepatitis. In this group, hemorrhagic syndrome was much less pronounced

than that with liver cirrhosis of viral cause. A detailed examination of patients' complaints and medical history followed by physical examination has showed that of hemorrhagic symptoms occurred in 5 (25.0%) patients. Epistaxis occurred in 5 (25.0%), gingival bleeding in 5 (25.0%), skin petechiae in 4 (20.0%), hemorrhoidal bleeding in 3 (15.0%), bleeding esophageal varices in 3

(15.0%), menorrhagia in 4 (20.0%), and gastrointestinal bleeding in 3 (15.0%) patients.

The list of the main complaints of bleeding from patients, and their frequency in different clinical groups are shown in Table 1.

Table 1: Structure of hemorrhagic syndrome in patients with liver cirrhosis and chronic viral hepatitis

Hemorrhagic syndrome	Patient groups					
	Group 1 n=30	Group 2 n=20	Group 3 n=30	Group 4 n=20	Group 5 n=32	Group 6 n=30
Nasal hemorrhage	17 (56,7%)	12 (60,0%)	16 (53,3%)	5 (25,0%)	2 (6,3%)	2 (6,7%)
Gingival bleeding	17(56,7%)	13 (65,0%)	13 (43,3%)	5 (25,0%)	1 (3,1%)	1 (3,3%)
Skin petechiae	13 (43,3%)	11 (55,0%)	12 (40,0%)	4 (20,0%)	2 (6,3%)	1 (3,3%)
Hemorrhoidal bleeding	12 (40,0%)	8 (40,0%)	10 (33,3%)	3 (15,0%)	0	0
Bleeding esophageal varices	12 (40,0%)	9 (45,0%)	9 (30,0%)	3 (15,0%)	0	0
Gastrointestinal bleeding	10 (33,3%)	7 (35,0%)	7 (23,3%)	3 (15,0%)	0	0
Menorrhagias	8 (26,7%)	5 (25,0%)	4 (13,3%)	4 (20,0%)	0	0

Group 5 and 6 consisted of patients with chronic viral hepatitis B and C of moderate activity with no hemorrhagic syndrome. In group 5 of patients with chronic viral hepatitis B, hemorrhagic syndrome occurred in 5 (15.6%) cases: nasal hemorrhage occurred in 2

(12.5%), skin petechiae in 2 (12.5%), gingival bleeding in 1 (3.1%) patients. In group 6 of patients with chronic viral hepatitis C, hemorrhagic syndrome occurred in 4 (13.3%), with nasal hemorrhage in 2 (6.7%), gingival and skin bleeding in 1 (3.3%) patients.

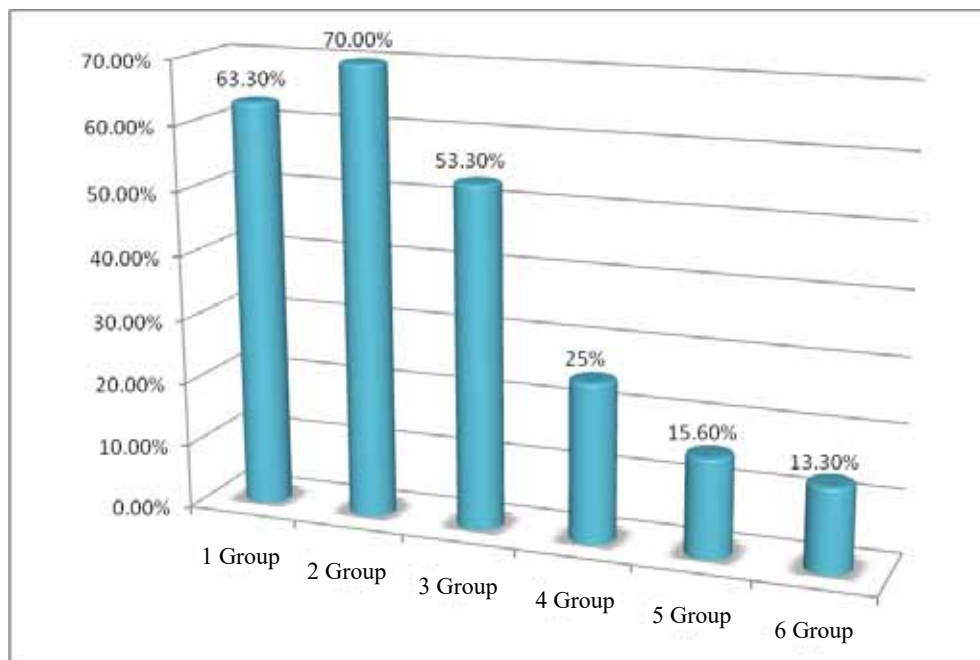


Fig. 2. Degree of incidence of hemorrhagic syndrome in patients with liver cirrhosis and chronic viral hepatitis.

As the above data shows, hemorrhagic syndrome was pronounced in the group of patients with HBV and HBV+HDV liver cirrhosis, in 63.3% and 70.0%, respectively. In the group of patients with HCV liver cirrhosis, bleeding symptoms occurred in 53.3% cases, and in the group with liver cirrhosis of non-viral cause, it was found twice less – in 25% of cases. For example, in chronic viral hepatitis B and C of moderate activity,

hemorrhagic syndrome occurred in 15.6% and 13.3% cases, respectively (Fig. 2).

The study of the hemostatic system in the examined patients allowed us to determine the following structure of the incidence of hemorrhagic diathesis in patients with chronic hepatitis and liver cirrhosis of viral cause (Table 2).

Table 2: Nosological structure of acquired hemorrhagic diathesis in patients with chronic diffuse liver diseases

Groups	Acquired coagulopathies		Acquired thrombocytopenias		Acquired thrombocytopathies	
	abs.	%	abs.	%	abs.	%
Group 1 (n=30)	19	63.3	11	36.7	26	86.7
Group 2 (n=20)	13	65.0	9	45.0	16	80.0
Group 3 (n=30)	15	50.0	16	53.3	21	70.0
Group 4 (n=20)	6	30.0	5	25.0	10	50.0
Group 5 (n=32)	2	6.3	1	3.1	15	46.9
Group 6 (n=30)	1	3.3	2	6.7	13	43.3
Total (n=162)	56	36.3	44	28.3	101	62.9

As the Table shows, a study of the vascular-platelet and coagulation hemostasis links demonstrated that the majority of hemorrhagic diathesis in all groups is represented by acquired thrombocytopathies, while thrombocytopenias and coagulopathies are much less common. Of 30 patients with HBV liver cirrhosis, 26 (86.7%) were diagnosed with acquired thrombocytopathy, while thrombocytopenia in this group was diagnosed in only 11 (36.7%) patients, and acquired coagulopathy - in 19 (63.3%). The same trend was also observed in patients with HBV+HDV and HCV liver cirrhosis. In the group 5 of patients with liver cirrhosis with negative results for markers of viral hepatitis, the incidence of hemostatic pathology was almost 2 times less than that in patients with liver cirrhosis of viral cause. For example, acquired thrombocytopathy occurred in 10 (50%), acquired thrombocytopenia - in 6 (30%), and acquired coagulopathy - in 5 (25%) patients.

Acquired thrombocytopathy was diagnosed in patients with chronic viral hepatitis B in 15 (46.9%), acquired coagulopathy - in 1 (3.1%) and thrombocytopenia and 2 (6.3%) patients. In patients with chronic viral hepatitis C, acquired thrombocytopathy

was diagnosed in 13 (43.3%), acquired coagulopathy - in 1 (3.3%) and thrombocytopenia - in 2 (6.7%) patients.

Conclusions

1. The main hemorrhagic symptoms in patients with chronic hepatitis and liver cirrhosis of viral cause have been divided as follows: nasal hemorrhage in 59 (34.3%) cases, gingival bleeding in 52 (30.2%), skin petechiae in 46 (26.7%), hemorrhoidal bleeding in 36 (20.9%), bleeding esophageal varices in 35 (20.4%), gastrointestinal bleeding in 29 (16.9%) and menorrhagia in 20 (11, 6%).
2. Hemorrhagic syndrome has been found in a group of patients with liver cirrhosis of viral cause: with HBV liver cirrhosis – in 63.3%, with HBV+HDV liver cirrhosis – in 70.0%, with HCV liver cirrhosis - in 53.3% cases. In patients with liver cirrhosis of non-viral cause (group 4), hemorrhagic syndrome has been found more than 2 times less often – in 25% of cases.
3. In chronic viral hepatitis B and C, hemorrhagic syndrome was much less common – in 15.6% and

13.3% cases, respectively. This indicated a lesser violation of the hemostatic system than with liver cirrhosis of viral cause.

4. Since the liver cirrhosis of viral cause is followed by pronounced hemorrhagic syndrome, a detailed study of coagulation and vascular-platelet hemostasis is required for the prevention and treatment of bleeding.

Ethical Clearance: No ethical approval is needed.

Source of Funding: Self

Conflict of Interest: Nil

References

1. Newdiamed PA. Diagnostics and treatment of hemostasis pathology. 2011; 410.
2. Kurkina I.A. OSVMVMVTI. Hemorrhagic syndrome in liver cirrhosis. Russian journal of Gastroenterology, Hepatology and Coloproctology. 2012; 6: p. 14-21.
3. Amarapurkar Pooja D ADN. Management of coagulopathy in patients with decompensated liver cirrhosis. International journal of hepatology. 2011; 2011: p. 74-78.
4. Dahal Sea. Trombocytopenia in Patients with Chronic Hepatitis C Virus Infection. Mediterr J Hematol Infect Dis. 2017.
5. Gangireddy VG, KPC, SS, TS & CT. Management of thrombocytopenia in advanced liver disease. Can J Gastroenterol Hepatol. 2014; 28: p. 558564.
6. Hayashi H, BT, SK, MY & BH. Management of thrombocytopenia due to liver cirrhosis: a review. World J Gastroenterol. 2014; 20: p. 2595–2605.
7. Hartmann M. CS, FH. Hemostasis in liver transplantation: Pathophysiology, monitoring, and treatment. World Journal of Gastroenterology. 2016; 22(4): p. 1541-1550.
8. Huang HS, SDS, LTS & CHH. Dendritic cells modulate platelet activity in IVIg-mediated amelioration of ITP in mice. Blood. 2010; 116: p. 5002–5009.
9. Intagliata NMea. Concepts and Controversies in Haemostasis and Trombosis Associated with Liver Disease: Proceedings of the 7th International Coagulation in Liver Disease Conference.. Thromb Haemost. 2018; 118: p. 1491–1506.
10. Lambert MP & GTB.. Clinical updates in adult immune thrombocytopenia. Blood. 2017; 129: p. 2829–2835.
11. Maan R, dKRJ & VBJ. Management of Trombocytopenia in Chronic Liver Disease: Focus on Pharmacotherapeutic Strategies. 2015; 75: p. 1981–1992.
12. D.M. M. The coagulation cascade in cirrhosis. ClinLiverDis. 2009; 13(1): p. 1-9.
13. Pluta A GKHM. Coagulopathy in liver deaseases. Advanced in Medical Sciences. 2010; 55(1): p. 16-21.
14. A. T. Hemostasis abnormalities in cirrhosis. Curr Opin Hematol. 2015; 22: p. 406.