

INTERNATIONAL MEDICAL SCIENTIFIC JOURNAL

ART OF MEDICINE

Founder and Publisher **North American Academic Publishing Platforms**

Internet address: <http://artofmedicineimsj.us>

E-mail: info@artofmedicineimsj.us

11931 Barlow Pl Philadelphia, PA 19116, USA +1 (929) 266-0862

Chief Editor

Dr. Pascual Izquierdo-Egea

Prof. Dr. Francesco Albano

Dr. Catherine J. Andersen

Prof. Dr. Sandro Ardizzone

Dr. Dmitriy Atochin

Prof. Dr. Antonio Aversa

Prof. Dr. Tamam Bakchoul

Prof. Dr. Pierre-Grégoire Guinot

Prof. Dr. Rainer Haak

Prof. Henner Hanssen

Roy G. Smith

Department of Molecular and Cellular Biology/Department of Medicine

Baylor College of Medicine

Houston, TX 77030, USA

Kalpesh Patel, MD

The Sydney Kimmel Comprehensive Cancer Center

Johns Hopkins Medical Institutions

Baltimore, MD, 21231, USA

Roy G. Smith

Department of Molecular and Cellular Biology/Department of Medicine

Baylor College of Medicine

Houston, TX 77030, USA

Khamdamov Bakhtiyor Bukhara State Medical Institute

Khamdamova Mukhayokhon Bukhara State Medical Institute

Available at <https://www.bookwire.com/>

ISBN: [978-0-578-26510-0](https://www.isbn-international.org/product/978-0-578-26510-0)

Multiparametric MRI diagnosis of soft tissue tumors.
Khodjamova G.A., Nazarova G.U., Valiev Y.Y., Nishanova Y.Kh.
Tashkent Medical Academy

Abstract: The purpose of the study. To evaluate multiparametric MRI for differentiation of benign and malignant soft tissue tumors.

Material and methods: This is a retrospective study of 67 patients (average age 55 years; 18-82 years) with 35 benign and 32 malignant soft tissue tumors. The parameters were compared between benign and malignant tumors.

Results: ADC and D were significantly lower in malignant than benign soft tissue tumors (1170 ± 488 vs. 1472 ± 349 mm²/s; 1132 ± 500 vs. 1415 ± 374 mm²/s; $p < 0.05$). K trans, K ep, V e and iAUC significantly differed between malignant and benign soft tissue tumors (0.209 ± 0.160 vs. 0.092 ± 0.067 min⁻¹; 0.737 ± 0.488 vs. 0.311 ± 0.230 min⁻¹; 0.32 ± 0.17 vs. 0.44 ± 0.28 ; 0.23 ± 0.14 vs. 0.12 ± 0.09 , $p < 0.05$, respectively). ADC (0.752), D (0.742) and ep (0.817) had high AUC. Subgroup analysis showed that only K-trans and iAUC differed significantly in myxoid tumors, while ADC, D, K-trans, K ep and iAUC differed significantly in non-myxoid tumors to differentiate benign and malignant tumors. D, K ep and iAUC were the most significant, predictable malignant soft tissue tumors.

Conclusion: Multiparametric MRI can be useful for differentiating benign and malignant soft tissue tumors using IVIM-DWI and DCE-MRI.

Keywords: IVIM-DWI, DCE-MRI, iAUC,

Introduction. In everyday practice, there are often problems that can distinguish benign soft tissue tumors from malignant ones. The signals of benign and malignant soft tissue tumors may overlap. Recently, diffusion-weighted imaging (DWI) has been used to evaluate soft tissue tumors. The calculation of the apparent diffusion coefficient (ADC) for the random movement of water in tissues may reflect the pathological status of the affected tissue. DWI based on the bi-exponential model of intravoxel incoherent motion (IVIM) by Le Bihan et al. allows to more accurately separate microcapillary perfusion from pure tissue diffusion (V e), as well as a semi-quantitative parameter of the initial area under the time - signal intensity curve (iAUC). The values of these pharmacokinetic parameters for DCE-MRI have rarely been evaluated in soft tissue tumors.. Perfusion characteristics (pseudodiffusion coefficient, D *) and their volume fraction (perfusion fraction, f) can be obtained simultaneously. IVIM-DWI applies the possibility of differentiation of benign and malignant soft tissue tumors. Dynamic contrast MRI (DCE) is reported to be very useful for the characteristics of soft tissue tumors. The application of the Tofts pharmacokinetic model 17, DCE-MRI can obtain three main quantitative parameters: the transfer constant (K trans), the rate constant (K ep) and the extracellular extracellular volume fraction

Despite these developments, there have been inconsistent reports on the use of DWI, IVIM or DCE-MRI for the differentiation of benign and malignant soft tissue

tumors, as well as several reports fully evaluating quantitative multivariate MRI, including IVIM-DWI and DCE-MRI for the differentiation of benign and qualitative soft tissues. tumors. Therefore, the aim of our study was to determine the value of multiparameter MRI for the differentiation of benign and malignant soft tissue tumors.

Methods and materials. This retrospective study has been cancelled. From May 2020 to February 2022, 130 patients were included in the study with the following criteria: (i) the first diagnosis of soft tissue formation (images were examined before histological biopsy and/or the start of treatment), (ii) soft tissue tumors with pathological confirmation by histological biopsy and/or examination of surgical samples, and (iii) underwent 3 T MRI, including IVIM-DWI and DCE-MRI. Among these 130 patients, 63 of the following exclusion criteria were excluded: (i) 30 non-tumor lesions (21 ganglion cyst, 6 epidermoid inclusions and 3 metastases), (ii) 24 well-differentiated adipocytic tumors (20 lipomas). and 4 well-differentiated liposarcomas), (iii) 4 soft tissue tumors smaller than 0.5 cm (2 fibromatoses and 2 glomus tumors), (iv) 4 with unsatisfactory quality in most sequences due to artifacts (three tenosynovial giant cell tumors and one fibromatosis), and (v) one intermediate malignant neoplasm (prominence dermatofibrosarcoma). Finally, the remaining 67 patients (mean age 55 ± 15 years; range from 18 to 82 years) with soft tissue tumors comprised the study population of 30 men (mean age 54 ± 16 years; range from 18 to 82 years) and 37 patients. women (average age 57 ± 15 years; range 26-82 years). Part of the population of this study (and (v) one intermediate malignant neoplasm (protuberant dermatofibrosarcoma). The past 67 patients (mean age 55 ± 15 years; range from 18 to 82 years) with soft tissue tumors comprised the study population of 30 men (mean age 54 ± 16 years; range from 18 to 82 years) and 37 patients. women (average age 57 ± 15 years; range 26-82 years). Finally, the remaining 67 patients (average age 55 ± 15 years; range from 18 to 82 years) with soft tissue tumors were examined by a population of 30 men (average age). age 54 ± 16 years; range from 18 to 82 years) and 37 patients. range from 18 to 82 years) with soft tissue tumors comprised the study population of 30 men (mean age 54 ± 16 years; range from 18 to 82 years) and 37 patients. women (average age 57 ± 15 years; range 26-82 years). Finally, the remaining 67 patients (average age 55 ± 15 years; range from 18 to 82 years) with soft tissue tumors were examined by a population of 30 men (average age). age 54 ± 16 years; range from 18 to 82 years) and 37 patients. range from 18 to 82 years) with soft tissue tumors comprised the study population of 30 men (mean age 54 ± 16 years; range from 18 to 82 years) and 37 patients. women (average age 57 ± 15 years; range 26-82 years). Finally, the remaining 67 patients (average age 55 ± 15 years; range from 18 to 82 years) with soft tissue tumors were examined by a population of 30 men (average age). age 54 ± 16 years; range from 18 to 82 years) and 37 patients. n = 17) comes from a previous study of 20 different measurements and aimed at determining the diagnostic values of multiparameter MRI for the differentiation of benign and malignant soft tissue tumors. Of these patients, six patients (angioliomyoma, fibroma, fibromatosis, glomus tumor, tenosynovial giant

cell tumor and malignant melanoma) were excluded from the IVIM-DWI analysis due to artifacts. All 67 patients were included in the DCE-MRI analysis.

Since it has been reported that the myxoid tumor matrix is part of many benign and malignant soft tissue tumors, we decided to compare quantitative parameters between patients with and without myxoid tumor matrix. For these reasons, the tumors were divided into 19 myxoid and 48 non-myxoid soft tissue tumors for subgroup analysis. Myxoid soft tissue tumors include myxoid liposarcomas (n = 3) and myxofibrosarcomas (n = 3), schwann (n = 8), myxomas (n = 2), neurofibroma (n = 1), fibromyxoid sarcoma of low malignancy (n= 1) and malignant tumor of peripheral nerves (n = 1).

The images were obtained using the 3T system (MAGNETOM Verio, Siemens Healthineers, Erlangen, Germany). The field of view depends on the part of the body. The usual MRI was obtained with coil adjustment. Axial turbo-spinal echo (TSE) images were obtained, weighted by T 1 and TSE T 2, with and without suppression, at least one longitudinal scan with weighted T 2 with fat suppression and longitudinal and axial images with contrast enhancement TSE T 1 with fat suppression. .

IVIM-DWI was obtained using single spin-echo planar imaging. Encoding was performed in three orthogonal directions. A series of nine b values was applied (0, 25, 50, 75, 100, 200, 300, 500 and 800 s/mm²). The obtained imaging data were processed to obtain ADC, parameters obtained on the basis of IVIM, including D (diffusion coefficient), D * (pseudodiffusion) and f (perfusion fraction of proton associated with microcirculation). (Siemens Healthineers). Pixel-based ADC maps were created based on a mono-exponential calculation from DWI with b-values of 0 and 800 s / mm².

For DCE-MRI, Unarmed axial examination T 1 weighted volumetric interpolated breath retention exams (VIBE), data were obtained for processing line T1 cards with flip angles of 2° and 15° before injection of contrast agent. The images were obtained immediately after bolus injection of Gadobutrol (Gadovist, Bayer Healthcare, Leverkusen, Germany) at a rate of 2 ml with -1 forums dose of 0.1 mmol/kg, followed by 20 ml of physiological flush. The total data collection time was 5 minutes. The Tofts pharmacokinetic model was used to calculate perfusion parameters, including the transfer rate constant between blood plasma and extracellular/extravascular space (K trans), the volume of the extracellular/extravascular space (V e), and the intravasation rate constant (K ep), calculated as K trans / V e. The population-averaged arterial input function (AIF) was used with an intermediate type. 22 Semi-quantitative parameters of the initial area under the time-signal intensity curve (iAUC) were also obtained from the intensity-time dependence curve as iAUC for 60 s.

The results obtained

The final diagnosis was established on the basis of histopathology, among the cases included 35 benign and 32 malignant formations. Detailed demographic and histopathological information for the two groups is described in Table 1. The

agreement between the IVIM-DWI observers was considered excellent for ADC and D (ICC = 0.95–0.98), for D* and f (ICC = 0.58–0.65). For DCE-MRI between observers for K trans, K_{ep} and iAUC were considered good (ICC = 0.72–0.74), and for V_e - bad (ICC = 0.38).

Benign group n = 35, malignant group n = 32 p value

Age (years) 53 ± 16

Schwannoma (8), undifferentiated sarcoma (8), Hemangioma (6), Synovial sarcoma (4), angioleiomyoma (4), myxoid liposarcoma (3)

fibromatosis (4), myxofibrosarcoma (3), nodular fasciitis (3), lymphoma (3)

fibroma (2), epithelioid angioendothelioma (2), glomus tumor (2), leiomyosarcoma (2), tenosynovial giant cell tumor (2), angiosarcoma (1), myxoma (2) and fibromyxoid sarcoma (1),

neurofibroma (1), myeloid sarcoma (1), neuroma (1), extra-skeletal mesenchymal chondrosarcoma (1), malignant melanoma (1)

Malignant tumor of the peripheral nerve sheath (1) also malignant solitary fibrous tumor (1)

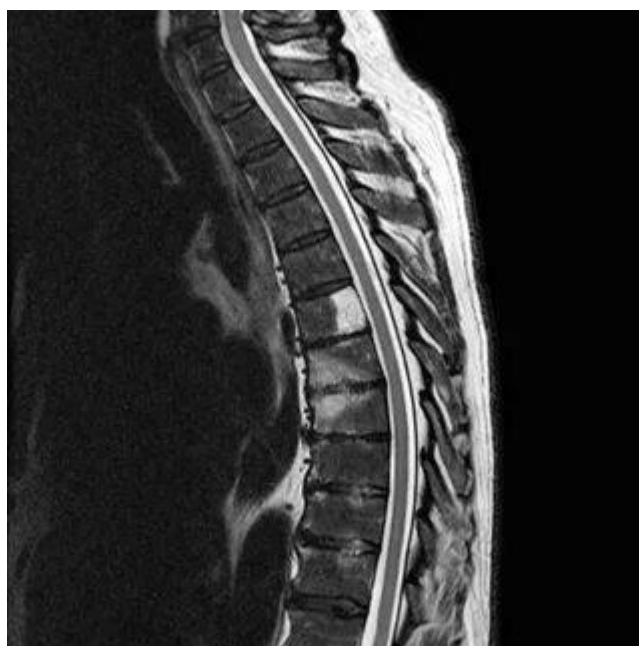

Figure 1. A 50-year-old man with myeloid sarcoma. A, Weighted image of TSE T1 with axial fat suppression and contrast enhancement shows an increasing mass of 2.5 cm (arrows) along the radial nerve in the elbow, simulating a suture. B The mass demonstrates a high signal with a hypointensive area (arrow) at a DVI oo value of b 800 s / mm². C, obstructed water diffusion (arrows) on the ADC map. IVIM-DWI parameters and DCE-MRI parameters suggest a qualitative soft tissue tumor. This case was pathologically confirmed as myeloid sarcoma. D. Results of quantitative multiparametric MRI. ADC, apparent diffusion coefficient; DCE-MRI,

magnetic resonance imaging with dynamic contrast; DWI, diffusion-weighted imaging; IVIM-DWI, intravoxel visualization of incoherent motion, diffusion-weighted; TSE, turbo spin echo.

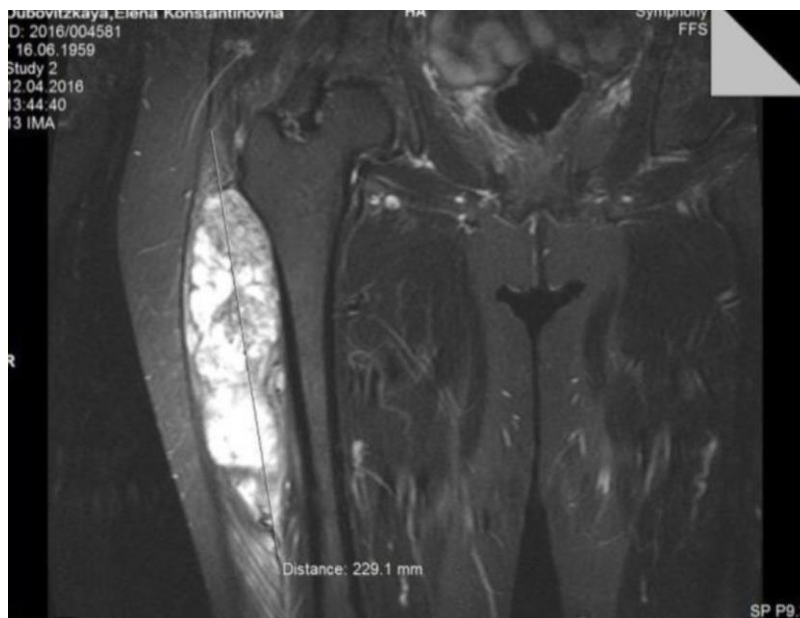


Figure 2.

A woman, 71 years old, has a myxoma. A, Weighted image of TSE T 1 with axial fat suppression and contrast enhancement shows 4 cm of inhomogeneously increasing mass (arrows) in the proximal thigh. B: The bright signal is not displayed on the DWI oo value b 800 s / mm² . C, the mass is hyperintensive (arrows) on the ADC map. IVIM-DWI parameters and DCE-MRI parameters suggest a benign soft tissue tumor. The formation was pathologically confirmed as a myxoma.

Results of quantitative multiparametric MRI.ADC, apparent diffusion coefficient; DCE-MRI, magnetic resonance imaging with dynamic contrast; DWI, diffusion-weighted imaging; IVIM-DWI, intravoxel visualization of incoherent motion, diffusion-weighted; TSE, turbo spin echo.

Benign group Malignant group the value of p. Threshold values
 Sensitivity (%) and specificity (%) accuracy (%) - AUC - area under
 the curve; DCE-MRI, magnetic resonance imaging with dynamic contrast; IVIM
 DWI, intravoxel visualization of incoherent motion, diffusion-weighted.

Among the parameters of DCE-MRI, K trans (209 ± 160 min⁻¹ x 10³), K ep (737 ± 488 min⁻¹ x 10³) and iAUC (23 ± 14%) in malignant tumors were significantly higher than in benign tumors (92 ± 67 min⁻¹ x 10³ , 311 ± 230 min⁻¹ x 10³ and 12 ± 9%, respectively; p <0.001 for all), while V e (32 ± 17%) in malignant tumors was significantly lower than in benign tumors (44 ± 28%, p = 0.043) (Table 2). ROC analysis showed that K-trans has the highest sensitivity of 81% (specificity 77%, cutoff > 110 min⁻¹ x10³, indicating malignancy) with an AUC of 0.792 with statistical significance (p <0.001). K er showed the highest AUC 0817 with statistical

significance ($p < 0.001$), while a value greater than $368 \text{ min}^{-1} \times 10^3$ indicates malignancy (78% sensitivity and 71% specificity). IAUC also showed an AUC of 0.771 with statistical significance ($p < 0.001$), with a value of more than 14% indicating malignancy (sensitivity 72% and specificity 69%).

Subgroup analysis of myxoid soft tissue tumors. There were no significant differences in IVIM-DWI for differentiation of benign and malignant myxoid soft tissue tumors.

AUC - area under the curve; DCE-MRI, magnetic resonance imaging with dynamic contrast; IVIM DWI, intravoxel visualization of incoherent motion, diffusion-weighted

Of the parameters of DCE-MRI, K_{trans} ($122 \pm 73 \text{ min}^{-1} \times 10^3$) and iAUC ($17 \pm 12\%$) in malignant myxoid soft tissue tumors were significantly higher than in benign myxoid soft tissue tumors ($63 \pm 37 \text{ min}^{-1} \times 10^3$ and $8 \pm 5\%$, respectively; $p = 0.035$ and 0.037). ROC analysis showed that K_{ep} has the highest sensitivity of 87% (specificity 63%, cutoff $> 220 \text{ min}^{-1} \times 10^3$, indicating malignancy) with an AUC of 0.750 with statistical significance ($p = 0.001$). The best specificity was achieved with iAUC (specificity 90%, sensitivity 62%, threshold $> 14\%$ indicating malignancy) with AUC 0.761 with statistical significance ($p = 0.001$).

Subgroup analysis of non-myxoid soft tissue tumors. ADC ($979 \pm 300 \text{ mm}^2/\text{s}$) and D ($938 \pm 296 \text{ mm}^2/\text{s}$) in malignant non-myxoid soft tissue tumors were significantly lower than in benign non-myxoid soft tissue tumors ($1,365 \pm 238 \text{ mm}^2/\text{s}$ and $1,294 \pm 249 \text{ mm}^2/\text{s}$, respectively; $p < 0.001$). ROC analysis showed that ADC and D showed the highest sensitivity of 87% (specificity 73 and 79%, threshold values $\leq 1261 \text{ mm}^2/\text{s}$ and $\leq 1183 \text{ mm}^2/\text{s}$, indicating malignancy, respectively) with AUC 0.835 and 0.831 with statistical significance ($p = 0.001$).

K_{trans} ($238 \pm 172 \text{ min}^{-1} \times 10^3$), K_{ep} ($832 \pm 510 \text{ min}^{-1} \times 10^3$) and iAUC ($26 \pm 15\%$) in malignant non-myxoid soft tissue tumors were significantly higher than in benign non-myxoid tumors. myxoid soft tissue tumors ($105 \pm 72 \text{ min}^{-1} \cdot 10^3$, $333 \pm 207 \text{ min}^{-1} \cdot 10^3$ and $14 \pm 10\%$, respectively; $p = 0.001$, < 0.001 and 0.002). ROC analysis showed that K_{trans} , K_{ep} and iAUC showed the same sensitivity of 87% (specificity 66%, 66% and 62%, threshold values $> 110 \text{ min}^{-1} \times 10^3$, $> 358 \text{ min}^{-1} \times 10^3$ and $> 12\%$ indicating malignancy, respectively) with AUC 0.798, 0.855 and 0.766 with statistical significance ($p < 0.001$ for all).

IVIM-DWI parameters were analyzed using step-by-step multidimensional logistic regression analysis, and D (OR, 0.998; 95% CI, 0.997-0.999) was an independent factor for predicting malignancy. DCE-MRI with multivariate logistic regression analysis showed that K_{ep} (OR, 1,004; 95% CI, 1,001–1,006) and iAUC (OR, 1,064; 95% CI, 1,001–1,131) were independent factors for predicting malignancy.

Three forecasting models were developed as follows - the first model, only D; the second model, D in combination with K_{ep} ; the third model, D in combination with K_{ep} and iAUC. ROC analysis of the three logistic regression models showed that the ROC AUC of the predicted probability increased by adding parameters to D

(AUC of the first model 0.750; second model 0.809; third model 0.838) without statistically significant differences ($p = 0.415, 0.406$). and 0.184 between the first and second, second and third, and first and second third respectively)

A graph showing a comparison of ROC between prediction models (D separately, D in combination with Kep and D in combination with Kep and iAUC; AUC, 0.750, 0.809, 0.838, respectively) for predicting malignancy. (AUC,) the area under the curve; ROC), the operating characteristic of the receiver.

D demonstrated a significantly high AUC value, among the parameters of IVIM-DVEI, and the cut-off value of D led to seven false positive cases (two angioleiomyomas, two nodular fasciitis, fibromatosis, fibroma and tenosynovial giant cell tumor, as well as eight false negative cases. (Three myxoid liposarcoma, fibromyxoid sarcoma, malignant tumor of the peripheral nerve sheath, epithelioid hemangioendothelioma, leiomyosarcoma and synovial sarcoma).

Among the DCE-MRI parameters, K trans and K ep showed significantly high AUC values. Based on the threshold value of K trans, eight false positive cases were registered (two hemangiomas, two glomus tumors, fibromatosis, nodular fasciitis, giant cell tenosynovial tumor and angioleiomyoma) of malignancy), and based on the K ep threshold value, there were 10 false positive cases (triangiomas, two cases of nodular fasciitis, schwann, glomus tumor, myxoma neuroma and tenosynovial giant cell tumor) and 7 false negative cases (two myxoid liposarcomas, myxofibrosarcoma, a qualitative tumor of peripheral nerves), epithelioid hemangioendothelioma and synovial sarcoma).

Our study showed that D, ADC, K-trans, K ep and iAUC can be used to differentiate benign and malignant soft tissue tumors. Only the DCE-MRI parameters for K-trans and iAUC allowed differentiating benign and malignant myxoid soft tissue tumors, whereas D, ADC, K-trans, K ep and iAUC can be used to differentiate benign and malignant non-myxoid soft tissue tumors. .

Chang et al. Diagnostic MRI values were reported using depth, size, and heterogeneity to distinguish benign and malignant soft tissue tumors, resulting in 64% sensitivity, 85% specificity, and 77% accuracy. Comparing the results of the study using a standard MRI performed by Chang et al. 23 and the results presented in this study using a multiparameter MRI, we can conclude that adding a multiparameter MRI to a standard MRI can improve diagnostic characteristics when distinguishing malignant soft tissue tumors from benign ones. , because it increased sensitivity (from 71 to 81%) while maintaining similar levels of specificity (from 69 to 83%) and accuracy (from 70 to 79%).

D and ADC differ significantly between qualitative and benign soft tissue tumors with good diagnostic indicators, which is consistent with previous studies. 12.13 We expect D to be better than ADC for differentiating soft tissue tumors because D eliminates tissue perfusion to reflect tissue diffusion more accurately than ADC. 24 However, the AUC values for ADC and D were similar based on ROC analysis (ADC, 0.752; D, 0.742) and multivariate logistic regression analysis, which is consistent with a recent study by Lim et al. 13 Our results contradict a previous

study by Rijswijk et al. 6Raiswake et al . 6 soft tissue tumors were examined using early IVIM-DWI with five values of b (0-701 s/mm²) at 1.5 T and reported that D significantly differs between benign and malignant soft tissue tumors, whereas ADC does not. Early IVIM-DWI with less exposure to b -values at 1.5 T may be one of the reasons for the difference. We also suggest that microcapillary perfusion may be heterogeneous or higher in benign soft tissue tumors than in malignant soft tissue tumors, which seems to favor the difference between ADC and D for differentiation of soft tissue tumors. This assumption is supported by our result that there are no differences in D^* and F between malignant and benign soft tissues, as in the previous study by Lim et al.

We have differences in K -trans, K_{ep} and $iAUC$ between qualitative and benign soft tissue tumors with good diagnostic indicators. Our results are similar to those of Leplat et al. 19, which show that only K -trans differs only between malignant and benign soft tissue tumors. However, we observed some discrepancies in K_{ep} , $iAUC$ and K trans, which could be related by different methods of AIF selection and ROI measurement. Leplat et al Used automatic program selection of AIFs, which increased most intensively on the AUC map. Our study showed that among the quantitative parameters of DCE-MRI, K_{ep} has the highest AUC in ROC analysis (K_{ep} , 0.817; K trans, 0.792; $iAUC$, 0.771) and multivariate logistic regression analysis, as in the previous study. Oto et al. It was found that the best correlation between the quantitative parameters of perfusion and the histological parameters of angiogenesis was noted between EP and microvascular density. K_{ep} is the K -trans/ V_e index, and the effect of mixing K -trans and V_e may be the organism of a better correlation of K_{ep} and microvascular density.

Our study showed that soft tissue tumors are better recognized when evaluated using a combination of IVIM-DWI and DCE-MRI than when evaluated using IVIM-DWI alone. The subgroup analysis of our study classified benign and qualitative soft tissue tumors into two groups: the myxoid and non-myxoid subgroups demonstrated by ADC and D did not differ between benign and malignant myxoid soft tissue tumors. Although the classification of myxoid soft tissue tumors based on the WHO classification does not include peripheral nerve sheath tumors, myxoid soft tissue tumors, we classified peripheral nerve sheath tumors as myxoid soft tissue tumors because they histologically contain a small myxoid component. As the results of the subgroup analysis show, IVIM-DWI has limitations in the differentiation of soft tissue tumors, since ADC is affected by the extracellular matrix, as well as by the cellularity. Regardless of benign soft tissue tumors, the myxoid matrix is of varying degrees, which causes an obstacle of ADC values between benign and malignant soft tissue tumors. This was analyzed by a subgroup in our study of previous studies. The ADC and D of malignant myxoid soft tissue tumors were slightly higher than those of benign myxoid soft tissue tumors, although there was no significant difference ($p > 0.05$). We think that these results influenced the inclusion of peripheral nerve sheath tumors in the subgroup of myxoid soft tissue tumors. In this schwann, which has a

relatively small myxoid component, is included in the benign subgroup, the ADC and D of the benign subgroup were lower than those in the subgroup of malignant tumors.

Conclusion. Our study had several limitations. Firstly, it was conducted retrospectively in one institution with a limited number of subjects. The use of systematic errors of sequential selection is continued. Secondly, the induction areas may contain calcifications of soft tissue tumors that affect ADC values, since calcifications cannot be completely excluded on MRI. Finally, we did not evaluate conventional MRI, because it is subjective, designed to improve the quality indicators of soft tissues in clinical practice. tissue compared to traditional MRI alone. We expect this assessment to be carried out in future studies.

Thus, quantitative analysis of multiparametric MRI, including IVIM-DWI and DCE-MRI, makes it possible to better differentiate benign and malignant soft tissue tumors. In particular, in myxoid tumors, the DCE-MRI parameters for K-trans and iAUC make it possible to differentiate benign and malignant myxoid soft tissue tumors.