

# CAJM

Central Asian Journal of Medicine

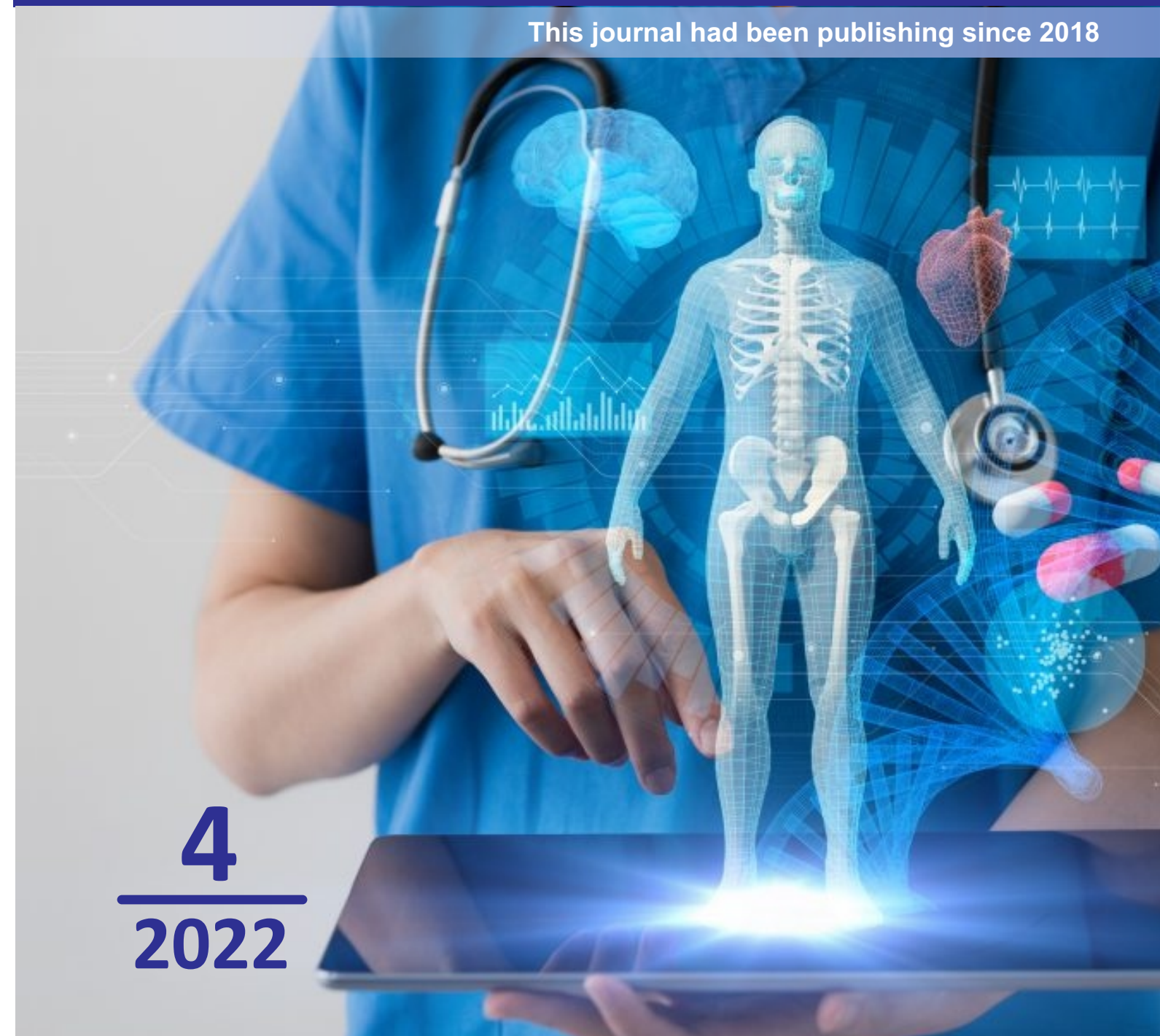


Tashkent Medical  
Academy Press

eISSN: 2181-1326

Scientific Journal

This journal had been publishing since 2018



**4**  
**2022**

eISSN 2181-1326



9 772181 132009



MINISTRY OF HIGHER AND SECONDARY SPECIALIZED  
EDUCATION OF THE REPUBLIC OF UZBEKISTAN

2030

UZBEKISTAN RESEARCH ONLINE

OAK.uz

Supreme Attestation Commission at the Cabinet  
Ministers of the Republic of Uzbekistan



Google Scholar

**Ministry of Health of the Republic of Uzbekistan  
Tashkent Medical Academy**

---

---



**Central Asian Journal of Medicine**

**№ 4 / 2022**

**Tashkent**

## THE STUDY OF PATHOMORPHOLOGICAL DIAGNOSIS OF VITAL ORGANS AFTER MODERN TREATMENT OF DIABETIC FOOT SYNDROME

Ulugbek Y.Ergashev<sup>1</sup>, Adkhamjon R. Zokhirov<sup>2</sup>, Khojimurod I. Ernazarov<sup>3</sup>,  
Ravshankhuja R. Minavarkhyjayev<sup>4</sup>, Behzod A. Abdusalomov<sup>5</sup>

1 Professor, MD, Head of department General surgery №2 of the Tashkent Medical Academy, Uzbekistan

2 Assistant of department General surgery №2 of the Tashkent Medical Academy, Uzbekistan

3 Assistant of department General surgery №2 of the Tashkent Medical Academy, Uzbekistan

4 Assistant of department General surgery №2 of the Tashkent Medical Academy, Uzbekistan

5 Assistant of department General surgery №2 of the Tashkent Medical Academy, Uzbekistan

### ABSTRACT

Study of the effect of the new drug "Rheomannisol" on vital organs, taking into account pathomorphological aspects in the complex treatment of experimental diabetic foot syndrome.

**Key words:** experimental model of diabetic foot, experimental animals, diabetes mellitus, alloxan, surgical debridement, reomannisol.

### INTRODUCTION

Diabetes mellitus (DM) is a chronic disease characterized by relative or absolute insufficiency of insulin, resulting in metabolic disorders that are the main cause of late complications of DM [1]. Early disability and high mortality among DM patients have made the treatment of this disease one of the priorities of national health systems [2]. In light of this, the search for new methods of treatment and the discovery of drugs that are easy to use and have minor side effects remain an urgent problem in medical science today [3]. To conduct such

studies in the field of diabetology, various models of DM are used, one of which is the alloxan model [4].

Morphological aspects of the healing of complicated human wounds have not been sufficiently developed, approaches to wound treatment are ambiguous, especially in relation to the wound process against the background of diabetes mellitus [1]. Wound healing proceeds according to the general laws and standard principles of tissue regeneration. The pace of this process, its outcome depends on the degree and depth of wound damage, the structural features of the affected organ, the general condition of the body, and the methods of treatment used. The problem of stimulation of reparative and regenerative processes and the fight against pathogenic microflora in a purulent wound against the background of diabetes mellitus remains extremely urgent [4]. At the same time, the issue of local treatment of the wound process against the background of diabetes mellitus remains insufficiently studied, despite the variety of means and methods proposed for this purpose [5].

The problem of violations of several types of metabolism with the introduction of alloxan, the prevalence of manifestations of oxidative stress as a typical pathological process in case of damage to the key organ involved in all types of metabolic processes (liver) dictate the need to prescribe pathogenetic drugs from the group of metabolic correctors with hepatoprotective and antioxidant orientation. One of the promising new drugs in this area is Rheomannisol (JV REKA-MEDFARM LLC Republic of Uzbekistan) - a complex drug with antihypoxic, antioxidant, rheological, anti-shock, detoxifying, diuretic effects. The main pharmacologically active substances are sodium succinate and mannitol.

**Purpose of the study.** Study of the effect of the new drug "Rheomannisol" on vital organs, taking into account pathomorphological aspects in the complex treatment of experimental diabetic foot syndrome.

**Materials and research methods.** The work was done on experimental material. Healthy rats were selected for the experiment. Experimental studies were carried out on 110 outbred male rats weighing 220-250 g, kept in the TMA vivarium. The rats were kept under optimal conditions, all rats lived in a room with a 12-hour light-dark cycle and a constant temperature of 22-25°C, with free access to water. All rats were given sufficient normal ad libitum rodent diet (rodent diet, GOST R50258-92) and tap water daily. Operations and all manipulations with animals were carried out using general anesthesia, in compliance with the principles of humanity set forth in the directives of the European Community (86/609/EEC) and the Declaration of Helsinki, in accordance with the "Rules for working with experimental animals". The experimental animals were divided into

3 groups: the 1st group was intact; 2nd control group - against the background of alloxan diabetes, the creation of an experimental model of a diabetic foot using traditional complex treatment; 3rd experimental group - on an experimental model of diabetic foot - traditional treatment and reomannisol.

After a 24-hour fast, the rats were weighed and a solution of alloxan 2%, diluted in 0.9% saline, was administered to the animals intraperitoneally as a single dose, corresponding to a dose of 20, 15, 12 mg of alloxan per 100 g of animal weight. Food and water were given to the animals only 30 minutes after the administration of drugs. On the 3rd day, the level of glucose in the blood was assessed. Determination of glucose concentration in the peripheral blood of animals. Diabetes was confirmed 3 days after the determination of the concentration of glucose in the blood. Peripheral blood glucose concentration was measured with an AccuChekActive glucometer (RocheDiagnostics, Germany), the linear measurement range was 0.6–33.3 mmol/L. Blood sampling to study the level of glycemia was performed from an incision in the tip of the tail. An experimental model of diabetes mellitus (type I DM) has been developed [5]. The day of verification of diabetes mellitus was considered the zero day of its development (DM).

**Surgical procedure.** On the day of verification, the skin surface of the right footpad was shaved and cleaned with a 70% ethanol wipe. On the skin of the foot pad of the right hind paw of each rat, a full-thickness rectangular wound measuring 2 mm × 5 mm was created with a scalpel [6]. The scalpel and scissor wounds (Day 0) were similar in size and shape with minimal or no bleeding in all groups. Every day, the wounds were treated with the traditional method of treatment (5% alcohol solution of iodine and levomekol ointment) until the end of the experiment, also for the experimental group, in addition to the local traditional method of treatment, a new drug Reomannisol (JV LLC REKA-MEDFARM, Republic of Uzbekistan) was used, which was administered intraperitoneally once a day for 5 days, in single doses of the therapeutic range for humans, taking into account differences in relative body surface area [7]. In all cases, the mean dose of the study range was 1 ml of Rheomannisol per 100 g of the calculated mean therapeutic dose equivalent (EMTD).

The development of the disease was assessed by the condition of the animals, lethality was recorded in groups, and recorded by clinical symptoms (polyuria, polydipsia, polyphagia, weight loss, coat) and blood glucose levels. The wool of animals normally has a peculiar luster and is usually adjacent to the skin.

The amount of water drunk by the rats was determined individually by measuring its volume with a measuring cylinder before and after the animals took

water. To assess the daily values of diuresis, individual urine collection was performed using urinals.

Rats were taken out of the experiment by decapitation on the 1st, 3rd, 7th, 10th, 14th days.

Evaluation of the effectiveness of the drug was carried out on the basis of, also, a visual examination of the animals and their wounds. The criteria for the effectiveness of the drug for the wound were: focusing on the severity and duration of inflammatory manifestations in the wound area (edema, hyperemia, wound exudate), the state of the wound bottom; the appearance of granulation tissue; reduction in the area of the wound defect; the appearance of marginal epithelialization; acceleration of wound healing.

The L.N. test was used to determine the area of the wound. Popova (1942). A sterile cellophane plate is placed on the wound and the contour of the wound is applied to it. The drawing is transferred to graph paper and the area of the wound is calculated.

$$\Delta S = \frac{(S - S_n) \cdot 100}{S \cdot t}$$

Where  $\Delta S$  is the desired value in  $\text{cm}^2$ ;

$S$  is the area of the wound in the previous measurement in  $\text{cm}^2$ ;

$S_n$  - the size of the area of the wound at the moment in  $\text{cm}^2$ ;

$t$  is the number of days between measurements.

Method of statistical analysis. The obtained data were statistically processed on a Pentium IV personal computer using the Microsoft Excel program. In addition, methods of traditional variational parametric and nonparametric statistics were used. To establish the reliability of the obtained results, the coefficient  $t$  - Student was used [8]. Differences were considered significant if the frequency for the studied trait did not exceed 5% ( $P < 0.05$ ).

Pieces from a diabetic foot, pancreas, and liver were fixed in Carnoy's solution (the composition of the fixative was glacial acetic acid, 10 parts; chloroform, 30 parts; ethyl alcohol, 60 parts). Fixing the pieces for 2-4 hours, then placing the pieces in 96% alcohol. Carrying out the wiring in the usual way and pouring in paraffin. Making histological sections with a thickness of 5-6 microns on a sledge microtome, deparaffinization on a thermostat and staining with hematoxylin and eosin. It is the most common method of staining histological sections. Paraffin sections are deparaffinized in chloroform and washed in distilled water, then a hematoxylin solution is poured onto the sections for 3 min [9].

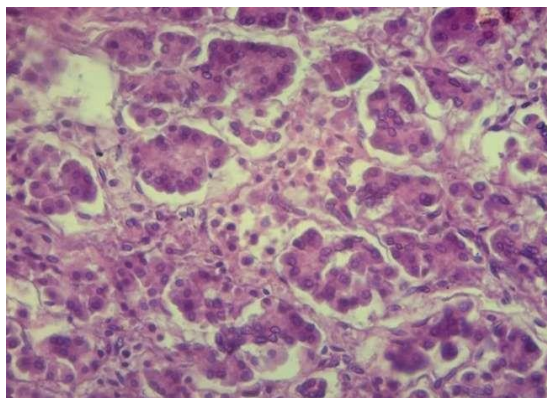
Washing in tap water for 10 minutes and sections are counterstained with eosin from 0.2 to 3 minutes, depending on the thickness of the sections. They are dehydrated in alcohols of increasing concentration, starting from 70° to 96°, clarified in carbol-xylene, xylene and placed in a balm. Result: cell nuclei are stained blue-violet, cytoplasm - pink [10]. Method of luminescent microscopic examination.

Statistical processing of digital data was carried out using the SPSS 16.0 and Statistica 6.0 for Windows application programs. Means and standard deviations, medians and interquartile intervals, as well as non-parametric methods (Mann-Whitney, Wilcoxon, Kruskal-Wallis tests) were determined. Analysis of the probability of occurrence of the studied outcome in a certain period of time (survival) was performed according to the method of E. Kaplan - P. Meier. Cox stepwise regression analysis was used to identify several risk factors for survival. The analysis of the accuracy and practical value of prognostic factors and the validity of the models were measured by the method of concordant (c-statistic) statistics (estimation of the area under the ROC-curve).

**Research results.** The body weight of rats before the experiment varied from 220 to 250 g. Group 1 - intact animals (10 rats each), served as controls for groups 2 and 3. The rats were given intraperitoneal 2% alloxan at a dose of 12 mg per 100 g, the 2nd control group was created on 50 rats and the 3rd experimental group n=50 rats. In both groups until the end of the experiment (17 days) no death was recorded.

**Visual inspection.** The first signs of diabetes were manifested in the form of a sharp increase in water consumption of 70-80 ml, polyphagia, polyuria, hyperglycemia. With alloxan-induced diabetes mellitus in animals during the experiment, lethargy, apathy, low activity, tarnishing and loss of coat, weight loss, clouding of the pupil and sclera, small-point erosion in the tails and limbs were noted. The wool of animals normally has a peculiar luster and is usually adjacent to the skin. In dynamic observation in rats of the experimental group, by the seventh day, the condition of the animals and appetite began to improve, they became active, slightly aggressive, the frequency of the coat increased, ulcers on the skin surface healed, polyuria and polydipsia began to decrease. Rare grooming appeared in animals of the control group, but no shine of wool was noted, they remained aggressive, ulcers on the skin surface did not heal. By 10 days in rats from the experimental group, the neatness of the coat was restored, erosion in the body disappeared. In the control group, until the end of the experiment, apathy, lethargy remained, they sat more in the corner of the cage, when picked up, the animals remained aggressive, grooming did not fully recover.

**Histological observations. Control group. Pancreas.** The results of a morphological study of the pancreas after traditional treatment on the 3rd and 7th days of the experiment showed the preservation of severe atrophy of the endocrine islets and the growth of connective tissue along the interstitium of the gland. At the same time, endocrine cells are few in number, scattered, almost all cells are in a state of dystrophy and destruction. The interstitial tissue of the pancreas is thickened due to edema and proliferation of fibrous structures and an increase in the number of histiocytic cells. The exocrine glands are destructive and deformed, merge with each other in places, the nuclei of the glandular epithelium are in the form of vacuolization of the karyoplasm. On the 10th day after treatment with the traditional method, a widespread arrangement of endocrine cells along the interstitial connective tissue was noted in the pancreatic tissue (Fig. 1). At the same time, these cells are concentrated around the vessels and are characterized by a relatively wide eosinophilic cytoplasm and hyperchromic nuclei. In the interstitium of the gland, there is also an overgrowth of connective tissue in the form of an increase in fibrous structures and a disorderly arrangement of histiocytic cells. The exocrine glands, in contrast to the previous period of the study, are somewhat scattered due to the thickening of the interstitial tissue. Glandular cells of various shapes and sizes with swelling of exocrine cells, in which the nuclei are located on the basal part of the cell. On the 14th day of treatment by the traditional method, the above described pathomorphological changes persist, of which interstitial sclerosis intensifies.

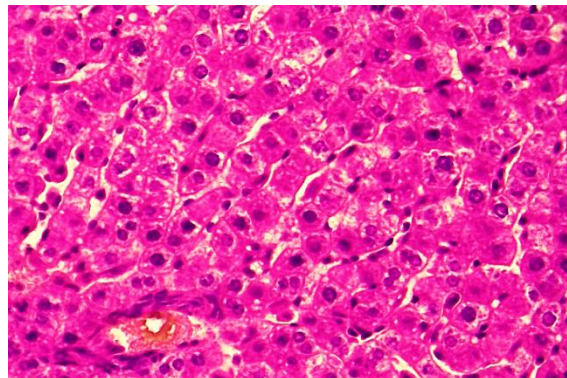


**Figure 1.** Morphological picture of the pancreas, traditional treatment, day 10. Diffuse arrangement of endocrine cells in the interstitium of the gland. Coloring: G-E. SW: 10x40.

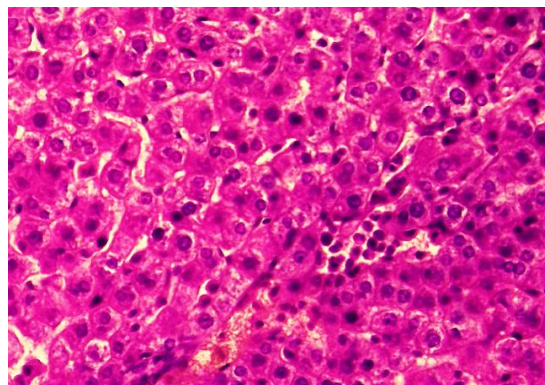
**Liver.** The results of microscopic examination of the liver tissue on the 7th day after the traditional treatment of alloxan diabetes in the liver, the degree of vacuolar degeneration of hepatocytes slightly decreases. More pronounced vacuolar dystrophy remains in the second morphofunctional zone of the liver parenchyma lobules. Where vacuolar degeneration of hepatocytes sometimes ends



with necrobiosis and necrosis of liver cells. In the third and first morphofunctional zones of the liver lobules, hydroptic dystrophy is less pronounced, which is manifested by loosening and uneven staining of the hepatocyte cytoplasm. The nuclear structures of hepatocytes are of various shapes and sizes, most of them are in a state of karyopyknosis and karyolysis. Perisinusoidal space is somewhat expanded, in some of them the presence of single leukocytes is determined. On the 10th day after the traditional treatment of alloxan diabetes in the liver, dystrophic changes in hepatocytes are relatively reduced. As mentioned above, in the second morphofunctional zone of the liver lobules, small droplet vacuolar dystrophy (Fig. 2) of the hepatocyte cytoplasm is preserved. The central vein, sinusoids, and Disse space remain somewhat dilated and plethoric. On the 14th day of the study, it is noted that in some places a small focus of inflammatory infiltration by lymphoid cells appeared in the liver tissue (Fig. 3). On the part of the liver parenchyma, compared with the previous periods, stabilization of dystrophic changes in hepatocytes is noted, only in some hepatocytes small droplet vacuolar dystrophy persists. At the same time, the nuclear structures of the liver cells are somewhat enlarged and hyperchromic.



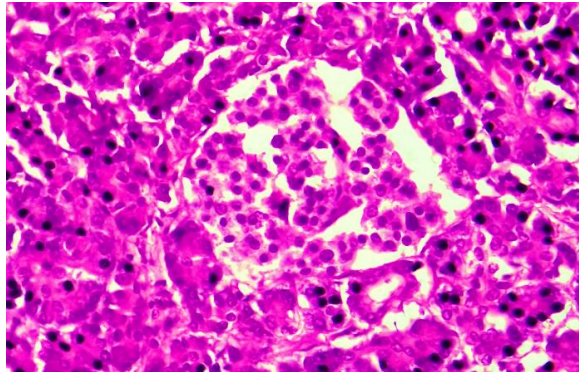
**Figure 2.** Morphological picture of the liver, traditional treatment, day 10. Stabilization of dystrophic changes in hepatocytes. Coloring: G-E. SW: 10x40.



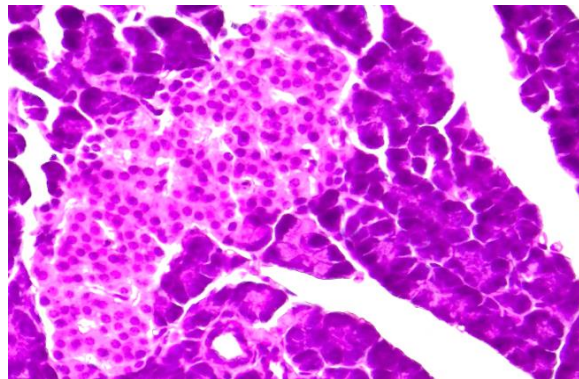
**Figure 3.** Morphological picture of the liver, traditional treatment, day 14. In the liver tissue, the appearance of foci of inflammatory infiltration. Coloring: G-E. SW: 10x40.

**Experienced group. Pancreas.** On the 7th day after the treatment of alloxan diabetes with rheomannisol, an increase in the number of cells was noted in the

islets of the endocrine part of the pancreas due to an increase in proliferative activity. At the same time, large and small, mainly hyperchromic activated cells are determined among the endocrine cells (Fig. 4). The activity of these cells is determined by the state of the cytoplasm, which is also strongly stained with eosin, which indicates an increase in the secretory substance in the cytoplasm. Exocrine glands are in a state of edema, dystrophy of cells, the nuclear structures of which are shifted to the periphery of the cell. By the 10th day after the treatment of alloxan diabetes with rheomannisol, increased hyperplasia of the cells of the endocrine islets is noted, among which the presence of cells of different sizes, staining and proliferative activity is determined. The area of the islet of Langerhans is expressed expanded, the entire area is filled with cells, most of which are in a state of proliferative activity. The cytoplasm and intercellular substance are filled with a mass intensely stained with eosin. The above morphological changes, showing the activation of the endocrine part of the gland, continue on the 14th day of the experiment (Fig. 5). The exocrine glands remain compressed due to interstitial edema.



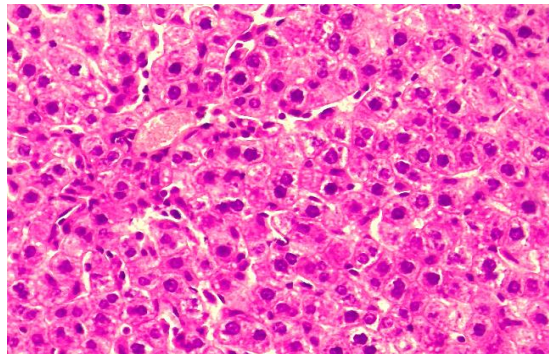
**Figure 4.** Morphological picture of the pancreas, treatment with rheomannisol, day 7. An increase in the number of cells in the islet apparatus. Coloring: G-E. SW: 10x40.



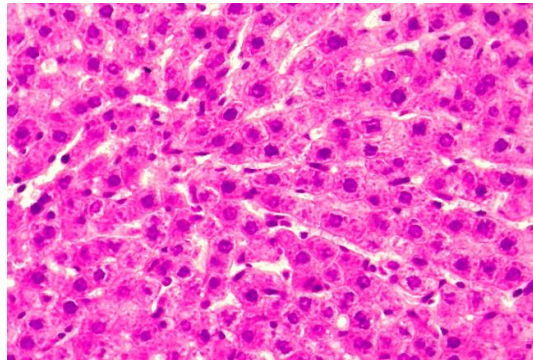
**Figure 5.** Morphological picture of the pancreas, treatment with rheomannisol, day 14. Hyperplasia of cells of the endocrine islets. Coloring: G-E. SW: 10x40.

**Liver.** On the 3rd day after the treatment of alloxan diabetes with rheomannisol, stabilization and a decrease in the severity of dystrophic changes in

the cytoplasm of hepatocytes are noted, only in some cells is the persistence of small droplet vacuolar dystrophy to an insignificant degree (Fig. 6). Due to parenchymal dystrophy of hepatocytes, discomplexation and violation of the beam structure, uneven narrowing of both the sinusoids and the space of Disse are noted. At this time of the experiment, some hypertrophy of Kupffer cells and an increase in the proliferative activity of histiocytic cells were noted in the stroma-vascular system. In the subsequent terms (7, 10 days) of the study of the liver after treatment with raomannisol, the complete disappearance of vacuolar dystrophy of the cytoplasm of hepatocytes is noted (Fig. 7), only a reduced eosinophilicity of some hepatocytes is determined. The cytoplasm of the main masses of hepatocytes is intensely stained with eosin, which indicates an increase in metabolic processes and the accumulation of useful protein substances in the cytoplasm of hepatocytes. Also, there is an increase in the activity of nuclear structures of hepatocytes in the form of intense staining of chromatin with hematoxylin. On the part of the stroma-vascular system of the liver tissue, there are signs of proliferative activity of both histiocytic and Kupffer cells. By the 14th day after the treatment of alloxan diabetes with rheomannisol, in the liver tissue, compared with the previous periods, there is a complete disappearance of dystrophic, destructive changes in hepatocytes. Only, a slight expansion of some sinusoids and hypertrophy of Kupffer cells is determined. At the same time, hepatocytes are located along the beams and retain their histotopography. Their cytoplasm is hyperchromic due to increased eosinophilicity and the appearance of intensely stained protein masses in the cytoplasm is noted. The nuclear structures of hepatocytes are enlarged, hyperchromic, and there are binuclear cells.



**Figure 6.** Morphological picture of the liver, treatment with rheomannisol, day 3. Reducing dystrophic changes in hepatocytes. Coloring: G-E. SW: 10x40.



**Figure 7.** Morphological picture of the liver, treatment with rheomannisol, 10 days. Disappearance of vacuolar dystrophy, increased eosinophilicity of the cytoplasm of hepatocytes. Coloring: G-E. SW: 10x40.

### **Conclusion.**

1. The use of the drug rheomannisol in an experimental model of diabetic foot in the pancreas shows stabilization of dystrophic, destructive changes in both the endocrine and exocrine parts of the gland. There is a restoration of the islet apparatus in the form of hyperplasia and hyperchromasia of endocrine cells, which are morphological criteria for proliferative activity and an increase in the functional state of the endocrine part of the gland.

2. The morphological picture in the liver is noted from the first days of the experiment, the stabilization of general pathological processes, the disappearance of dystrophic and destructive changes, the restoration of the histotopography of the liver parenchyma, the beam structure of hepatocytes. The cytoplasm of hepatocytes acquires eosinophilic staining due to increased metabolism and restoration of the function of the liver parenchyma.

**Conclusion.** A morphological study of the pancreas and liver in dynamics after treatment with rheomannisol showed a complete restoration of the functional abilities of the organs in the early stages of the experiment.

### **REFERENCES**

1. Bennett W.L., Maruthur N.M., Singh S. et al. Comparative effectiveness and safety of medications for type 2 diabetes: an update including new drugs and 2-drug combinations // *Ann. Intern. Med.* — 2011. — Vol. 155, N 1. — P. 67–68.
2. Eidi M., Eidi A., Saeidi A. et al. Effect of coriander seed (*Coriandrum sativum* L.) ethanol extract on insulin release from pancreatic beta cells in streptozotocin-induced diabetic rats // *Phytother. Res.* — 2009. — Vol. 23. — P. 404–406.

3. Ergashev U. Y. et al. Treatment of idiopathic thrombocytopenic purpura: prevention of hormonal complications in the stomach and duodenum //Central Asian Journal of Medicine. – 2020. – T. 2020. – №. 2. – C. 5-28.

4. Ergashev U. Y., Ernazarov Kh. I., Zohirov A. R., Alzabni I. D. 2022. Complex Treatment of Experimental Model of Diabetic Foot Syndrome. American Journal of Medicine and Medical Sciences 2022, 12(5): 471-480. DOI:10.5923/j.ajmms.20221205.05.

5. Ernazarov Kh.I., Zohirov A.R., Ergashev U.Yu., Israilov R.I. Pathological picture of vital organs in an experimental model of diabetic foot. Herald TMA № 1, 2022. 74-79. e-mail: rio-tma@mail.ru. rio@tma.uz

6. Karimov Sh. I., Axmedov R. M., Ergashev U. Yu. Poglotitel'no videlitel'naya funktsiya pecheni u bol'nix s mexanicheskoy jeltuxoy do i posle endobiliarnix vmeshatel'stv //Vestnik xirurgii. – 1992. – T. 148. – №. 1. – S. 138.

7. Guillemin, Y., Le Broc, D., Ségalen, C., Kurkdjian, E., and Gouze, J.N. 2016. Efficacy of a collagen-based dressing in an animal model of delayed wound healing. J. Wound Care 25: 406–413. [medline] [CrossRef]

8. Mustafakulov G. I. et al. Splenectomy for hairy cell leukemia //Central Asian Journal of Medicine. – 2021. – T. 2021. – №. 4. – C. 160-167

9. Mustafakulov G. I., Ataxodjaeva F. A., Ergashev U. Yu. Idiopaticeskaya trombotopenicheskaya purpura pri beremennosti //Jurnal teoreticheskoy i klinicheskoy medisini. – 2020. – №. 1. – S. 104-107.

10. Vergouwe Y., Soedamah-Muthu S., Zgibor J. et al. Progression to microalbuminuria in type 2 diabetes: development and validation of prediction rule // Diabetologia. — 2010. — Vol. 53. — P. 254–262.