

БИМЕДИЦИНА ВА АМАЛИЁТ ЖУРНАЛИ


8 ЖИЛД, 3 СОН

ЖУРНАЛ БИМЕДИЦИНЫ И ПРАКТИКИ

ТОМ 8, НОМЕР 3

JOURNAL OF BIOMEDICINE AND PRACTICE

VOLUME 8, ISSUE 3



Бош муҳаррир:

Ризаев Жасур Алимжанович
тиббиёт фанлари доктори, профессор,
Самарқанд давлат тиббиёт университети ректори
ORCID ID: 0000-0001-5468-9403

Бош муҳаррир ўринбосари:

Зиядуллаев Шухрат Худайбердиевич
тиббиёт фанлари доктори, Самарқанд давлат тиббиёт
университети Илмий ишлар ва инновациялар бўйича
проректори, **ORCID ID:** 0000-0002-9309-3933

Масъул котиб:

Самиева Гулноза Утқуровна
тиббиёт фанлари доктори, доцент,
Самарқанд давлат тиббиёт университети
ORCID ID: 0000-0002-6142-7054

Нашр учун масъул:

Шаханова Шахноза Шавкатовна
PhD, Самарқанд давлат тиббиёт университети,
онкология кафедраси
ORCID ID: 0000-0003-0888-9150

ТАХРИРИЯТ КЕНГАШИ:

Арипова Тамара Уктамовна

*Иммунология ва инсон геномикаси институти директори –
тиббиёт фанлари доктори, профессор, Ўзбекистон
Республикаси Фанлар академияси академиги*

Jin Young Choi

*Сеул миллий университети Стоматология мактаби оғиз ва
юз-жағ жаррохлиги департаменти профессори, Жанубий
Кореянинг юз-жағ ва эстетик жаррохлик ассоциацияси
президенти*

Абдуллаева Наргиза Нурмаатовна

*тиббиёт фанлари доктори, профессор, Самарқанд
давлат тиббиёт университети проректори, 1-клиникаси бош
врачи. **ORCID ID:** 0000-0002-7529-4248*

Худоярова Дилдора Рахимовна

*тиббиёт фанлари доктори, доцент, Самарқанд давлат
тиббиёт университети №1-сон Акушерлик ва гинекология
кафедраси мудири
ORCID ID: 0000-0001-5770-2255*

Орипов Фирдавс Суръатович

*тиббиёт фанлари доктори, доцент, Самарқанд давлат
тиббиёт университети Гистология, цитология ва
эмбриология кафедраси мудири
ORCID ID: 0000-0002-0615-0144*

Мавлянов Фарход Шавкатович

*тиббиёт фанлари доктори, Самарқанд давлат тиббиёт
университети болалар жаррохлиги кафедраси доценти
ORCID ID: 0000-0003-2650-4445*

Акбаров Миршавкат Мирлоимович

*тиббиёт фанлари доктори, В.Ваҳидов номидаги
Республика ихтисослаштирилган жаррохлик маркази*

Саидов Саидамир Аброрович

*тиббиёт фанлар доктори,
Тошкент фармацевтика институти
ORCID ID: 0000-0002-6616-5428*

Бабалжанов Ойбек Абдужаббарович

*тиббиёт фанлари доктори, Тошкент педиатрия
тиббиёт институти, Тери-таносил, болалар
тери-таносил касалликлари ва ОИТС
ORCID ID: 0000-0002-3022-916X*

Теребаев Билим Алдамуратович

*тиббиёт фанлари номзоди, доцент, Тошкент
педиатрия тиббиёт институти Факультет болалар
хирургия кафедраси. **ORCID ID:** 0000-0002-5409-4327*

Юлдашев Ботир Ахматович

*тиббиёт фанлари номзоди,
Самарқанд давлат тиббиёт университети
№2-сон Педиатрия, неонатология ва болалар
касаликлари пропедевтикаси кафедраси доценти.
ORCID ID: 0000-0003-2442-1523*

Ибрагимова Малика Худайбергандовна

*тиббиёт фанлари доктори, профессор
Тошкент давлат стоматология институти
ORCID ID: 0000-0002-9235-1742*

Рахимов Нодир Махамматкулович

*тиббиёт фанлари доктори, Самарқанд давлат
тиббиёт университети, онкология кафедраси доценти
ORCID ID: 0000-0001-5272-5503*

Саҳифаловчи: Хуршид Мирзахмедов

Контакт редакций журналлов. www.tadqiqot.uz

ООО Tadqiqot город Ташкент,
улица Амира Темура пр.1, дом-2.
Web: <http://www.tadqiqot.uz/>; E-mail: info@tadqiqot.uz
Тел: (+998-94) 404-0000

Editorial staff of the journals of www.tadqiqot.uz

Tadqiqot LLC The city of Tashkent,
Amir Temur Street pr.1, House 2.
Web: <http://www.tadqiqot.uz/>; E-mail: info@tadqiqot.uz
Phone: (+998-94) 404-0000

GYNECOLOGY

1. **Kurbaniyazova E. Venera**
RELATIONSHIP OF POSTOPERATIVE SCAR ON THE UTERUS AND TYPE II COLLAGEN
2. **Khudoyarova R. Dildora, Shavkatova Z. Aziza**
OZONE THERAPY IN THE TREATMENT OF PREGNANT WOMEN WITH FETOPLACENTAL INSUFFICIENCY
3. **Todjjeva I. Nigina**
HYPERPLASTIC PROCESSES IN PREMENOPAUSAL AGE WOMEN

ANESTHESIOLOGY AND REANIMATION

4. **Matlubov M. Mansur, Nematulloev K. Tukhtasin**
EVALUATION OF THE EXTERNAL RESPIRATORY FUNCTION IN PATIENTS WITH VARIOUS DEGREES OF OBESITY IN THE PRE-OPERATIVE PERIOD
5. **Pardaev K. Shukur, Sharipov L. Isroil, Kasparova A. Gayana**
USE OF COMBINED SPINAL-EPIDURAL ANESTHESIA IN SIMULTANEOUS GYNECOLOGICAL OPERATIONS
6. **Sharipov L. Isroil, Pardaev K. Shukur**
ALTERNATIVE OPTION OF PREMEDICATION IN GYNECOLOGICAL PATIENTS DURING PERIMENOPAUSE (LITERATURE REVIEW)

SURGERY

7. **Zayniyev F. Alisher, Kurbaniyazov B. Zafar, Babajanov S. Axmadjon, Tukhtayev K. Jamshid**
TECHNICAL ASPECTS OF STRUMECTOMY IN TOXIC GOITER
8. **Sherbekov A. Ulugbek, Khadarova O. Laylo, Abduraxmanov Sh. Diyor**
INTEGRATED SURGICAL APPROACH TO PATIENTS WITH VENTAL HERNIATION AND OBESITY
9. **Kurbaniyazov B. Zafar, Nazarov N. Zokir, Sulaymonov U. Salim**
OPTIMIZATION OF TACTICAL AND TECHNICAL ASPECTS OF SURGICAL TREATMENT OF ELDERLY AND SENIOR PATIENTS WITH COMPLICATED FORMS OF CHOLELITHIASIS
10. **Gulamov M. Olimjon, Mukhamedov Z. Batir, Tashkenbayev R. Firdavs, Dusiyarov M. Muhammad, Makhmudov B. Saydinjon**
STUDYING THE REASONS FOR THE FORMATION OF SKIN-PROSTHETIC FISTULAS AFTER HERNIOPLASTY OF THE ABDOMINAL WALL
11. **Ahmedov K. Gayrat, Gulamov M. Olimjon, Makhsudov T. Maksud, Saydullaev Ya. Zayniddin, Khudaynazarov R. Utkir**
THE ROLE OF ENDOSCOPIC METHODS IN THE COMPLEX TREATMENT OF GERD COMPLICATIONS
12. **Babajanov S. Akhmadjon, Makhmudov B. Saidinzhon, Safarova B. Khafiza**
CRITERIA FOR CHOOSING A PLASTY METHOD IN PATIENTS WITH POSTOPERATIVE VENTAL HERNIAS
13. **Khayitov M. Laziz, Khakimov A. Erkin, Karabaev K. Khudoiberdi, Abrorov N. Shahbozjon**
RESULTS OF TREATMENT OF BURN DISEASE IN ELDERLY AND SENILE PATIENTS
14. **Khayitov M. Laziz, Khakimov A. Erkin, Karabaev K. Khudoiberdi, Abrorov N. Shahbozjon**

41. **Babadjanov D. Bakhtiyar, Matmurotov J. Kuvondik, Sattarov S. Inayat, Ruzmetov A. Bakhtiyar, ATAJONOV Sh. Tulkinbek**
COMBINED ENDOVASCULAR INTERVENTIONS FOR LESIONS OF THE PERIPHERAL ARTERIES OF THE LOWER EXTREMITIES ON THE BACKGROUND OF DIABETES MELLITUS
42. **Khalimov A. M. Khanifa, Matmurotov J. Rustambek, Umirova M. Surayyo**
EVALUATION OF THE DYNAMICS OF DIABETIC POLYNEUROPATHY IN PATIENTS AFTER COVID-19

PEDIATRIC SURGERY

43. **Ulugmuratov A. Azim, Mavlyanov Sh. Farxod, Mavlyanov X. Shavkat, Ulugmuratov A. Firdavs**
STATUS OF MINIMALLY INVASIVE INTERVENTIONS IN CHILDREN WITH INVAGINATION OF THE FINE INTESTINE (REVIEW OF LITERATURE)
44. **Khamraev J. Abdurashid, Eminov I. Ravshanjon**
FEATURES OF CLINICAL COURSE AND TACTICS OF TREATMENT OF HEMORRHOIDS IN CHILDREN
45. **Shamsiev A. Jamshid, Atakulov J. Ostonakulovich, Yusupov A. Shukhrat, Bayzhigitov I. Nusratilla**
HIRSCHSPRUNG'S DISEASE IN CHILDREN AND FEATURES REHABILITATION AFTER SURGERY

REHABILITATION AND SPORTS MEDICINE

46. **Rizaev A. Jasur, Boymurodov A. Shukhrat, Abdurakhmonov R. Farkhod.**
REABILITATION OF THE COMPLICATIONS OF THE COMBINED SOFT TISSUE INJURIES IN THE MAXILLOFACIAL REGION
47. **Ravshanova Z. Maftuna, Axmedov A. Ibrat**
REHABILITATION METHODS FOR TRAUMATIC INJURIES OF THE ANKLE JOINT IN FOOTBALL PLAYERS
48. **Egamova T. Malika, Rasulov Sh. Jamshedjon**
ORGANIZATIONAL MECHANISM FOR THE REHABILITATION OF CHILDREN WITH CEREBRAL PALSY AT HOME
49. **Egamova T. Malika, Rasulov Sh. Jamshedjon**
PHYSICAL REHABILITATION FOR CEREBRAL PALSY HOME
50. **Xakimova Z. Sohiba, Gulyamova A. Gulshan**
USING FRACTIONAL LASER ABLATION TO IMPROVE THE CONDITION OF THE SKIN AROUND THE EYES FOR THE PURPOSE OF REJUVENATION

OTORHINOLARYNGOLOGY

51. **Esamuratov I. Aybek, Karimova A. Maqsuda**
CHARACTERISTICS OF THE DISTRIBUTION OF ALLELIC POLYMORPHISM OF PRO-INFLAMMATORY CYTOKINE GENES (TNF-A (G308A), IL2 (T330G), IL6 (C174G), IL10 (C592A)) IN PURULENT-INFLAMMATORY DISEASES OF THE MIDDLE EA.
52. **Nasretdinova T. Makhzuna, Normirova N. Nargiza, Bakhronov B. Shavkatovich, Normuradov A. Nodir**
IMPROVEMENT OF THE DIAGNOSIS OF VESTIBULAR FUNCTION IN VERTIGO
53. **Nasretdinova T. Makhzuna, Karabayeva Z. Khurramovna, Normuradov A. Nodir**
CHRONIC ALLERGIC RHINITIS AS AN OCCUPATIONAL DISEAS
54. **Abdiev M. Elbek, Nasretdinova T. Makhzuna, Normuradov A. Nodir**


БИМЕДИЦИНА ВА АМАЛИЁТ ЖУРНАЛИ

ЖУРНАЛ БИМЕДИЦИНЫ И ПРАКТИКИ | JOURNAL OF BIOMEDICINE AND PRACTICE

BABADJANOV Bakhtiyar Duschanbaevich
Doctor of Medical Sciences, professor
MATMUROTOV Kuvondik Jumaniyozovich
Doctor of Medical Sciences
SATTAROV Inayat Saparbayevich
Candidate of Medical Sciences
RUZMETOV Bakhtiyar Abdirakhimovich
Applicant
ATAJONOV Tulkinbek Shavkatovich
Candidate of Medical Sciences
Tashkent Medical Academy

COMBINED ENDOVASCULAR INTERVENTIONS FOR LESIONS OF THE PERIPHERAL ARTERIES OF THE LOWER EXTREMITIES ON THE BACKGROUND OF DIABETES MELLITUS

For citation: Babadjanov Bakhtiyar Duschanbaevich, Matmurotov Kuvondik Jumaniyozovich, Sattarov Inayat Saparbayevich, Ruzmetov Bakhtiyar Abdirakhimovich, Atajonov Tulkinbek Shavkatovich. Combined endovascular interventions for lesions of the peripheral arteries of the lower extremities on the background of diabetes mellitus. Journal of Biomedicine and Practice. 2023, vol. 8, issue 3, pp.

 <http://dx.doi.org/10.5281/zenodo.0000000>

ANNOTATION

The aim of the study assess the effectiveness of minimally invasive methods in the treatment of patients with gangrene of the lower extremities against the background of diabetes mellitus.

Materials and research methods. The results of the study and inpatient treatment of 311 patients were analyzed with purulent-necrotic complications of DFS in the department of purulent surgery and surgical complications of diabetes at the 2nd clinic of the Tashkent Medical Academy. All patients suffered from type 2 diabetes.

Research results. The performance of an adequate isolated revascularization of the peripheral arteries of the extremities and the complex of therapeutic measures carried out in 81.0% of cases led to the preservation of the support function of the limb. The catheterization of the NLA with the conduct of PIACT improved the result by 7.3% and this shows the effectiveness of the integrated use of minimally invasive treatment methods for gangrene of the lower extremities against the background of diabetes mellitus.

Conclusions. Revascularization of the lower limb arteries is a highly effective method of treatment in the rescue of the limb in patients with diabetic gangrene of the lower extremities and, in the presence of purulent-necrotic processes against the background of critical ischemia of the foot, in 81.0% of cases it will be possible to save the limb.

Keywords: diabetes, critical ischemia, prolonged intra-arterial catheter therapy, purulent-necrotic wound, gangrene.

БАБАДЖАНОВ Бахтиёр Дусчанбаевич
доктор медицинских наук, профессор
МАТМУРОТОВ Кувондик Джуманиезович
Доктор медицинских наук
САТТАРОВ Инаят Сапарбаевич
Кандидат медицинских наук
РУЗМЕТОВ Бахтиёр Абдирахимович
Соискатель
АТАЖОНОВ Тулкинбек Шавкатович
кандидат медицинских наук
Ташкентская медицинская академия

КОМБИНИРОВАННЫЕ ЭНДОВАСКУЛЯРНЫЕ ВМЕШАТЕЛЬСТВА ПРИ ПОРАЖЕНИЯХ ПЕРИФЕРИЧЕСКИХ АРТЕРИЙ НИЖНИХ КОНЕЧНОСТЕЙ НА ФОНЕ САХАРНОГО ДИАБЕТА

АННОТАЦИЯ

Целью исследования явилось оценить эффективность малоинвазивных методов лечения у пациентов с гангреной нижних конечностей на фоне сахарного диабета.

Материалы и методы исследования. Были проанализированы результаты исследования и стационарного лечения 311 пациентов с гнойно-некротическими осложнениями СДС в отделении гнойной хирургии и хирургических осложнений сахарного диабета 2-й клиники Ташкентской медицинской академии. Все пациенты страдали сахарным диабетом 2 типа.

Результаты исследования. Выполнение адекватной изолированной реваскуляризации периферических артерий конечностей и комплекс лечебных мероприятий, проведенных в 81,0% случаев, привели к сохранению опорной функции конечности. Катетеризация ПБА с проведением ДВАКТ улучшила результат на 7,3%, и это свидетельствует об эффективности комплексного применения малоинвазивных методов лечения гангрены нижних конечностей на фоне сахарного диабета.

Заключения. Реваскуляризация артерий нижних конечностей является высокоэффективным методом лечения при спасении конечности у пациентов с диабетической гангреной нижних конечностей при наличии гнойно-некротических процессов на фоне критической ишемии стопы в 81,0% случаев удастся спасти конечности.

Ключевые слова: сахарный диабет, критическая ишемия, длительная внутриартериальная катетерная терапия, гнойно-некротическая рана, гангрена.

BABADJANOV Baxtiyor Duschanojevich
Tibbiyot fanlari doktori, professor
MATMURTOV Quvondik Jumaniyevovich
Tibbiyot fanlari doktori
SATTAROV Inayat Saparbajevich
Tibbiyot fanlari nomzodi
RO'ZMETOV Baxtiyor Abdiraximovich
Ilmiy izlanuvchi
ATAJONOV To'likinbek Shavkatovich
tibbiyot fanlari nomzodi
Toshkent tibbiyot akademiyasi

QANDLI DIABET FONIDA OYOQ PERIFERIK ARTERIYALARI SHIKASTLANISHIDA KOMBINIRLANGAN ENDOVASKULYAR MUOLAJALAR

ANNOTATSIYA

Tadqiqotning maqsadi – qandli diabet fonida bemorlarda oyoqlar gangrenasini davolashda kichik invaziv davolash usullarini samaradorligini baholash.

Materiallar va tadqiqot usullari. Toshkent tibbiyot akademiyasining 2-klinikasi qandli diabetning yiringli jarrohlik va jarrohlik asoratlari bo'limida DPSning yiringli-nekrotik asoratlari bo'lgan 311 bemorni o'rganish va statsionar davolash natijalari tahlil qilindi. Barcha bemorlarda 2-toifa diabet kasalligi bo'lgan.

Tadqiqot natijalari. Periferik arteriyalarini etarli darajada to'liq revaskulyarizatsiya qilish 81,0% bemorlarda amalga oshirish orqali oyoq-qo'llarning tayanch funksiyasini saqlab qolishga olib keldi. Yuza son arteriyasi katetrizatsiya qilish orqali uzoq mudatli arteriya ichi katetr terapiyasi davolash samaradorligini 7,3% yaxshiladi, bu o'z navbatida qandli diabet fonida kechuvchi oyoqlar gangrenasini kichik invaziv davolash usullarini samaradorligini ko'rsatib berdi.

Xulosa. Oyoq arteriyalarini revaskulyarizatsiya qilish oyoqlarda diabetik gangrenasi bo'lgan bemorlarda oyoqlarni saqlab qolish uchun juda samarali davolash usuli hisoblanadi, agar oyoqning kritik ishemiyasi fonida yiringli-nekrotik jarayonlar mavjud bo'lsa, 81,0% hollarda oyoq-qo'llarni saqlab qolish mumkin bo'ladi

Kalit so'zlar: qandli diabet, kritik ishemiya, uzoq muddatli arteria ichi kateter terapiyasi, yiringli-nekrotik yara, gangrena.

Introduction. Diabetic foot syndrome (DFS) is defined as an infection, an ulcer and/or destruction of deep tissues associated with neurological disorders and / or a decrease in the main blood flow in the arteries of the lower extremities of varying severity. Despite the new methods of diagnosing and treating diabetic gangrene, the frequency of limb amputations on the background of diabetes mellitus remains high [1,11].

Currently, a number of classifications of DFS have been proposed, based on ideas about the main pathogenetic mechanisms for the development of this diabetic complication, which takes into account the severity of damage to the peripheral nervous system, the peripheral arterial bed, the size of the wound defect and the severity of the infection process [2, 5].

Diabetic gangrene of the lower extremity is a serious complication of diabetic foot syndrome on the background of diabetes mellitus. The severity of this complication is determined not only by the mental trauma caused by the understanding of leg loss and disability, but also by the real danger of the death of the patient. Mortality after limb amputation is currently 20–33% [1, 3, 5]. Amputations performed below the knee joint are accompanied by reamputations in almost 40% of patients. Complications and defects of the stump in one form or another occur in 30–35% of operated patients [2, 7, 8].

The lesion of the peripheral arterial bed in patients with diabetes is most closely associated with bilateral amputation [4, 6]. Literature data showed that large amputations range from 48.9 to 60%, while according to cohort studies this number is 24% [5, 12].

Historically, the gold standard for the treatment of critical lower limb ischemia (CLLI) is surgical revascularization (endovascular treatment), but this method can only be used in patients with a good distal recipient vessel without severe concomitant pathology. The prospects of balloon angioplasty are determined by the following factors: the achievement of adequate results at lower costs, a low rate of complications, the possibility of repeated interventions and insignificant mortality. All this opens up great opportunities in the application of this method in the treatment of CLLI [8, 13].

Despite the long history of amputation, a large number of scientific studies, the treatment of patients with gangrene of the limb on the background of diabetes is an unsolved extremely urgent, not only medical, but also a social problem [9, 10].

In this regard, the purpose of this study was to assess the effectiveness of minimally invasive methods in the treatment of patients with gangrene of the lower extremities against the background of diabetes mellitus.

Material and methods. The results of the study and inpatient treatment of 311 patients for 2018-2022 were analyzed with purulent-necrotic complications of DFS in the department of purulent surgery and surgical complications of diabetes at the 2nd clinic of the Tashkent Medical Academy. All patients suffered from type 2 diabetes. In 63% of cases (203) patients for the correction of blood sugar received insulin.

The average duration of diabetes was 14.7±5.2 years. The age of patients ranged from 47 to 81 years (on average, 62.3±6.8 years). Among male patients, there were 217 (69.7%) and 94 (30.3%) women. The neuroischemic form of diabetic foot syndrome was diagnosed in 262 (84.2%) patients, ischemic form - in 49 (15.8%).

The main instrumental method of assessing the state of macrocirculation was duplex scanning of the lower extremities, performed on the Acuson-128 XP/10 ultrasonic duplex system (Acuson, USA) by a standard technique using a linear sensor with a frequency of 7-15 MHz and multispiral computed tomography (MSCT) of the lower limb arteries. After checking renal activity and normalizing renal tests (urea, creatinine), all patients underwent MSCT, which determined the level of stenosis and occlusion of peripheral arteries, the degree of artery narrowing, the extent of the lesion and the exact location of atherosclerotic plaques.

After the establishment of the affected segment (occlusion and/or stenosis) of the segment, transluminal balloon angioplasty (TLBAP) of the lower limb arteries was performed in all patients. Balloon angioplasty was carried out strictly according to the angiosomal structure of the foot and lower leg, and these patients were conditionally divided into 2 groups. In the first group, 252 (81%) patients received only BAP. Of the 323 patients after balloon angioplasty, 59 (19%) patients of group 2, in connection with severe purulent-necrotic process of the foot and critical ischemia, prolonged intra-arterial catheter therapy (PIACT) was done with catheterization of the external iliac artery on the affected side. The duration of PIACT was from 3 to 5 days with continuous administration of drugs. After improving blood circulation, small surgical interventions were performed on the foot.

Results and discussion. When analyzing the affected segments of the peripheral arterial bed, patients often had a lesion of two arteries of the lower leg - anterior and posterior tibial (ATA and PTA) - 22.2%.

Table 1.

Analysis of the results of treatment in patients performed TLBAP (n=252)

№	Lesion segment	Number of patients	Amputation of fingers	Necro-ectomy	Amputation by Sharpe	Amputati on of the leg	Hip amputati on	Mortali ty
1.	External iliac artery	3 (1,2)	1 (33,3)	1 (33,3)	-	-	-	-
2.	superficial femoral artery	52 (20,6)	27 (52,0)	16 (30,7)	7 (13,4)	8 (15,3)	4 (7,7)	3 (5,7)
3.	popliteal artery	31 (12,3)	8 (25,8)	15 (48,4)	4 (13,0)	1 (3,2)	1 (3,2)	1 (3,2)
4.	posterior tibial artery	25 (9,9)	6 (24)	11 (44,0)	-	4 (16,0)	1 (4,0)	4 (16,0)
5.	anterior tibial artery	31 (12,3)	11 (35,4)	14 (45,1)	6 (19,3)	3 (9,6)	-	2 (6,4)
6.	fibular artery	4 (1,6)	2 (50,0)	-	-	-	-	-
7.	anterior and posterior tibial arteries	62 (24,6)	31 (50,0)	17 (27,4)	9 (14,5)	5 (8,0)	2 (3,2)	3 (1,6)
8.	Two different segments	44 (17,4)	7 (16,0)	11 (25,0)	4 (9,1)	3 (8,0)	1 (1,6)	2 (3,2)

Total	252 (100)	93 (36,9)	85 (33,7)	30 (12)	24 (9,5)	9 (3,5)	15 (6,0)
-------	-----------	-----------	-----------	---------	----------	---------	----------

An isolated lesion of the superficial femoral artery (SFA) was observed in 50 (20.6%) patients and, together with isolated occlusion of the ATP, was distinguished by a malignant course. In these patients, high limb amputations were often performed (half of all amputations) (Table 1).

With a lesion of the popliteal artery (PA) after balloon angioplasty, staged necrotomy was most often performed (48.4%). This indicates the great role of the popliteal arterial network in compensating for the circulation of the foot (“rete genu”).

In the long term (72 months) after performing balloon angioplasty of the lower limb arteries, 15 (6.0%) cases were fatal. Half (8) of the patients had a fatal outcome from acute myocardial infarction and coronary syndrome (AMI and ACS), in 4 (33.3%) cases there was an acute cerebrovascular accident (ACVA), one patient died from uremic coma and 2 (13.3%) the cause of death has not been established.

59 (18.9%) patients with severe purulent-necrotic lesion and critical ischemia of the lower limb the next day or two days after the TLBAP, a catheter (F5) was installed in the femoral artery (in 36 patients – 61.0%) and in the popliteal artery (PA) (in 23 patients – 39.0%) on the affected side for intensive intraarterial drug administration using a dosimeter. This procedure lasted from 3 to 5 days. It should be noted that in the patients who received PIACT, in most cases, isolated PAB lesion was observed (33.9%) and two lower leg arteries - 23.6% (PBBA and ASFA) (Table 2). Staged necrotomies (32.2%) were performed in the most frequent patients who received PIACT.

These data in turn shows that, against the background of PIACT with the introduction of antibiotics, angioprotectors and anticoagulants, can lead to rapid relief of purulent-inflammatory process and improve local blood circulation, thereby accelerating the appearance of the demarcation line in the lesion. Minor surgeries on the foot are often performed in patients with lesions of the arteries of the lower leg (78.5%). With the defeat of two or more arterial segments, these surgeries were performed in all cases (Table 2).

As can be seen in Table 2 patients who received PIACT managed to maintain the support function of the limbs in 83% of cases, only 5 (8.4%) patients had to perform amputation of the limb due to the progression of the purulent-necrotic process. Amputation above the knee of the hip in one patient due to total occlusion of the SFA.

Amputation at the level of the leg was performed in 4 (6.7%) cases. Fatal outcome was observed in 2 patients (3.3%). One patient died after hip amputation, in the second patient with a total occlusion of all the arteries of the lower leg, died of acute myocardial infarction.

Table 2.

Analysis of the results of treatment in patients undergoing PIACT after TLBAP (n=62)

№	Lesion segment	Number of patients	Amputation of fingers	Necrotomy	Amputation by Sharpe	Leg’s amputation	Hip amputation	Mortality
1.	superficial femoral artery	20 (33,9)	3 (14,2)	6 (28,5)	7 (33,3)	2 (9,5)	1 (4,7)	1 (4,7)
2.	popliteal artery	4 (6,7)	2 (50,0)	1 (25,0)	-	-	-	-
3.	posterior tibial artery	3 (5,0)	1 (33,3)	1 (33,3)	-	-	-	-
4.	anterior tibial artery	11 (18,6)	4 (36,3)	2 (18,1)	3 (27,2)	-	-	-
5.	anterior and posterior tibial arteries	15 (25,4)	6 (40,0)	5 (33,3)	4 (26,6)	2 (13,3)	-	1 (6,7)
6.	Two different segments	6 (10,1)	1 (16,7)	4 (66,7)	1 (16,7)	-	-	-

Total	59 (100)	17 (28,8)	19 (32,2)	15 (25,4)	4 (6,7)	1 (1,7)	2 (3,3)
-------	----------	-----------	-----------	-----------	---------	---------	---------

Thus, an analysis of the dependence of the risk of amputations on the nature and localization of purulent-necrotic lesions showed that with isolated balloon angioplasty in patients with diabetic gangrene of lower extremities (DGLE) the number of amputations (above and below the knee joint) is 13%.

The most aggressive course of purulent-necrotic lesions of the feet was observed in patients with occlusive-stenotic lesions of PTA and SFA. A segmental or total lesion of the PTA led to limb amputations in 20% of cases and in 4 (16%) deaths were observed.

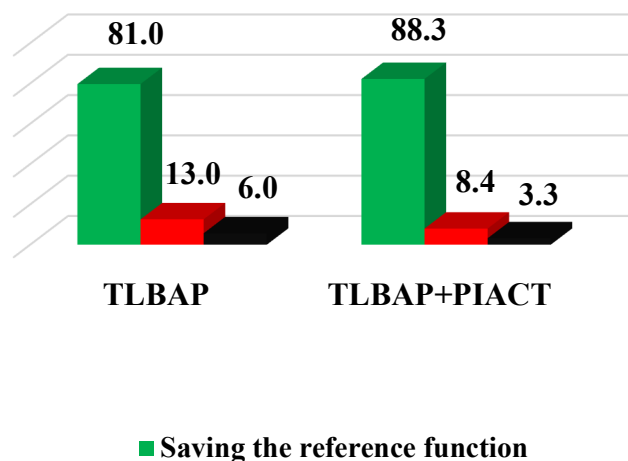


Fig.1. Comparative analysis of the results of treatment of patients.

The performance of an adequate isolated revascularization of the peripheral arteries of the extremities and the complex of therapeutic measures carried out in 81.0% of cases led to the preservation of the support function of the limb. The catheterization of the SFA with the conduct of PIACT improved the result by 7.3% and this shows the effectiveness of the integrated use of minimally invasive treatment methods for gangrene of the lower extremities against the background of diabetes mellitus.

Discussion. A comparative analysis of the results of patients who received intra-arterial catheter therapy showed that these patients most often from minor surgeries on the foot were performed stepwise necrotomy (32.2%), due to the appearance of a demarcation line in the lesion for a short time and a sharp decrease in purulent inflammatory process. Despite the conducted medical procedures, amputation of the limb was performed in 5 (8.4%) cases.

Thus, minimally invasive endovascular interventions are most effective in treating diabetic gangrene of the lower extremities. Conducting intra-arterial catheter therapy with the administration of drugs after balloon angioplasty with improved blood circulation in patients with foot purulent-necrotic lesions against the background of critical ischemia increases the chances of preserving the musculoskeletal function of the lower extremities to 88.3%.

Findings:

1. Revascularization of the lower limb arteries is a highly effective method of treatment in the rescue of the limb in patients with diabetic gangrene of the lower extremities and, in the presence of purulent-necrotic processes against the background of critical ischemia of the foot, in 81.0% of cases it will be possible to save the limb.

2. After the restoration of the blood flow of the peripheral arterial bed of the lower extremities, the introduction of drugs using intra-arterial catheters increases the chances of maintaining the support function of the limb to 88.3% and reduces mortality by 3.3%.

3. Conducting comprehensive minimally invasive treatment methods, allowing us to achieve the expected result even in patients with a critical situation and thereby improve their quality of life.

REFERENCES / СНОСКИ / ИҚТИБОСЛАР:

1. Abyshov N.S., Zakirjayev E.D. The immediate results of “large” amputations in patients with occlusive diseases of lower limb arteries // Surgery. Journal them. N.I. Pirogov. –2015.– №11. - P.15-19.
2. Gaibov A.D., Gaibov A.D., Kamolov A.N. Amputations of the lower limbs during their chronic critical ischemia // Cardiology and cardiovascular surgery. – 2019. – №2. - C.40-46.
3. Zoloev G.K. Obliterating diseases of the arteries. Surgical treatment and rehabilitation of patients with loss of limb // M.: Medicine. – 2018. – 432 p.
4. Pokrovsky A.V., Zotikov A.E. Prospects and reality in the treatment of atherosclerotic lesions of the aorta // M.: Meditsina. – 2018.-192 p.
5. Saveliev B.C., Koshkin B.C., Karalkin A.B. Pathogenesis and conservative treatment of severe stages of atherosclerosis obliterans of lower limb arteries // M.: MIA. –2020. – 214 p.
6. Biamino G. et al. Critical limb ischemia: new techniques for complex interventions // HMP Communication. –2021. –P. 72.
7. Castelli G. et al. Procalcitonin and C-reactive protein during systemic inflammatory response syndrome, sepsis and organ dysfunction // Critical Care.–2017.–Vol. 8.–P. 234-242.
8. Dormandy J.A. et al. Major amputations // Semin Vasc. Surg.–2009–Vol. 73.–P. 321.
9. Eskelinen E. et al. Major amputation incidence decreases both in non-diabetic and in diabetic patients in Helsinki // Scandinavian Journal of Surgery.–2020.–Vol.95.– P. 185-189.
10. Johannesson A. et al. Incidence of lower-limb amputation in the diabetic and nondiabetic general population // Diabetes Care.–2021.–Vol.32.– №2.– P.275–280.
11. Snow D.E., Everett J., Mayer G. et al. The presence of biofilm structures in atherosclerotic plaques of arteries from legs amputated as a complication of diabetic foot ulcers // J. Wound Care. – 2016. – Vol. 25, №2. - S16-22.
12. TASC Working group. Management of peripheral arterial disease (PAD): TransAtlantic Inter-Society Consensus (TASC). Management Eur // J. Vasc. Endovasc. Surg. – 2007– Vol. 19, Suppl 1.
13. Zhang Z., Lv L. Effect of local insulin injection on wound vascularization in patients with diabetic foot ulcer // Exp. Ther. Med. – 2018. – Vol. 11, №2. – P.397-402.