

NOVATEUR PUBLICATION


# JournalNX

A Multidisciplinary Peer Reviewed Journal

**VOLUME 9, ISSUE 10**

ISSN: 2581-4230

SJIF 2023: 8.075



www.journalnx.com

OCTOBER, 2023

**EMAIL**

editor@journalnx.com

**LOCATION**

466, Sadashiv Peth, Pune, M.S.  
India



## **VOL. 9 NO. 10 (2023): JOURNALNX**

- 1. THE IMPORTANCE OF TRAVEL AND TOURISM IN FORMING A HEALTHY LIFESTYLE IN HIGH SCHOOL STUDENTS**  
Umarova Zulxumor Urinbaevna, Umarov Abdusamat Abdumalikovich  
1-7
- 2. PEDAGOGICAL MECHANISMS OF PHYSICAL EDUCATION EXERCISES IN INCREASING THE SOCIAL ACTIVITY OF SCHOOL GUESTS**  
Umarova Zulxumor Urinbaevna  
8-16
- 3. A CASE OF OBLITERATING THROMBANGIITIS IN A 6-YEAR-OLD GIRL**  
Iskanova G. Kh., Karimjanov I. A., Dinmukhamedova D. R.  
17-19
- 4. THE ARTISTIC WORLD OF LERMONTOV**  
Ayupov T. R.  
20-26
- 5. METHODS FOR FORMING A HEALTHY LIFESTYLE AT SCHOOL PHYSICAL EDUCATION LESSONS**  
Hamrakulov Tulkin Takhirovich  
27-31
- 6. PEDAGOGICAL CONDITIONS FOR FORMATION OF SPORTS SKILLS**  
Hamrakulov Tulkin Takhirovich  
32-38
- 7. MODERN METHODS AND TECHNOLOGIES OF DISTANCE ASSESSMENT IN UNIVERSITIES**  
Kunnazarov Aliy Bisenbaevich  
39-43
- 8. ADDRESSING WOMEN'S CRIMINAL BEHAVIOR IN UTTARAKHAND: CHALLENGES AND SOLUTIONS**  
Dr. Asha Rana, Arushi  
44-55
- 9. HERMENEUTICS, MATHEMATICS AND ITS HISTORY**  
B. N. Alimov  
56-61

## A CASE OF OBLITERATING THROMBANGIITIS IN A 6-YEAR-OLD GIRL

Iskanova G. Kh.,  
Karimjanov I. A.,  
Dinmukhamedova D. R.  
Tashkent Medical Academy

### Abstarct

Systemic vasculitis (SV) is one of the most severe forms of chronic inflammatory human diseases [1,2,3,4,7,8]. This is a group of diseases, the basis of which is a generalized lesion of the vascular wall of immune genesis with the development of inflammation and necrosis, leading to a violation of blood flow in organs and tissues. In various vasculitis, the severity of clinical manifestations, as well as the prognosis, will depend both on the nature of the immune-inflammatory process in the vascular wall, and on the type, caliber and localization of the affected vessels, the course and severity of concomitant inflammatory changes in tissues [1,2,5,6]. The cause of the disease is unknown, although according to some sources, cigarette smoking is the main risk factor [3,5]. The mechanism of pathology development may include delayed hypersensitivity or toxic vasculitis. According to another theory, obliterating thrombangiitis may be an autoimmune disease caused by a cell-mediated reaction to human collagen types I and III, which is part of blood vessels. The disease is more common in young men with a long smoking experience, while the progression of the pathological process with an increase in ischemic disorders in the extremities and changes in the vessels of internal organs lead to early disability of patients [2,5,7,8]. To date, there is no doubt that there is a relationship between immune inflammation and the development of thrombosis, since these processes are based on many similar pathogenetic mechanisms. Thrombotic complications remain one of the most severe and life-threatening conditions that occur in patients with systemic vasculitis [2,3,4,6].

A 6-year-old child was hospitalized in the Department of Pediatric rheumatology of the multidisciplinary TMA clinic in May 2023 with a diagnosis of Systemic vasculitis, obliterating thrombangiitis, Raynaud's syndrome

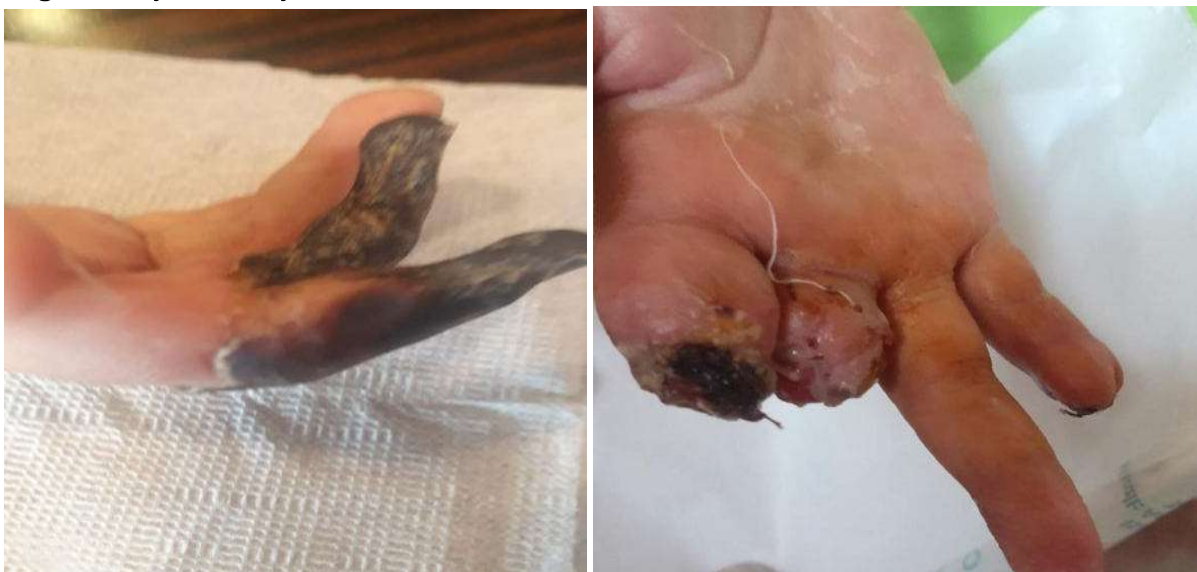

Figure 1.

We offer a full description of the medical history No. 2034/173. A 6-year-old girl was admitted with complaints of blueness and freezing of the fingers of both hands, tongue, fever, severe pain on the hands and feet (fig. 1). Ill for a month. The disease began with weakness, capriciousness and the appearance of a small red rash on the palms. No treatment was carried out. After 2 days, the body temperature increased to 38 degrees. At home, the child was treated with antipyretic drugs and antibiotics. The girl lost her appetite and lost weight. The last 7 days the condition worsened, there was chilliness, tingling and burning in the fingertips, fatigue and weakness. She was hospitalized in the Department of Pediatric Rheumatology of the multidisciplinary hospital of Andijan with a diagnosis of "Mixed connective tissue disease. Systemic vasculitis". Examined by a hematologist and oncologist. After treatment, the child's condition remained poor and the child was sent to the TMA clinic.

On examination, the patient's condition is severe, severe pains on her arms and legs are bothering. The terminal phalanges of 3 fingers of the right and 1 finger of the left hand are bluish-purple in color and cold to the touch, the remaining fingers have a pale color. A small, pink rash is detected on the flexor surfaces of the upper and lower extremities. Pulse on the arteries of the hands of weak filling. When walking, intermittent lameness is observed. The lymph nodes are not enlarged. There is vesicular respiration in the lungs. The heart tones are muted, the heart rate is 96 beats per 1 minute, the tongue is dry, dark blue and overlaid with a white-brownish coating. The smell of rot is coming out of mouth. When removing the crust, serous fluid is released, the abdomen is soft, painful on palpation. The liver and spleen are not enlarged. The chair is decorated. Urinates regularly, the urine is straw-yellow.

From anamnesis, 2 children were born from healthy parents, a girl from twins. The mother's pregnancy and childbirth proceeded normally. She was breastfed for up to 6 months. Received vaccinations on time and on schedule. She was often ill with viral infections. Living conditions are good, but the mother believes that the girl got sick after scandals in the family.

From laboratory data (only pathological parameters): hemoglobin 78, segmentad- 92, ESR-30, ASLO-550, CRP-18, fibrinogen-7.06, ALT -166 Units/L, and AST-52Ed/L are high. Procalcitonin, antineutrophil cytoplasmic antibodies ANA screen, IgG antibodies to beta 2 glycoprotein were elevated, cryoglobulins were normal. Duplex scanning of large arterial and venous vessels revealed no pathology.

Taking into account the manifestation of the disease with pronounced intoxication, fever, skin and joint syndromes, it was necessary to exclude oncohematological pathology. For this purpose, a biopsy was performed from the pathological focus, which made it possible to exclude the oncoproliferative process.

Histology: slight hyperkeratosis, sometimes detachment of the stratum corneum, granular thinned, epidermal processes smoothed, sometimes vacuole dystrophy of the cells of the basal layer. In the papillary layer, there is swelling and unfolding of collagen fibers, the walls of the vessels are thickened and fibrously altered. There is disorganization and fibrosis in the mesh layer.

Clinical diagnosis: "Systemic vasculitis, obliterating thrombangiitis, severe course, Raynaud's syndrome".

Treatment. The patient underwent pulse therapy with methylprednisolone at a dose of 500 mg No. 3, cyclophosphamide 600 mg, plasmapheresis No. 5 sessions. Cellsept (mofetil mycophenolate),

prostaglandin E analog-alprostadil, anticoagulant- xarelto, heparin, antiplatelet agent- pentoxifylline, peripheral vasodilator-amlodipine.

Hepatoprotector-karsil, nonsteroidal anti-inflammatory drug-diclofenac, antibiotics-cefepim, meropenem. Against the background of the therapy, only by day 7, the beginning of positive dynamics was observed, the temperature decreased. Necrotic phalanges of the fingers were amputated. In the future, pulse therapy with metipred and cyclophosphamide continues 1 time a month. Methotrexate 10mg 1 time in 7 days.

Thus, the following features of the course of this pathology in a child can be distinguished. In children, it occurs with nonspecific general symptoms: fever, malaise, weight loss, necrotic ulcers on the extremities, on the tongue. The diagnosis confirms the presence of antinuclear antibodies to proteinase. Methylprednisolone, methotrexate, cyclophosphamide give a good effect in treatment, and patients need lifelong therapy with glucocorticoids and immunosuppressants.

Damage to peripheral arteries leads to a classic picture of limb ischemia. As the disease develops, its effect spreads to both the arterial and venous bed without the symptoms characteristic of atherosclerosis. The course of thrombangiitis occurs against the background of ischemia of the upper and lower extremities, as well as thrombosis. These conditions can cause amputation.

## References

1. Hematological manifestations of systemic lupus erythematosus. Egamova S.S., Mirakhmedova H.T., Iskanova G.H. / Bulletin of the Tashkent Medical Academy.2023,№7.P. 172-175. URI: <http://repository.tma.uz/xmlui/handle/1/8976>
2. Tursunboev A.K., Dinmuxamedova D.R., Iskanova G.Kh. Renal complications of vasculitis in children. URI: <http://repository.tma.uz/xmlui/handle/1/8885>. Date: 2023-04-28
3. YalcindagA., Sundel R. Vasculitis in childhood. *Curr Op.n Rheumatol* 2001; 13: 422-7.
- 4.Hunder G.G., Arend W.P., Bloch D.A. et al. The American College of Rheumatology 1990 criteria for the classification of vasculitis. *Arthr Rheum* 1990; 33: 1065—1067.
- 5.Merkel P. A. Drug induced vasculitis. *Rheum Dis Clin North Am* 2001; 27: 849-62.
- 6.Nadeau S. E. Neurologic manifestations of systemic vasculitis. *Neurcl Clin* 2002; 20: 123-50.
- 7.Rostoker G. Scenlein-Henoch purpura in children and adults: Diagnosis, pathophysiology and management. *Bio Drugs* 2001; 15: 99-138.
8. Luqmani R.A., Bacon P.A., Moots R.J. et al. Birmingham vasculitis activity score (BVAS) in systemic necrotizing vasculitis. *Q J Med* 2001; 87: 671—678.