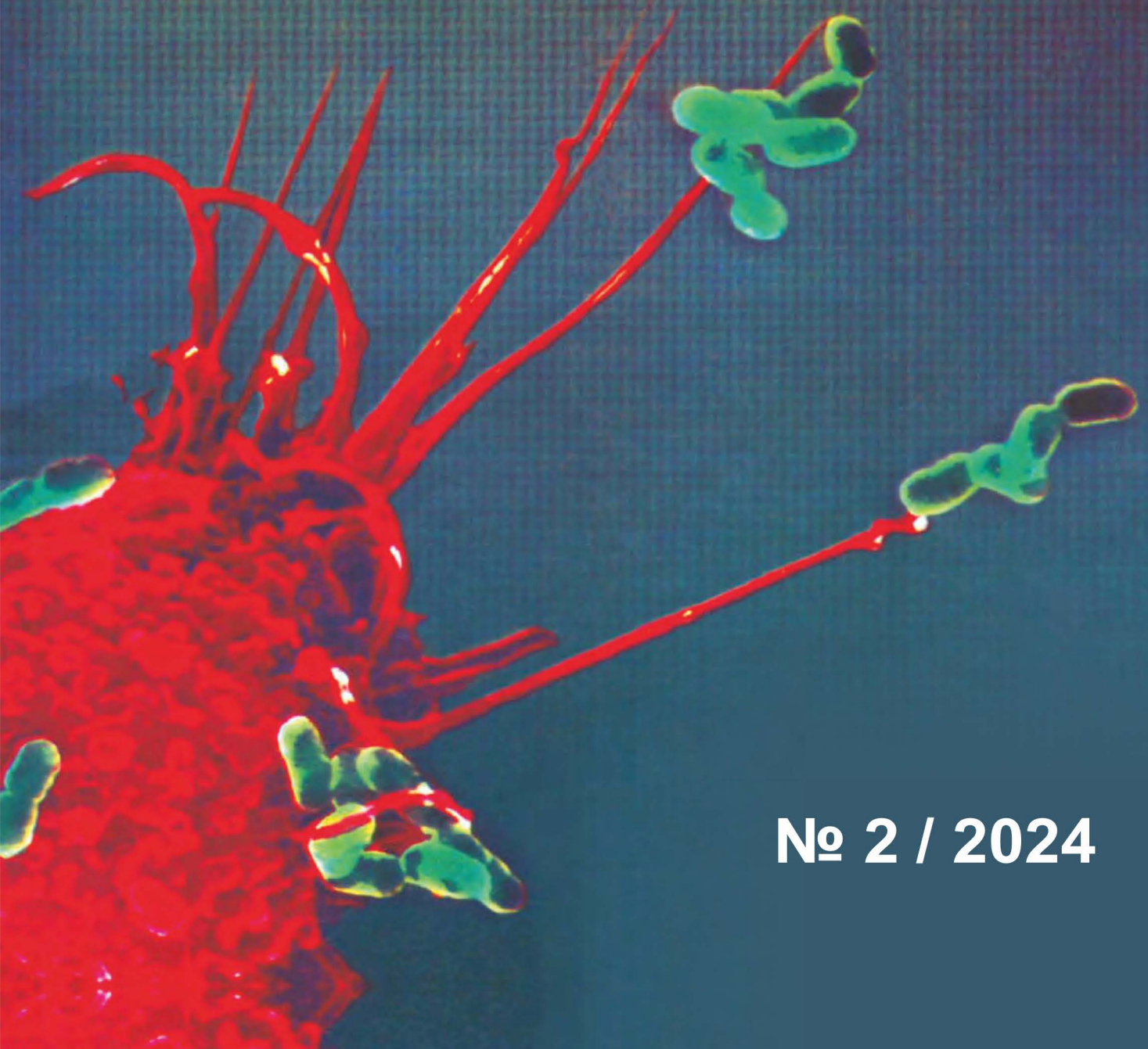


ISSN 2181-5534

ИНФЕКЦИЯ, ИММУНИТЕТ и ФАРМАКОЛОГИЯ



№ 2 / 2024

ИНФЕКЦИЯ, ИММУНИТЕТ И ФАРМАКОЛОГИЯ

Научно-практический журнал

2/2024

Журнал основан в 1999 г.

Редакционная коллегия:

Главный редактор — профессор Тулаганов А. А.

1. Атабеков Нурмат Сатиниязович – д.м.н., проф., Санитарно-эпидемиологической службы спокойствия и общественного здравоохранения РУз.
2. Ражабов Гулом Хурсанович – к.м.н., зав. лаб. института вакцин и сывороток РУз.
3. Абдихакимов Абдулла Нусратиллаевич – д.м.н., проф., директор Таш. обл. филиала научно-практ. спец. центра онкологии и радиологии РУз.
4. Аллаева Мунира Журакуловна – д.м.н., проф., зав. каф. фармакологии ТТА.
5. Аминов Салохиддин Джураевич – д.м.н., проф. зав. каф. фармакологии, физиологии ТашПМИ.
6. Богдасарова Эльмира Сергеевна – д.м.н., проф., ТашФарМИ.
7. Таджиев Ботир Мирхашимович – д.м.н., проф., директор РСНПМЦЭМИПЗ.
8. Туляганов Рустам Турсунович – д.б.н., проф., каф. фармакологии и клинической фармации ТФИ.
9. Маматкулов Ибрагим Хамидович (зам. глав. редактора), – д.м.н., проф., директор НИИХиФ РУз.
10. Сабиров Джахонгир Рузиевич – д.м.н., доцент, заместитель директора детск. нац. мед. центра по науке, образованию и международным связям.
11. Нарзуллаев Нуриддин Умарович – д.м.н., проф., БухГМИ.
12. Аминжон Каримов – д.м.н., проф., каф. органического синтеза ТашФарМИ.
13. Максудова Лайло Масхутовна – д.м.н., доцент, каф. офтальмол. центра развития проф. квалиф. мед. раб.
14. Таджиев Мирхотам Мирхашимович – д.м.н., доцент каф. неврологии, детск. неврологии, мед. генетики ТашПМИ.
15. Облокулов Абдурашид Рахимович – д.м.н., проф., зав. каф. инф. болезней и детских инф. болезней БухГМИ.
16. Мавлянов Искандар Рахимович – д.м.н., проф., консультант директора Республиканского научно-практического Центра Спортивной медицины.
17. Ибадова Гулнара Алиевна – д.м.н., проф., каф. инф., дет. инф. и паразит. заб. центра развития проф. квалиф. мед. раб.
18. Қосимов Илхомжон Асомович (зам. глав. редактора), – д.м.н., проф., каф. инф. болезней и детск. инф. заб., фтизиатрии и пульмонологии ТашПМИ.
19. Кахоров Болта Абдугафарович – к.б.н., доц., зав. каф. физиологии человека и животных Национального университета РУз.
20. Зияева Шахида Тулаевна (ответственный секретарь). – к.м.н., доц. каф. фармакология, физиология ТашПМИ.

Зарубежные члены редколлегии:

21. Кравченко Ирина Эдуардовна – д.м.н., проф., каф. едры инф. болезней ФГБОУ ВО «Казанский ГМУ» МЗ РФ.

Редакционный совет:

акад. Арипова Т.У., (Ташкент)
акад. РАН, Кукес В.Г. (Москва)
акад. Тулегенова А.У. (Астана)
акад. Раменская Г.В. (Москва)
акад. Иноятова Ф.И. (Ташкент)

проф. Гариб Ф.Ю. (Москва),
проф. Сайфутдинов Р.Г. (Казань),
проф. Мадреимов А.М. (Нукус),
проф. Нуралиев Н.А. (Бухара)
проф. Туйчиев Л.Н., (Ташкент)
проф. Облокулов А.Р. (Бухара)

СОДЕРЖАНИЕ

1. АГЗАМОВА М.Н., ЗУПАРОВ К.Ф., ТУХТАМУРОД З.З. ОКИСЛИТЕЛЬНЫЙ СТАТУС ВО ВРЕМЯ АЛЛОПЛАСТИКИ У БОЛЬНЫХ С ПОСЛЕОПЕРАЦИОННОЙ ВЕНТРАЛЬНОЙ ГРЫЖЕЙ. АГЗАМОВА.....5
2. AZIZOVA N.M., YULDASHEV N.M. ABO SISTEMASI BO'YICHA TURLI QON GURUHLARINING BIOKIMYOVIY KO'RSATKICHLARI ORASIDAGI O'ZIGA XOSLIKLAR.....11
3. АХМЕДОВА Н.Ш., ЖУМАЕВА М.Ф. ПОРАЖЕНИЯ ПОЧЕК ПРИ ХРОНИЧЕСКИХ ВИРУСНЫХ ГЕПАТИТАХ В И С (ЛИТЕРАТУРНЫЙ ОБЗОР)17
4. ASHUROVA A.SH., PULATOVA R.Z., TASHPULATOVA G.U. ERTABOLALIK DAVRIDA COVID-19 BILAN KASALLANGAN BOLALARDA KASALLIKNI KLINIK VA IMMUNOLOGIK XUSUSIYATLARINI BAHOLASH22
5. БОБОЕВ К. Т., МУСАШАЙХОВА Ш. М., МАХСУДОВ О. М., МУСАШАЙХОВ У. Х. ИЗУЧИТЬ ЧАСТОТЫ ВСТРЕЧАЕМОСТИ ДРАЙВЕРНЫХ СОМАТИЧЕСКИХ МУТАЦИИ В РАЗВИТИИ ОСТРОГО МИЕЛОИДНОГО ЛЕЙКОЗА27
6. ГАФУРОВА Н.С., ХАДЖАЕВА Д.Х., ОЧИЛОВ С.И. ДИНАМИКА ОСОБЕННОСТЕЙ ЭТИОЛОГИИ, КЛИНИЧЕСКОГО ТЕЧЕНИЯ И СТРУКТУРЫ ГНОЙНО-ВОСПАЛИТЕЛЬНЫХ ЗАБОЛЕВАНИЙ У ДЕТЕЙ31
7. ZUBTIYEV S. U. BIRTH TRAUMA IN NEWBORNS (ANALYTICAL REVIEWS) ..36
8. КАРИМОВА Г.А. ВЛИЯНИЕ ДАРМОНАЛА И СОЕДИНЕНИЙ ФИТИНА ФУНКЦИОНАЛЬНОЕ СОСТОЯНИЕ ПЕЧЕНИ ПРИ ЭКСПЕРИМЕНТАЛЬНОМ ГЕПАТИТЕ, ВЫЗВАННОМ ПАРАЦЕТАМОЛОМ46
9. KARIMOVA SH.F. KALAMUSHLARNING TURLI XIL IOD BILAN TA'MINLANISHIDA TIREOTSITLARNING TIREOTROP GORMONIGA SEZUVCHANLIGINI TAJRIBADA O'RGANISH.....52
10. МИРЗАЕВА М.А., КАРАЖАНОВА Т., ГАФУРОВА Н.С. РАСПРОСТРАНЕНИЕ ДИАРЕЙНЫХ ЗАБОЛЕВАНИЙ СРЕДИ ДЕТЕЙ В РЕСПУБЛИКЕ КАРАКАЛПАКСТАНЕ.....56
11. МИРЗАЕВА М.А., ГАФУРОВА Н.С., МАХКАМОВА Д.Э. ЭТИОЛОГИЯ ОСТРЫХ КИШЕЧНЫХ ЗАБОЛЕВАНИЙ У ДЕТЕЙ В ШКОЛЬНЫХ ВОЗРАСТАХ61
12. MIRRAKHIMOVA M.KH., NISHANBAEVA N.Y., KASIMOVA M.B. BOLALARDA O'TKIR REVMATIK ISTMA KASALLIGINI KELIB CHIQISHI VA DAVOLASH ALGORITMI65

REZYUME
БОЛАЛАРДА ЙИРИНГЛИ ЯЛЛИҒЛАНИШ КАСАЛЛИКЛАРИ
СТРУКТУРАСИ, КЛИНИК КЕЧИШИ ВА ЭТИОЛОГИЯСИНИНГ ЎЗИГА
ХОС ДИНАМИКАСИ

Гафурова Нигора Сабитовна, Хаджаева Дилбар Ҳамидовна,
 Очиллов Сардор Илҳомович

Тошкент педиатрия тиббиёт институти
[@gmail.com](mailto:sardoruktamovich@gmail.com)

2-Тошкент болалар хирургик шифонасида йирингли яллиғланиш касалликлари билан даволанаётган 0 ёшдан 15 ёшгача бўлган 112 нафар болаларнинг клиник кўринишлари, касалланиш даражаси ва тузилиши ўрганилди. Ҳозирги вақтда болалардаги йирингли яллиғланиш касалликларининг кўпчилиги хусусиятлари шу жумладан болалар организми билан келтириб чиқарувчи микроорганизмларнинг ўзаро муносабати ўзга-

риб бормоқда. Текширувлар шуни кўрсатдики йирингли яллиғланиш касалликларининг келтириб чиқарувчи қўзғатувчиларининг турлари ўзгариб бормоқда. Шунини алоҳида таъкидлаш керакки кўпчилик қўзғатувчиларнинг патогенлик омиллари уларнинг назологик маҳсулигининг йўқлиги ва шартли патоген микроорганизмларнинг патоген микроорганизмлардан кўпгина фарқлари билан белгиланади.

UDC 616-018 /616-091.8

BIRTH TRAUMA IN NEWBORNS (ANALYTICAL REVIEWS)

Zubtiyev Sardor Uktamovich

Tashkent medical academy
sardoruktamovich@gmail.com

Annotation. Birth trauma is damage to the fetus (soft tissues, bone, musculoskeletal system, internal organs, central and peripheral nervous system) by the action of adverse factors during childbirth. In some cases, birth trauma can be formed antenatally. Birth injuries of newborns during vaginal delivery occur in 3.6% of cases and during cesarean section – 1.2%. Recently, there has been an increase in the prevalence of birth injuries due to damage to the

scalp of newborns, while there has been a decrease in severe injuries leading to significant long-term consequences, disability, and death. Birth trauma most often occurs with complicated delivery and operative delivery. However, in some cases, birth trauma is a consequence of natural forces acting during the birth act. In this regard, it is impossible to exclude birth trauma in newborns even with an uncomplicated course of pregnancy, the absence of external in-

fluences on the fetus, and instrumental delivery.

Keywords: birth trauma; depressed fracture; linear fracture; “pingpong” fracture

Birth injuries of newborns during vaginal birth occur in 3.6% of cases, during cesarean section – in 1.2% of cases [1, 2]. In the structure of newborn morbidity, birth trauma accounts for 7–8.9% [3, 4]. Among the perinatal factors contributing to the development of cerebral palsy and other lesions of the nervous system in children, one of the important ones is the birth traumatic factor, which causes both mechanical damage and various disorders of cerebral hemodynamics. Perinatal lesions of the nervous system lead to disability in 35–40% of cases.

Birth trauma in a newborn can have different localizations and lead to disturbances in various body functions. The following types of birth trauma in newborns are distinguished: soft tissue injury (skin, subcutaneous tissue, muscles, birth tumor); trauma to the osteoarticular system (fractures of the clavicle, humerus and femur; traumatic epiphysiolysis of the humerus, subluxation of the CI–CII joints, damage to the skull bones, cephalohematoma, etc.); internal organs (hemorrhages in internal organs); central and peripheral nervous system: a) intracranial (epidural, subdural, subarachnoid hemorrhages); b) spinal cord (hemorrhages in the spinal cord and its membranes); c) peripheral nervous system (damage to the brachial plexus - Duchenne-Erb paresis/palsy or Dejerine-Klumpke palsy, total type of brachial plexus paresis, diaphragm paresis, damage to the facial nerve, etc.) [5–8]. The most common injury is damage to the scalp, its incidence is up to 20.4 per 1000 births. This is followed by clavicle frac-

tures with an incidence of 2.4 per 1000 births [9, 10]. Meanwhile, the incidence of more serious injuries, such as brachial plexus injury, ranges from 1 to 3.5 per 1000 live births. Intracranial hemorrhages are less common, their incidence varies from 0.1 to 1.4 per 1000 live births [9, 11, 12].

G. Ruby et al. examined birth records in the United States from 2006 to 2014. They found 982,033 cases of neonatal birth injuries and found a 23% increase in the overall incidence of newborn injuries (from 25.3 to 31.1 per 1000 births), with a 33% increase in the number of newborns. scalp injuries and a 16% decrease in the number of other types of injuries, including brachial plexus injuries - by 20%, and clavicle fractures - by 11%. Most likely, the decrease in the incidence of severe birth injuries is associated with an increase in the frequency of cesarean sections [13].

Currently, there is a fairly wide range of risk factors for birth trauma in the newborn. These factors can be classified into fetal, associated with pregnancy and childbirth, maternal and iatrogenic. Soft tissue injuries resulting from birth trauma include petechiae, ecchymoses, lacerations and, in rare cases, subcutaneous fat necrosis [20]. A number of common soft tissue injuries have a favorable prognosis. These include hemorrhages in the skin and mucous membranes, abrasions, and a birth tumor.

Birth tumor (caput succedaneum) is swelling with hemorrhages of the soft tissues of the head that develops during childbirth. Self-resolution occurs within the first few days after birth. Due to the almost 100% frequency and in the vast majority of cases the absence of serious complications, many authors do not classify this condition as a birth injury.

Rare complications include bruising of the skin over the tumor with necrosis leading to scarring and alopecia, sometimes leading to local infection [21].

Subconjunctival hemorrhage is a benign condition in newborns and resolves without intervention [22]. More serious damage to the eye can occur when using obstetric forceps (corneal abrasion, vitreous hemorrhage) [23, 24].

Cephalohematoma occurs in 2.5% of all births. The occurrence of this injury is associated with difficult passage of the head through the birth canal, as well as the application of obstetric forceps [25]. Spontaneous resolution usually occurs within 2 weeks to 3 months without intervention. However, in rare cases, complications such as calcification, skull deformation, infection and osteomyelitis may develop [21].

Subgaleal hemorrhage occurs when tension pulls the scalp away from the fixed bony vault of the skull, which leads to rupture of blood vessels. It is estimated that this occurs in 4 out of 10 thousand spontaneous vaginal births and in 59 out of 10 thousand births using vacuum extraction of the fetus [26]. According to P.C. Ng et al., the incidence of subaponeurotic hemorrhages is 6.4 cases per 1000 births during childbirth through vacuum extraction of the fetus, compared with the overall incidence of 0.8 cases per 1000 births [27]. In rare cases, with significant blood loss, subgaleal hemorrhage can lead to hemorrhagic shock, which is accompanied by a 14% risk of death [28].

The incidence of symptomatic intracranial hemorrhage in full-term infants is approximately 5.1–5.9 per 10 thousand live births [29]. Characteristic risk factors include forceps placement, vacuum extraction, precipitate labor, prolonged

second stage of labor, and macrosomia [30]. The incidence of intracranial hemorrhage associated with childbirth has been. In recent years, there has been a downward trend due to a reduction in the frequency of use of obstetric forceps and the use of softer and more flexible vacuum extractors [19]. The most common symptoms of intracranial hemorrhage are apnea and seizures, which can appear within 48 hours after birth [31].

Epidural hemorrhage in newborns occurs as a result of damage to the middle meningeal artery, is rare and usually accompanies linear skull fractures in the parietotemporal region after surgical delivery. The rarity of epidural hemorrhage in newborns is associated with the absence of a groove for the middle meningeal artery in the bones of the skull, which makes the artery less susceptible to injury [32].

Subdural hemorrhage is the most common type of intracranial hemorrhage in newborns. Subdural hemorrhages sometimes become an incidental finding in newborns without clinical symptoms. Recent published data indicate that clinically significant subdural hemorrhages occur in 2.9 cases per 10 thousand live births during spontaneous vaginal birth, in 8–10 cases per 10 thousand live births during childbirth using a vacuum extractor and obstetric forceps [29]. Intracranial hemorrhage in newborns was initially thought to be rare and associated with significant morbidity and mortality. However, recent studies have shown that in the absence of clinical manifestations in the neonatal period, subdural hemorrhage is diagnosed by magnetic resonance imaging (MRI) in 26–46% of cases [33–35]. Unlike subdural hematoma associated with traumatic brain injury, which is often localized along the in-

terhemispheric fissure or convexes of the brain [36], subdural hematoma in newborns without neurological symptoms is found predominantly in the posterior cranial fossa or over the occipital lobes near tentorium cerebellum [37].

Subarachnoid hemorrhage is the second most common type of intracranial hemorrhage in newborns, occurs with an incidence of 1.3 per 10 thousand vaginal births and usually results from rupture of the bridging veins in the subarachnoid space. Intracerebral and intracerebellar hemorrhages are less common and occur as a result of occipital osteodiastasis (bone separation) [38].

Damage to the facial nerve is the most common injury to cranial nerves due to birth injuries. This occurs in 3 cases per 10 thousand live births and is usually the result of pressure on the facial nerve from forceps or the protruding maternal sacral promontory during descent of the head. Clinical manifestations include decreased or loss of mobility on the affected side of the face. Although the application of forceps is directly related to this injury, damage to the facial nerve can occur without any visible traumatic impact. The prognosis is favorable, with spontaneous resolution usually observed within the first few weeks of life [39].

Brachial plexus injuries. They occur with a frequency of 1 to 3.5 cases per 1000 live births and are the result of stretching of the cervical nerve roots during childbirth. These injuries are typically unilateral, and risk factors include macrosomia, shoulder dystocia, breech presentation, multiple births, and instrumental delivery [40].

Damage to the V and VI cervical nerve roots leads to Duchenne-Erb palsy. Damage to the 8th cervical and 1st

thoracic nerves leads to Klumpke's palsy. Damage to all nerve roots can lead to complete paralysis of the arm. Damage to the phrenic nerve may be a concomitant symptom of brachial palsy. Clinical manifestations include tachypnea with asymmetrical chest motion and decreased breathing on the affected side.

Rare, severe cases of brachial plexus injury lead to persistent muscle weakness on the affected side [41].

Spinal cord injuries in the neonatal period are rare and usually result from excessive traction or twisting of the spine during fetal extraction. Clinical manifestations depend on the type and location of the lesion. Higher lesions (cervical/upper thoracic) are associated with high mortality, and lower lesions (lower thoracic, lumbosacral) can lead to bladder and bowel dysfunction. Diagnosis is made using ultrasound (US) or MRI of the spinal cord [42].

Risk factors for birth trauma. Factors related to fruit and pregnancy/childbirth [14–17]

- Fetal macrosomia
- Macrocephaly
- Congenital anomalies of the fetus
- Low birth weight
- Extreme prematurity
- Low water
- Incorrect position and presentation of the fetus, including breech
- Extension head inserts
- Asynclitic insertion of the fetal head
- Multiple pregnancy
- Fetal shoulder dystocia
- Rapid or, on the contrary, prolonged labor
- Maternal factors [14, 18]
- Obesity

- Diabetes mellitus, including gestational
- Narrow pelvis
- Parity (first birth)
- Age of the woman giving birth (>35 years)
- Large uterine fibroids
- Maternal abdominal trauma
- Iatrogenic factors [19]
- Delivery using a vacuum extractor, obstetric forceps

Skeletal injuries. Most fractures resulting from birth trauma are associated with difficult extraction or abnormal presentation of the fetus. Clavicle fractures are the most common bone fracture during childbirth and can occur in up to 15 per 1000 live births. The clinical picture is characterized by crepitus at the fracture site, pain and decreased mobility of the affected arm with an asymmetrical Moro reflex. Clavicle fractures have a good prognosis, with spontaneous healing occurring in most infants. The humerus is most often broken at the time of birth, which can be combined with damage to the brachial plexus. The clinical picture may be similar to a clavicle fracture with an asymmetrical Moro reflex and inability to move the affected arm. Rare conditions may include separation of the distal humeral epiphysis due to birth trauma, requiring skilled orthopedic intervention [43]. Fractures of the femur and ribs can also occur during childbirth, but this type of injury is rare [44].

Skull fracture. The prevalence of spontaneous intrauterine skull fractures ranges from 1 in 4000 to 1 in 10 thousand births [45]. In a retrospective analysis conducted by O. Dupuis et al. in France, spontaneous and instrumental obstetric depressed skull fractures were compared over a 10-year period. 1,994,250 births

were analyzed, 75 cases of depressed skull fractures were found, which is 1 case in every 26 thousand births. Of the 68 cases of depressed fractures, 18 occurred during spontaneous vaginal birth and delivery by cesarean section without the use of a vacuum extractor and obstetric forceps, i.e. spontaneous depressed fractures. The remaining 50 out of 68 were births in which obstetric forceps and a vacuum extractor were used [18, 46].

Among depressed skull fractures, congenital and acquired ones are distinguished [47].

Congenital (spontaneous, not associated with instrumental delivery): occur during pregnancy (pressure from uterine fibroids, fetal arms and part of the twin's body) and childbirth, during which the forces of uterine contraction must overcome the resistance forces of the birth canal [48]. This is accompanied by compression of the fetal head by the mother's bony pelvis (from the V lumbar vertebra, ischial processes, sacral promontory and pubic symphysis, asymmetrical pelvis), which leads to deformation of the skull [48], indentation of the parietal or frontal bones of the skull, which can cause a violation of the integrity of the cerebral cortex brain [45, 49, 50]. Other risk factors include external maternal abdominal trauma, Ehlers–Danlos syndrome, and congenital osteogenesis disorders [51]. Acquired (iatrogenic) most often develop during delivery with obstetric forceps or vacuum extraction of the fetus [47].

Depending on the severity of the injuries, depression of the skull bones is classified into two main types: depression without fracture and with fracture of the skull bones [49].

Other authors describe 3 types of

skull fractures in newborns: linear, depressed, or “celluloid ball type,” and occipital osteodiastasis [45]. A celluloid ball fracture is a type of depressed skull fracture that occurs in newborns due to the relatively soft and pliable nature of the skull bones [52]. As a result of immature ossification, increased pressure on the neonate's skull can cause the bones of the calvarium to cave inward, causing a depression on radiographs to resemble a dent in the surface of a ping-pong ball [47]. Most often the parietal and frontal bones are affected, and very rarely the occipital region [45].

Occipital osteodiastasis is a birth injury, characteristic caused by the appearance of stretches and tears between the scales and the lateral parts of the occipital bone. This type of injury is typical for breech birth. When moving downwards, the fetal head, fixed by the back of the head at the pubic symphysis, is delayed and the scales of the occipital bone are torn off from its basal part at the level of the suture that existed in the embryonic period. A rare case is the separation of scales from the base of the occipital bone, which is a fatal injury, since it is accompanied by ruptures of the straight sinus, tentorium, crushing of cerebellar tissue and other injuries [53].

The main complications of depressed skull fractures are subdural and epidural hematoma, cerebral hemorrhage, contusion and cerebral edema, the formation of epileptogenic foci, and less commonly, the subsequent development of a brain tumor, neurological deficit (as rare as the manifestation of hematomas and hemorrhages) [47, 54]. Diagnosis of skull fractures is based on examination and palpation (abnormal concavity and deformation of the skull), radiographic examination (visualization of the degree

of skull deformation, sometimes false interpretation of suture lines and vascular grooves as fractures is possible), ultrasound (detection of intracerebral hemorrhages and hematomas). Computed tomography (CT) and MRI can be used for definitive diagnosis. CT makes it possible to more accurately differentiate the boundaries of the fracture, but has the disadvantage of a high dose of ionizing radiation [55]. MRI improves the accuracy of diagnosis when a fracture is combined with intracranial injury, but requires sedation to avoid artifacts caused by movement of the child [21].

Currently, there are no uniform protocols for the management and treatment of depressed skull fractures in newborns. Conservative and neurosurgical approaches are determined individually for each individual case [47]. Most fractures resolve spontaneously within 4–6 months [56]. In the absence of neurological symptoms, conservative treatment is recommended [57]. The prognosis for spontaneous depressed skull fractures in newborns is favorable in most cases. Long-term neurological consequences of instrument-associated depression fractures can be severe, but are rare, occurring in 4% of all cases [18].

Conclusion. Birth trauma most often occurs during complicated labor and surgical delivery. However, in some cases, birth trauma is a consequence of natural forces acting during the birth act. In this regard, even with a smooth pregnancy, the absence of external influences on the fetus and instrumental methods of delivery, it is impossible to exclude birth trauma in newborns.

REFERENCES

1. Abedzadeh-Kalahroudi M., Talebian A., Jahangiri M., Mesdaghinia E., Moham-

- madzadeh M. Incidence of neonatal birth injuries and related factors in Kashan, Iran // Arch. Trauma Res. 2015. Vol. 4, N 1. Article ID e22831.
2. Chaturvedi A., Chaturvedi A., Stanescu A.L., Blickman J.G., Meyers S.P. Mechanical birth-related trauma to the neonate: an imaging perspective // Insights Imaging. 2018. Vol. 9, N 1. P. 103–118.
3. Соколовская Т.А., Ступак В.С., Меньшикова Л.И., Постоев В.А. Заболеваемость и причины смертности у недоношенных и доношенных новорожденных детей в Российской Федерации // Экология человека. 2021. № 5. С. 20–27.
4. Кравченко Е.Н. Родовая травма: акушерские и перинатальные аспекты. Москва : ГЭОТАР-Медиа, 2009. 240 с.
5. Зедгенизова Е.В., Иванов Д.О., Прийма Н.Ф., Петренко Ю.В. Особенности по-казателей мозгового кровотока и центральной гемодинамики у детей, родившихся с задержкой внутриутробного развития (ЗВУР) // Бюллетень Федерального центра сердца, крови и эндокринологии имени В.А. Алмазова. 2012. № 3. С. 76–82.
6. Иванов Д.О. Неврологические нарушения у недоношенных детей, перенесших инфекционно-септический процесс в неонатальный период // Бюллетень Федерального центра сердца, крови и эндокринологии имени В.А. Алмазова. 2012. № 1. С. 69–73.
7. Курзина Е.А., Жидкова О.Б., Петренко Ю.В., Иванов Д.О., Шабалов Н.П. Прогнозирование состояния здоровья в катамнезе у детей, перенесших тяжелую перинатальную патологию // Детская медицина Северо-Запада. 2010. № 1. С. 22–27.
8. Сурков Д.Н., Капустина О.Г., Дука И.Г. и др. Посмертная диагностика родовой травмы: надрыв намента мозжечка у доношенного новорожденного с тяжелой бронхолегочной дисплазией // Трансляционная медицина. 2012. № 4 (15). С. 42–46.
9. Sauber-Schatz E.K., Markovic N., Weiss H.B., Bodnar L.M. et al. Descriptive epidemiology of birth trauma in the United States in 2003 // Paediatr. Perinat. Epidemiol. 2010. Vol. 24, N 2. P. 116–124.
10. Kaplan B., Rabinerson D., Avrech O.M., Carmi N. et al. Fracture of the clavicle in the newborn following normal labor and delivery // Int. J. Gynaecol. Obstet. 1998. Vol. 63, N 1. P. 15–20.
11. Ekéus C., Högberg U., Norman M. Vacuum assisted birth and risk for cerebral complications in term newborn infants: a population-based cohort study // BMC Pregnancy Childbirth. 2014. Vol. 14. P. 36.
12. Tavil B., Korkmaz A., Bayhan T., Aytac S. et al. Foetal and neonatal intracranial haemorrhage in term newborn infants: Hacettepe University experience // Blood Coagul. Fibrinolysis. 2016. Vol. 27, N 2. P. 163–168.
13. Gupta R., Cabacungan E.T. Neonatal birth trauma: analysis of yearly trends, risk factors, and outcomes // J. Pediatr. 2021. Vol. 238. P. 174–180.e3.
14. Van der Looven R., Le Roy L., Tanghe E., Samijn B. et al. Risk factors for neonatal brachial plexus palsy: a systematic review and meta-analysis // Dev. Med. Child Neurol. 2020. Vol. 62, N 6. P. 673–683.
15. Boulet S.L., Alexander G.R., Salihu H.M., Pass M. Macrosomic births in the united states: determinants, outcomes, and proposed grades of risk // Am.J. Obstet. Gynecol. 2003. Vol. 188, N 5. P. 1372–1378.
16. Moczygemba C.K., Paramsothy P., Meikle S., Kourtis A.P. et al. Route of delivery and neonatal birth trauma // Am.J. Obstet. Gynecol. 2010. Vol. 202, N 4. P. 361.e1–e6.
17. Vlasjuk V., Malvasi A. The importance of asynclitism in birth trauma and intrapartum sonography // J. Matern. Fetal Neonatal Med. 2022. Vol. 35, N 11. P. 2188–2194.
18. Preston D., Jackson S., Gandhi S. Non-traumatic depressed skull fracture in a neonate or «ping pong» fracture // BMJ Case Rep. 2015. Vol. 2015. Article ID bcr2014207077.

19. Linder N. et al. Birth trauma – risk factors and short-term neonatal outcome // *J. Matern. Fetal Neonatal Med.* 2013. Vol. 26, N 15. P. 1491–1495.
20. Del Pozzo-Magaña B.R., Ho N. Subcutaneous fat necrosis of the newborn: a 20-year retrospective study // *Pediatr. Dermatol.* 2016. Vol. 33, N 6. P. e353–e355.
21. Doumouchsis S.K., Arulkumaran S. Head trauma after instrumental births // *Clin. Perinatol.* 2008. Vol. 35, N 1. P. 69–83, viii.
22. Katzman G.H. Pathophysiology of neonatal subconjunctival hemorrhage // *Clin. Pediatr. (Phila.)*. 1992. Vol. 31, N 3. P. 149–152.
23. Holden R., Morsman D.G., Davidek G.M., O'Connor G.M. et al. External ocular trauma in instrumental and normal deliveries // *Br.J. Obstet. Gynaecol.* 1992. Vol. 99, N 2. P. 132–134.
24. McAnena L., O'Keefe M., Kirwan C., Murphy J. Forceps delivery-related ophthalmic injuries: a case series // *J. Pediatr. Ophthalmol. Strabismus.* 2015. Vol. 52, N 6. P. 355–359.
25. Thacker K.E., Lim T., Drew J.H. Cephalhaematoma: a 10-year review // *Aust. N. Z.J. Obstet. Gynaecol.* 1987. Vol. 27, N 3. P. 210–212.
26. Plauché W.C. Subgaleal hematoma. A complication of instrumental delivery // *JAMA.* 1980. Vol. 244, N 14. P. 1597–1598.
27. Ng P.C., Siu Y.K., Lewindon P.J. Subaponeurotic haemorrhage in the 1990s: a 3-year surveillance // *Acta Paediatr.* 1995. Vol. 84, N 9. P. 1065–1069.
28. Gebremariam A. Subgaleal haemorrhage: risk factors and neurological and developmental outcome in survivors // *Ann. Trop. Paediatr.* 1999. Vol. 19, N 1. P. 45–50.
29. Towner D., Castro M.A., Eby-Wilkens E., Gilbert W.M. Effect of mode of delivery in nulliparous women on neonatal intracranial injury // *N. Engl. J. Med.* 1999. Vol. 341, N 23. P. 1709–1714.
30. Jhawar B.S, Ranger A., Steven D., Del Maestro R.F. Risk factors for intracranial hemorrhage among full-term infants: a case-control study // *Neurosurgery.* 2003. Vol. 52, N 3. P. 581–590.
31. Pollina J., Dias M.S., Li V., Kachurek D., Arbesman M. Cranial birth injuries in term newborn infants // *Pediatr. Neurosurg.* 2001. Vol. 35, N 3. P. 113–119.
32. Uhing M.R. Management of birth injuries // *Pediatr. Clin. North Am.* 2004. Vol. 51, N 4. P. 1169–1186, xii.
33. Rooks V.J., Eaton J.P., Ruess L., Petermann G.W. et al. Prevalence and evolution of intracranial hemorrhage in asymptomatic term infants // *AJNR Am.J. Neuroradiol.* 2008. Vol. 29, N 6. P. 1082–1089.
34. Looney C.B., Smith J.K., Merck L.H., Wolfe H.M. et al. Intracranial hemorrhage in asymptomatic neonates: prevalence on MR images and relationship to obstetric and neonatal risk factors // *Radiology.* 2007. Vol. 242, N 2. P. 535–541.
35. Whitby E.H., Griffiths P.D., Rutter S., Smith M.F. et al. Frequency and natural history of subdural haemorrhages in babies and relation to obstetric factors // *Lancet.* 2004. Vol. 363, N 9412. P. 846–851.
36. Kemp A.M., Jaspan T., Griffiths J., Stoodley N. et al. Neuroimaging: what neuroradiological features distinguish abusive from non-abusive head trauma? A systematic review // *Arch. Dis. Child.* 2011. Vol. 96, N 12. P. 1103–1112.
37. Zamora C., Sams C., Cornea E.A., Yuan Z. et al. Subdural hemorrhage in asymptomatic neonates: neurodevelopmental outcomes and MRI findings at 2 years // *Radiology.* 2021. Vol. 298, N 1. P. 173–179.
38. Hayden C.K. Jr., Shattuck K.E., Richardson C.J., Ahrendt D.K. et al. Subependymal germinal matrix hemorrhage in full-term neonates // *Pediatrics.* 1985. Vol. 75, N 4. P. 714–718.
39. Al Tawil K., Saleem N., Kadri H., Rifaie M.T., Tawakol H. Traumatic facial nerve palsy in newborns: is it always iatrogenic? // *Am.J. Perinatol.* 2010. Vol. 27, N 9. P. 711–713.
40. Borschel G.H., Clarke H.M. Obstetrical brachial plexus palsy // *Plast. Reconstr. Surg.* 2009. Vol. 124, N 1 Suppl. P. 144e–155e.

41. Alfonso D.T. Causes of neonatal brachial plexus palsy // Bull. NYU Hosp. Jt Dis. 2011. Vol. 69, N 1. P. 11–16.
42. Menticoglou S.M., Perlman M., Manning F.A. High cervical spinal cord injury in neonates delivered with forceps: report of 15 cases // Obstet. Gynecol. 1995. Vol. 86, N 4. Pt 1. P. 589–594.
43. Patil M.N., Palled E. Epiphyseal separation of lower end humerus in a neonate- diagnostic and management difficulty // J. Orthop. Case Rep. 2015. Vol. 5, N 4. P. 7–9.
44. Basha A., Amarin Z., Abu-Hassan F. Birth-associated long-bone fractures // Int. J. Gynaecol. Obstet. 2013. Vol. 123, N 2. P. 127–130.
45. Arifin M.Z. et al. Spontaneous depressed skull fracture during vaginal delivery: a report of two cases and literature review // Indian J. Neurotrauma. 2013. Vol. 10, N 1. P. 33–37.
46. Dupuis O., Silveira R., Dupont C., Mottolise C. et al. Comparison of «instrument-associated» and «spontaneous» obstetric depressed skull fractures in a cohort of 68 neonates // Am.J. Obstet. Gynecol. 2005. Vol. 192, N 1. P. 165–170.
47. Zalatimo O., Ranasinghe M., Dias M., Iantosca M. Treatment of depressed skull fractures in neonates using percutaneous microscrew elevation // J. Neurosurg. Pediatr. 2012. Vol. 9, N 6. P. 676–679.
48. Oh C.K., Yoon S.H. The significance of incomplete skull fracture in the birth injury // Med. Hypotheses. 2010. Vol. 74, N 5. P. 898–900.
49. Ben-Ari Y., Merlob P., Hirsch M., Reisner S.H. Congenital depression of the neonatal skull // Eur. J. Obstet. Gynecol. Reprod. Biol. 1986. Vol. 22, N 4. P. 249–255.
50. Flannigan C., O'Neill C. Faulty fetal packing // BMJ Case Rep. 2011. Vol. 2011. Article ID bcr0220113802.
51. Tovar-Spinoza Z., Kim P.D. Congenital depressed skull fracture in the absence of trauma: case report and literature review // Res. Rep. Neonatol. 2012. Vol. 2. P. 11–14.
52. Zia Z., Morris A.-M., Paw R. Ping-pong fracture // Emerg. Med. J. 2007. Vol. 24, N 10. P. 731.
53. Власюк В.В. Родовая травма и перинатальные нарушения мозгового кровообращения Санкт-Петербург : Нестор-История, 2009
54. Saunders B.S., Lazowitz S., McArtor R.D., Marshall P. et al. Depressed skull fracture in the neonate. Report of three cases // J. Neurosurg. 1979. Vol. 50, N 4. P. 512–514.
55. Ganhão I. Spontaneous congenital ping-pong fracture // Neonatol. Clin. Pediatr. 2019. Vol. 6, N 3. P. 1–3.
56. Ilhan O., Bor M., Yukkaldiran P. Spontaneous resolution of a «ping-pong» fracture at birth // BMJ Case Rep. 2018. Vol. 2018. Article ID bcr2018226264.

REZYUME

YANGI TUG'ILGAN CHAQALOQLARDA TUG'MA JAROHATLAR (TAHLILIY SHARHLAR)

Zubtiyev Sardor O'ktamovich

Toshkent tibbiyot akademiyasi

Kalit so'zlar: tug'ma jarohatlar; siqilgan (ezilgan) sinish; chiziqli sinish; “ping pong” sinishi.

Tug'ma jarohatlar – tug'ruq paytida va periferik asab tizimi) shikastlanishi noqulay omillar ta'sirida homilaning hisoblanadi, Ba'zi hollarda tug'ilishdan (uning yumshoq to'qimalari, suyak-bo'g'im tizimi, ichki a'zolari, markaziy keyin paydo bo'lgan jarohatlar antenatal davrda rivojlanishi mumkin. Vaginal

(qin orqali) tug'ilish paytida yangi tug'ilgan chaqaloqlarning tug'ilish jarohatlari 3,6% hollarda, kesarchakesish amaliyoti paytida - 1,2% da sodir bo'ladi. So'nggi paytlarda yangi tug'ilgan chaqaloqlarning bosh qismi shikastlanishlarini aniqlash chastotasining ortishi tufayli, tug'ilishdagi tug'ma jarohatlarining kamayishi kuzatilmoqda, ushbu patologiya ayni paytda jiddiy uzoq muddatli oqibatlariga olib keladigan og'ir shikastlanishlar, nogironlik va o'lim holatlari

sezilarli darajada kamaydi. Tug'ma jarohatlar –ko'pincha murakkab tug'ruq va jarrohlik orqali tug'ish paytida sodir bo'ladi. Biroq, ba'zi hollarda, tug'ma jarohatlar tug'ilish paytida harakat qiladigan tabiiy kuchlarning natijasidir. Shu munosabat bilan, hatto silliq kechadigan homiladorlik paytida, homilaga tashqi ta'sirlarning yo'qligi va tug'ruqni instrumental usullari, yangi tug'ilgan chaqaloqlarda tug'ilish travmasini istisno qilish ham mumkin emas.

РЕЗЮМЕ РОДОВАЯ ТРАВМА У НОВОРОЖДЕННЫХ (АНАЛИТИЧЕСКИЕ ОБЗОРЫ)

Зубтиев Сардор Уктамович

Ташкентская медицинская академия

Ключевые слова: родовая травма; вдавленный перелом; линейный перелом; «пингпонговый» перелом

Родовая травма – это повреждение плода (его мягких тканей, костно-суставной системы, внутренних органов, центральной и периферической нервной системы) действием неблагоприятных факторов во время родов. В ряде случаев травма, проявляющаяся после рождения, может формироваться антенатально. Родовые травмы новорожденных при влагалищных родах встречаются в 3,6% случаев, при операции кесарева сечения – в 1,2%. В последнее время отмечается увеличение родового травматизма за счет повышения частоты выявления повреждений скальпа новорожденных,

при этом снижается регистрация тяжелых травм, приводящих к значительным отдаленным последствиям, инвалидизации и смерти. Родовая травма наиболее часто возникает при осложненном течении родов и оперативном родоразрешении. Однако в ряде случаев родовая травма является следствием естественных сил, действующих во время родового акта. В связи с этим даже при гладко протекающей беременности, отсутствии внешних воздействий на плод и инструментальных способов родоразрешения невозможно исключить родовую травму у новорожденных.