

Brain Morphological Changes in the Experimental Hypothyroidism Correction

Muminova Guyokhon^{1,*}, Isroilov Rajabboy², Inoyatova Feruza², Abdullaeva Mashkhura²

¹Andijan State Medical Institute, Andijan, Uzbekistan

²Tashkent Medical Academy, Tashkent, Uzbekistan

Abstract The developmental pathomorphological changes in the cerebral cortex and hippocampal tissue by introducing L-thyroxine and neuroprotectants into experimental hypothyroid-induced animals were studied in this research work. Treatment of hypothyroid animals with L-thyroxine for 10 days showed that perivascular and pericellular tumors remained in the cerebral cortex tissue, and colliquation foci appeared in some areas of the brain substance.

Keywords Hypothyroidism, L-thyroxine, Neuroprotectors, Hippocampus

1. Introduction

In recent years, there has been an increase in the incidence of endocrine diseases, especially thyroid disease. Among thyroid diseases, the proportion of hypothyroidism is large, accounting for 3–8% of the total population, and the majority of patients are adults, the elderly, young children, pregnant women [1,2]. Hypothyroidism - occurs with damage to all organs and organ systems of the body, including changes in the activity of the nervous system [3,4,5,6]. Among the pathological changes of the nervous system, neurological disorders in various cases of hypothyroidism also occupy a leading position.

The interest of neurologists in the problem of hypothyroidism is characterized by a wide range of neurological manifestations in the early stages of the disease, associated with its impact on all levels of the nervous system [2,7]. In hypothyroidism, cognitive function decreases, intelligence, memory and concentration deteriorate, disomnia syndrome develops, and sometimes depression is observed [8]. The main forms of neurological disorders in patients with primary hypothyroidism due to various causes are: encephalopolyneuropathy (69.8%), neuromuscular disorders (49.4%), encephalopathy (25.1%), encephalomyelopolyneuropathy (22.2%) and others include [9,10]. Epileptic seizures or fainting may occur in almost 20% of patients with hypothyroidism [10].

Neurological disorders resulting from hypothyroidism are now becoming more prevalent and over time will become one of the top priorities. Therefore, improving their

diagnosis and treatment methods has become one of the most pressing tasks of neurology.

2. Purpose of the Research

Detection of morphological changes in the brain and hippocampus in thyroid hypofunction and their correction.

3. Materials and Methods

Research material. In order to restore the morphological changes in the brain in experimental hypothyroidism, the drug "somazina" (Spanish pharmaceutical company "FERRER Internacional, S.A.") and "Neuromak" (pharmaceutical company "Radix NPP" in Uzbekistan) were selected in combination with L-thyroxine.

Research design. The study used adult male rats weighing 180-220 g without 120 white females fed a standard ration in the central laboratory of TashFarMI. All animal studies were conducted in accordance with WHO recommendations for working with experimental animals and adherence to precautionary measures. To achieve the goal, the state of hypothyroidism was modeled by injecting mercaptozol into the stomach of white rats at a dose of 2.5 mg/100 g [11]. The development of hypothyroidism was confirmed by monitoring body temperature, body weight gain, and general condition of the animals, and by detecting TTG, T3, and T4 hormones. Rats with hypothyroidism were divided into 4 groups: Group 1 - control; Group 2 - treated with thyroxine; Group 3 was treated with thyroxine and a neuroprotector "neuromak". In this article, only the second and third groups were examined.

Research methods: The animals were anesthetized by decapitation and fragments from the cerebral cortex and

* Corresponding author:

rakhmatullaev_physiology@yahoo.com (Muminova Guyokhon)

Received: Mar. 18, 2021; Accepted: Apr. 16, 2021; Published: Apr. 30, 2021

Published online at <http://journal.sapub.org/ijvmb>

hippocampus were obtained. Brain tissue fragments were solidified for 72 h in a 10% phosphate buffer solution of formalin. It was then dehydrated, poured into paraffin, bricks were prepared, and histological incisions were made. Histological incisions were stained with hematoxylin-eosin and Nissl stains, examined under a light microscope, the desired areas were photographed.

4. Results and Discussion

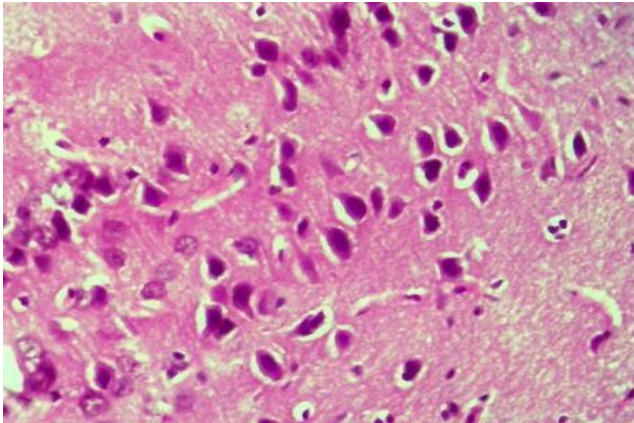


Figure 1. Thyroxine-treated group, cerebral cortex. Preservation of perivascular and pericellular tumors, hyperchromasis of neurons. Paint: G-E. X: 10x40

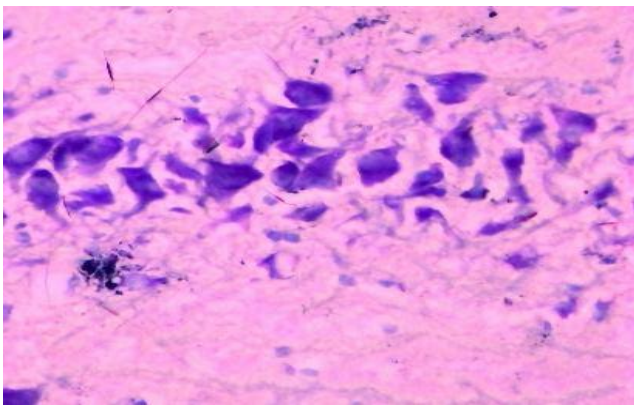


Figure 2. Thyroxine-injected group, day 10, hippocampus. The amount of tigroid substance in the cytoplasm of neurons is increased. Dye: Nissl method. X: 10x90

In experimental hypothyroid-induced animals, L-thyroxine-neuroprotectants were administered to study the developing pathomorphological changes in the cerebral cortex and hippocampal tissue. Treatment of hypothyroid animals with L-thyroxine for 10 days showed that perivascular and pericellular tumors persisted in the cerebral cortex tissue, colliculitis foci appeared in some areas of the brain substance. It should be noted that the darkening of the nucleus and cytoplasm, which are part of neurons and glial cells, hyperchromasis (Fig. 1), especially the increase in chromatin in the nucleus, indicates an increase in protein metabolism in these cells, while the tumor process is preserved in brain tissue. The fact that the pyramidal cells from the neurons are hyperchromasia, the granular cells are

stained with a relatively light color in the cytoplasm and nucleus, indicates a lack of chromatin in them (Fig. 2).

In hippocampal tissue, vascular fullness and persistence of perivascular tumor were observed. However, against the background of these changes, it was found that in the hippocampal band of neurons with a tapered structure, almost all types of cells are relatively dark-stained, their cytoplasm and nuclei are hyperchromatic (Fig. 2). However, it was observed that the molecular layer neurons on the lateral ventricular side of the hippocampus were swollen in both the cytoplasm and the nucleus, the karyoplasm was vacuolated and enlarged. During this period of experiments, Nissl staining of the hippocampal tissue revealed that the brain material was swollen and colligated with a band-like structure of neurons in the cytoplasm of the thyroid gland. It was observed that the dark ink was filled with a colored substance. The nuclei of these neurons also appear saturated and hyperchromatic.

The following data were obtained from microscopic examination of the cerebral cortex and hippocampal tissue after correction of experimental hypothyroidism with thyroxine and neuromack neuroprotector. On day 10 of the hypothyroidism combined correction experiment, there were almost no circulatory, edematous, and dystrophic changes in the cerebral cortex tissue, with only a small focal local edema process preserved around some small capillaries. The peculiarity of this period is that in the cerebral cortex tissue the above-mentioned diffuse gliosis process is slightly intensified. Morphologically, glial cells have different shapes, concentrated around neurons in some areas and concentrated around blood vessels in other areas. It is found that the nerve cells of the brain tissue are densely packed, unlike the anterior ones, most of which are both hypertrophied and hyperchromatic (Fig. 3). Their nuclei were stained dark and diffuse with hematoxylin, and an increase in chromatin content was observed. Brain Tissue Nissl-stained brain tissue found that all neurons in the brain tissue, including pyramidal neurons, were relatively dark-stained, they increased the amount of chromatophilic substance in the cytoplasm (Fig. 4) and the tigroid substance was distributed along neuronal fibers. It is observed that the nuclei of neurons are mostly round and their nuclei are stained dark blue.

Subsequent periods of the experiment, by 10 days, showed complete disappearance of morphological features characteristic of distirculatory, edematous, and dystrophic processes in hippocampal tissue. The hippocampal neurons retained a distinctive, band-shaped set of cells, all the neurons in the band, i.e., round-shaped neurons in the periphery, the pyramidal neurons in the middle, retained their histotopographic and histochemical structure (Fig. 5). The fact that the cytoplasm of all types of neurons is stained dark purple with eosin, the nuclei are dark ink, indicates the activation of their morphofunctional state. The brain substance around the neuronal band is also stained purple with eosin, and the glial cells in it are also morphologically active. When hippocampal tissue is stained by the Nissl

method, the activity of the morphofunctional state of the neurons in it is confirmed by the abundance of tigroid substance in the cytoplasm, scattered and intensively stained state (Fig. 6). Even in the cytoplasm of sparsely located neurons in the molecular layer of the hippocampus, tigroid substance appears to accumulate in large quantities.

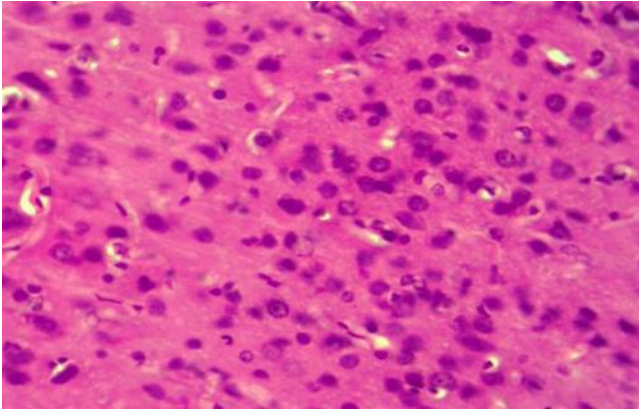


Figure 3. Correction group with thyroxine and neuroma, day 10, cerebral cortex. There is no tumor in the brain tissue, all neurons are hypertrophic and hyperchromatic. Paint: G-E. X: 10x40

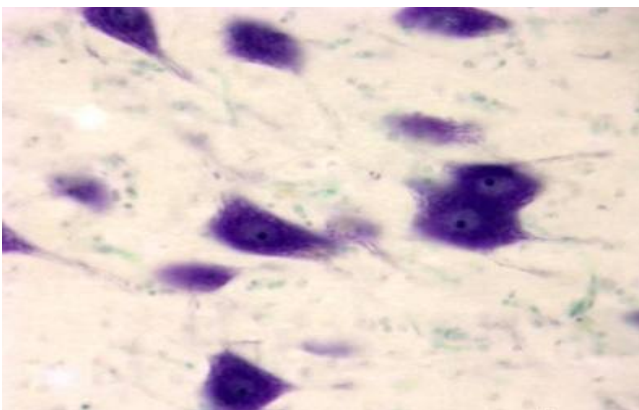


Figure 4. Correction group with thyroxine and neuroma, day 10, cerebral cortex. The cytoplasm of neurons is filled with tigroid substance. Dye: Nissl method. X: 10x90

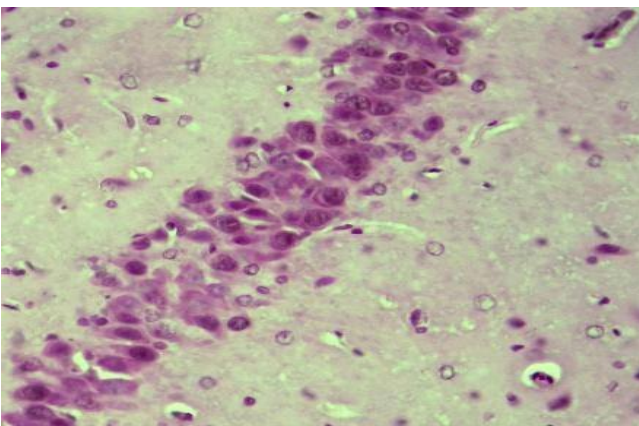


Figure 5. Correction group with thyroxine and neuromac, 10-day, hippocampus. Hypertrophy and hyperchromasia of neurons. Paint: G-E. X: 10x40

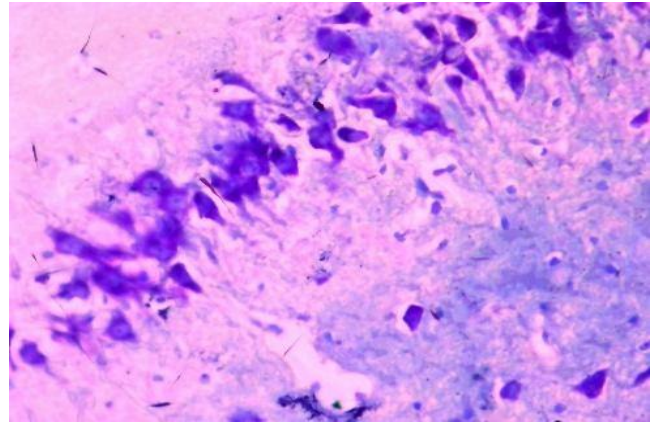


Figure 6. Correction group with thyroxine and neuromac, 10-day, hippocampus. An increase in thyrod substance in the cytoplasm of neurons. Dye: Nissl method. X: 10x40

5. Conclusions

In conclusion, the correction of experimental hypothyroidism with L-thyroxine at a dose of 3 $\mu\text{g}/\text{kg}$ resulted in relatively preserved circulatory and tumor processes in the cerebral cortex and hippocampal tissue, but increased activity of enzyme and protein metabolism under the influence of L-thyroxine in neurons and glial cells, confirms that both the cytoplasm is hypertrophic and hyperchromatic. There is an increase in tigroid substance in neurons.

The experimental hypothyroidism was corrected by a combination of thyroxine and neuroma, in contrast to the thyroxine-treated group, distillation and tumor processes in the brain and hippocampal tissue were stabilized and reduced from the beginning of the experiment. Absence of perivascular, pericellular tumors in the cerebral cortex and hippocampal tissue, activation of the morphofunctional state of both neurons and glial cells, hypertrophy and hyperprombosis, stimulation of neuroprotectors, cell membrane structures indicates.

Thus, in thyroid hypofunction depending on the duration of the experiment, swelling of the brain and hippocampus, cell dystrophy, loss of tigroid substance were observed, reduction of L-thyroxine and neurodegenerative changes, especially with the use of neuroprotectants, activation of morphofunctional status of glial cells.

REFERENCES

- [1] Afanasyev V.V. Clinical application of citicoline and its role in homeostasis of cell membranes of neurons and effector organs. // emergency medicine. -2016. No. 1 (72). - pp.46-50.
- [2] Grigorova I.A., Tovazhnyanskaya E.L. Pathogenetic aspects of the formation of neurological complications of primary hypothyroidism // News in neurology: XI Mizhnar. Conf. - Sudak, 2009. - pp. 338–343.

- [3] Makar R.D., Sandurska M.V. Hypothyroidism: conceptual aspects across the prism of the hour // *International Endocrinology journal*. - 2009. - No. 1 (19). - pp.124-131.
- [4] Namazova L.S., Shirokova I.V. Prevention of iodine deficiency diseases // *Pediatric Pharmacology*. – 2008. – No. 2. – pp.108–111.
- [5] Tovazhnyanskaya E.L. Neurological complications of primary hypothyroidism of various origins // *International medical journal*. - 2013. - №1. - pp.15-19.
- [6] Troshina E.A. Algorithm for the diagnosis and treatment of hypothyroidism // *Pharmateka*. – 2008. – №12. – pp.68–70.
- [7] Braverman L.E., Utiger R.D. *The thyroid: a Fundamental and clinical text*. 10th ed. Philadelphia: Lippicott Williams & Wilkins, 2013.- pp.735-878.
- [8] Lee E., Kim, S., Chung H, Park Ch. Dopamine neuron induction and the neuroprotective effects of thyroid hormone derivatives. // *Scientific Reports*. - 2019.- Vol.9. - 136-159. <https://doi.org/10.1038/s41598-019-49876-6>.
- [9] Noda M., Mori Y., Yoshioka Y. Sex- and Age-Dependent Effects of Thyroid Hormone on Glial Morphology and Function. // *Opera Med Physiol*.– 2016. - Vol.2(2).- pp.164-171.
- [10] Nunez J., Celi F.S., Ng L., Forrest D. Multigenic control of thyroid hormone functions in the nervous system. // *Molecular and Cellular Endocrinology*. - 2008. - Vol.287(1-2). - pp.1–12.
- [11] O'hare E., Kim E.-M., Page D., Reid R. Effects of thyroxine treatment on histology and behavior using the methimazole model of congenital hypothyroidism in the rat. // *Neuroscience*. - 2015. - Vol.285. - pp.128–138.