


*INTERNATIONAL SCIENTIFIC AND PRACTICE
CONFERENCE ON " INTERNATIONAL EXPERIENCE IN
INCREASING THE EFFECTIVENESS OF DISTANCE
EDUCATION: PROBLEMS AND SOLUTIONS" SPECIAL
ISSUE., 27 th March., 2022., France .,
Joint Conference IJSSIR*



o [PDF](#)

• **IMPROVE GOODWILL OPERATIONAL ACCOUNTING**

Vafoxodjaeva D.M

48-53

o [PDF](#)

• **The place of revenues from individuals in budget revenues**

Mukhabbat Volnazarovna Imamova

54-57

o [PDF](#)

• **Health and Medicine in the Islamic Tradition Based on the Book of Medicine (Kitab al-Tibb) by Sahih al-Bukhari**

Alidjanova Lazizkhon Abbasovna

58-61

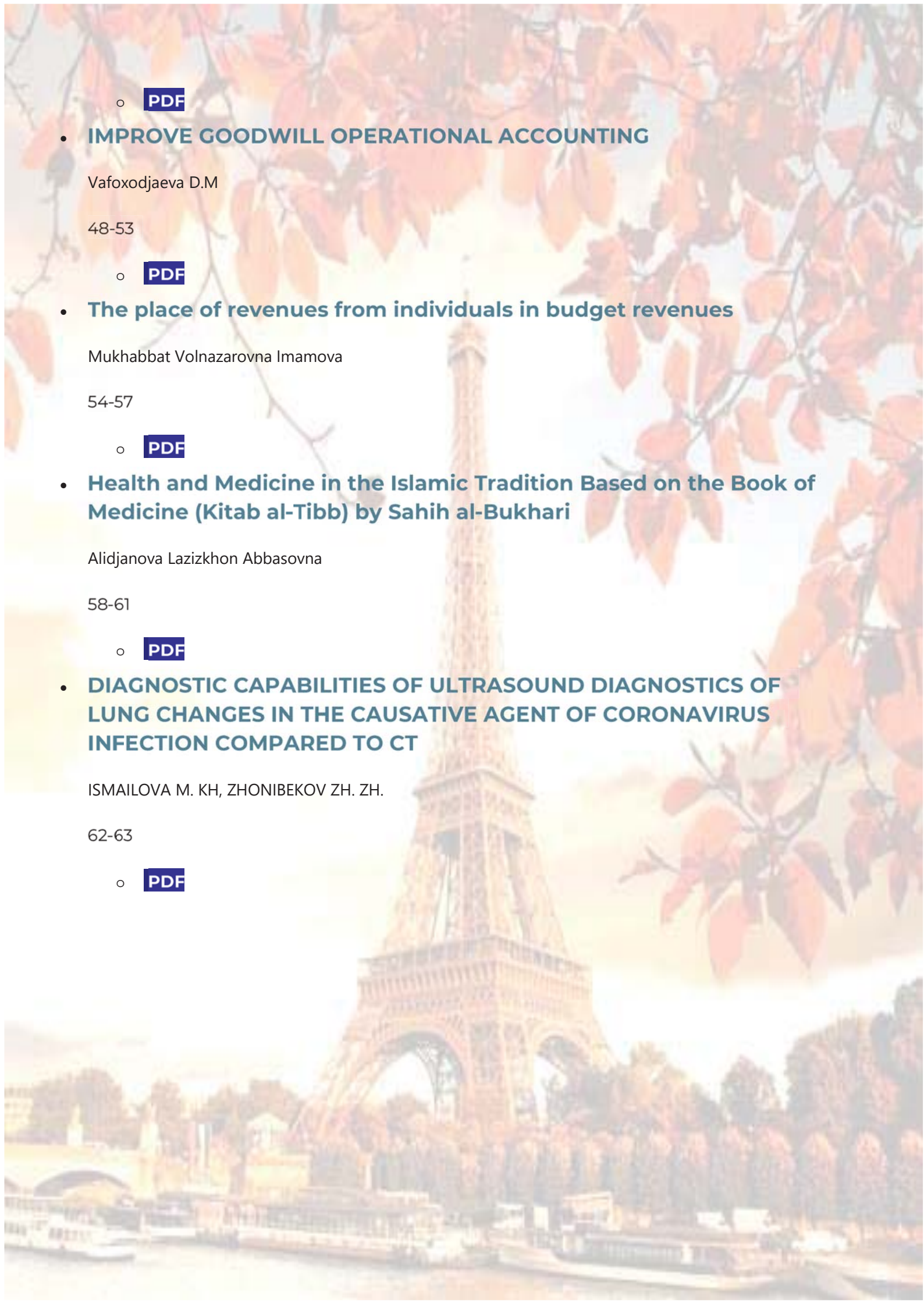
o [PDF](#)

• **DIAGNOSTIC CAPABILITIES OF ULTRASOUND DIAGNOSTICS OF LUNG CHANGES IN THE CAUSATIVE AGENT OF CORONAVIRUS INFECTION COMPARED TO CT**

ISMAILOVA M. KH, ZHONIBEKOV ZH. ZH.

62-63

o [PDF](#)



DIAGNOSTIC CAPABILITIES OF ULTRASOUND DIAGNOSTICS OF LUNG CHANGES IN THE CAUSATIVE AGENT OF CORONAVIRUS INFECTION COMPARED TO CT

ISMAILOVA M. KH., ZHONIBEKOV ZH. ZH.

BUKHARA STATE MEDICAL INSTITUTE

Relevance: *The " gold standard" of SARSCoV-2 diagnostics is the detection of viral RNA in a nasopharyngeal smear using PCR. In the diagnosis of COVID-19, the sensitivity of CT is 98%, which was significantly higher than the sensitivity of PCR-71%. Ultrasound of the lungs demonstrates a high diagnostic value in the assessment of various lung diseases and is superior in sensitivity and specificity to X-ray examination of the chest organs.*

The purpose of the study: *To determine the diagnostic accuracy of lung ultrasound compared to chest computed tomography (CT) in the diagnosis of lung changes in COVID-19.*

Materials and methods: The study involved 63 patients with an established coronavirus infection caused by the COVID-19 virus (M41: W 22) aged 27 to 90 years, who underwent a polypositional ultrasound with an assessment of 14 zones. Echograms of the lungs were compared with CT data on the prevalence of the process and the nature of structural changes. The diagnostic accuracy, sensitivity and specificity of ultrasound compared to CT results were determined, and 95% confidence intervals (CI) were calculated.

Results: In 62 patients (98.4%) with CT, pathological changes were detected in both lungs and had sub pleural localization. In 50 cases, the inflammation was limited only to the sub pleural parts, in 12- the changes spread to the central parts, while ultrasound revealed changes at a depth of no more than 4 cm. The lesion of 10-11 zones according to ultrasound corresponded to CT of the 1-2-th degree, the lesion of 13-14 zones-CT of the 3-4-th degree. The sensitivity of ultrasound in detecting lung changes of various types was $\geq 92\%$. The highest sensitivity of 97.9% (95% CI: 92.8–99.8%) was determined for small consolidations on the background of interstitial changes (degree 1a+, 1b+), which corresponded to the "cobblestone pavement" according to CT. The specificity depended on the nature of the changes and varied from 46.7 to 70.0%. The diagnostic accuracy was $\geq 81\%$, the maximum values of 90.6% (95% CI: 85.6–94.2%) were obtained for moderate interstitial changes (degree 1a) corresponding to "frosted glass" (the first type) according to CT data.

Discussion: When comparing the nature of lung damage by CT with ultrasound data, the following characteristic features were noted. Thus, the "frosted glass" type of lung compaction, which was determined on CT as a diffuse increase in the density of lung tissue while maintaining visibility of

the walls of blood vessels and bronchi, could be clearly divided into two types. The first type-a less intense and less dense "frosted glass" - mainly interstitial lesion with a minor alveolar component in the form of infiltration of pulmonary parenchymal edema with a density of -765 HU to -468 HU, on average - 655 HU-was localized in all parts of the lungs and was detected in 38 patients in 179 areas of analysis. On ultrasound, these changes corresponded to moderate interstitial changes (ultrasound grade 1a) and were characterized by the presence in one intercostal space of scattered B-lines extending vertically from the pleural line to the entire thickness of the visualized lung tissue, in an amount of more than 3, on average 6-8; B-lines could always be counted. Such changes were detected in 28 patients in 168 ultrasound zones. The second type is a more intense and dense "frosted glass" - interstitial lesion with an alveolar component with a density of -358 HU to -150 HU, with an average of -267 HU. Alveolar infiltration with a predominant content of large-molecular protein fluid was detected in 33 patients in 100 CT zones. During ultrasound, these patients had pronounced interstitial changes characterized by multiple B-lines that merged with each other; their number could not be counted (ultrasound gradation 1b. Such changes were detected in 23 patients in 92 ultrasound zones. Thus, lung ultrasound is of great importance for the diagnosis of COVID-19 due to its safety, availability, lack of radiation exposure, low cost, and the possibility of using it at the patient's bedside in the intensive care unit. **Conclusion:** The sensitivity of ultrasound in detecting lung changes in COVID-19 is more than 90%. Limitations of ultrasound are the lack of the ability to clearly determine the prevalence of the process and identify centrally located areas of changes in the lung tissue, as well as the upper parts of the lungs. However, ultrasound scanning of lung tissue is an auxiliary method for diagnosing viral pneumonia caused by the new COVID-19 coronavirus. The method can be used in clinical situations in which there is a mild course of the disease, if it is impossible to conduct a study and to monitor patients who are on a ventilator. The advantages of the method include the possibility of obtaining a dynamic image in online mode, the possibility of conducting a study at the patient's bedside. In addition, ultrasound scanning of lung tissue, unlike CT of the lungs, has an advantage in recognizing interstitial lesions and displays the distribution of blood flow in the tissues with an assessment of the degree of angiogenesis in inflammatory viral lung lesions.

References:

1. Fang Y., Zhang H., Xie J., Lin M., Ying L., Panget P. et al. Sensitivity of Chest CT for COVID-19: Comparison to RT-PCR [published online ahead of print, 2020 Feb 19]. *Radiology*. 2020.
2. Franquet T. Imaging of pulmonary viral pneumonia. *Radiology*. 2011; 260 (1): 18–39.
3. Kligerman S.J., Franks T.J., Galvin J.R. From the radiologic pathology archives: organization and fibrosis as a response to lung injury in diffuse alveolar damage, organizing pneumonia, and acute fibrinous and organizing pneumonia. *Radiographics*. 2013; 33 (7): 1951–75.