

ЎЗБЕКИСТОН РЕСПУБЛИКАСИ СОҒЛИҚНИ САҚЛАШ ВАЗИРЛИГИ
ТОШКЕНТ ТИББИЁТ АКАДЕМИЯСИ

2022 №

2011 йилдан чиқа бошлаган

ТОШКЕНТ ТИББИЙОТ АКАДЕМИЯСИ АХБОРОТНОМАСИ



ВЕСТНИК ТАШКЕНТСКОЙ МЕДИЦИНСКОЙ АКАДЕМИИ

СПЕЦВЫПУСК ПОСВЯЩЁН

**Республиканской научно-практической конференции
с международным участием**

**«Коронавирусная инфекция: актуальные вопросы
диагностики и лечения в медицинской практике»**

Андижан

Содиқова Д.Т., Кутликова Г.М. COVID-19-ЛИ ПНЕВМОНИЯНИНГ МОРФОЛОГИК БЕЛГИЛАР АЛГОРИТМИ	77
Тошбоев Ш.О., Абдуллажонов Х.М. ОСОБЕННОСТИ ТЕЧЕНИЯ КОРОНАВИРУСНОЙ ИНФЕКЦИИ ПО ДАННЫМ ОБЛАСТНОЙ ДЕТСКИЙ МНОГОПРОФИЛЬНЫЙ МЕДИЦИНСКИЙ ЦЕНТР Г. АНДИЖАН	83
Тошбоев Ш.О., Исмоилов Р.А. К ПРОБЛЕМЕ ИСККУСТВЕННОЙ ВЕНТИЛЯЦИИ ЛЕГКИХ У ПАЦИЕНТОВ С COVID-19 И НЕКОТОРЫЕ ПУТИ ИХ РЕШЕНИЯ	86
Usmanova E.M. FEATURES OF CLINICAL COURSE, DIAGNOSIS AND TREATMENT OF DIARRHEA IN PATIENTS WITH COVID-19	89
Хакимов Н.С., Хакимова Р.А., Кучкарова М., Кобилов А.А. МЕТОДЫ УЛЬТРАЗВУКОВОГО ИССЛЕДОВАНИЯ ЛЕГКИХ В ЦЕЛЯХ ДИАГНОСТИКИ КОВИДНОЙ ПНЕВМОНИИ В УСЛОВИЯХ ПОЛИКЛИНИКАХ НА СЕЛЕ	93
Хакимова Р.А., Садикходжаев С.Ш., Махсумова Д.К. КЛИНИЧЕСКОЕ ТЕЧЕНИЕ ТУБЕРКУЛЕЗНОЙ ИНФЕКЦИИ В РАЗЛИЧНЫЕ СРОКИ ПОСЛЕ ПЕРЕНЕСЕННОЙ КОРОНАВИРУСНОЙ ИНФЕКЦИИ.	95
Хакимова Р.А., Хакимов Н.С., Абдумананова Р.К., Абдукадырова Г. ПРОБЛЕМЫ ДИАГНОСТИКИ И ДИФФЕРЕНЦИАЛЬНОЙ ДИАГНОСТИКИ COVID-19 У ДЕТЕЙ – ПОДРОСТКОВ ПЕРЕНЕСШИХ ТУБЕРКУЛЕЗ	98
Хакимова Р.А., Халилов Ж.Х., Абдумананова Р.К., Низомов Я.К. ПРЕДУПРЕЖДЕНИЕ ЗАНОСА И РАСПРОСТРАНЕНИЯ КОРОНАВИРУСНОЙ ИНФЕКЦИИ В ПРОТИВОТУБЕРКУЛЕЗНЫЙ СТАЦИОНАР	101
Халилов Н.А., Юлдашева Г.Б. ОСОБЕННОСТИ ТЕЧЕНИЯ БРОНХИАЛЬНОЙ АСТМЫ У ПАЦИЕНТОВ, ПЕРЕНЕСШИХ COVID-19	104
Хамидов Ф.Ш., Алиев Л.М., Хамидов М.З., Пулатов Б.Т. COVID-19 ДАН КЕЙИН КУЗАТИЛГАН ЭШАКЕМ КАСАЛЛИГИДА ДЕРМАТОЛОГИК ИНДЕКСЛАР	107
Хамидов Ф.Ш., Пакирдинов А.Б., Фозилов Ф., Хамидова М.З., Ботиров К.З., Қучқаров А.А., Алиев Л.Т., Тошўлатов Б., Насриддинова Н.Б., Абдурахмонов А.А., Мўминов М.М. COVID-19 ЭПИДЕМИЯСИ ВА АНТИСЕПТИК АЛЛЕРГИЯ	110
Хамидов Ф.Ш., Алиев Л.М., Хамидов Ф.Ш. COVID-19: НИҚОБЛАРНИ ТЕРИГА ТАЪСИРИ	114
Хамидов Ф.Ш., Гаджимурадов М.Н., Пакирдинов А.Б., Ботиров К.З., Кучкаров А.А., Алиев Л.М., Хамидова М.З., Абдужаббаров Т.К., Абдурахманов А.А., Фозилов Ф.А. РЕЗУЛЬТАТЫ КОМПЛЕКСНОГО ПРИМЕНЕНИЯ ПРЕПАРАТОМ КОЛОСТРУМА, ОЗОНИУМ, УГРИНОЛ ПРИ АКНЕ ПОСЛЕ COVID-19	117
ДИАГНОСТИКА И ПРОФИЛАКТИКА ЗАБОЛЕВАНИЙ	
Иноятова Ф.И., Юсупалиева Г.А. ОСОБЕННОСТИ ДОПплерографических показателЕй ПРИ ХРОНИЧЕСКИХ ВИРУСНЫХ ГЕПАТИТАХ С ПЕРЕХОДОМ В ЦИРРОЗ ПЕЧЕНИ У ДЕТЕЙ	121
Каландаров Д.М., Мамасолиев Н.С., Салохидинов А.С. ОЦЕНКА АКТИВНОЙ ПРОФЛАКТИКИ АРТЕРИАЛЬНОЙ ГИПЕРТОНИИ В НЕОРГАНИЗОВАННОЙ СЕЛЬСКОЙ ПОПУЛЯЦИИ	125
Madumarova Z.Sh., Xodjibekov M.X., Nazarova G. U., Xamidova G.J., Adilova G. R.. ADVANTAGES OF ULTRASONOGRAPHY IN INFLAMMATORY AND DEGENERATIVE DISEASES OF THE HIP JOINT	128
Машрапова З.М., Икрамов А.Ф. СОВРЕМЕННЫЕ ПРОБЛЕМЫ ДИАГНОСТИКИ И ЛЕЧЕНИЯ ВОСПОЛИТЕЛЬНЫЕ ЗАБОЛЕВАНИЯ ЗРИТЕЛЬНОГО НЕРВА	131
Нормурадова Н.М. УЛЬТРАЗВУКОВАЯ ДИАГНОСТИКА СЛОЖНЫХ ВАРИАНТОВ ТЕТРАДЫ ФАЛЛО В ПРЕНАТАЛЬНОМ ПЕРИОДЕ	134
Пакирдинов А.Б., Юнусова С.И., Сайдуллаева К.М. ФУНКЦИОНАЛЬНОЕ СОСТОЯНИЕ ГИПОФИЗАРНО-ЯИЧНИКОВОЙ СИСТЕМЫ У БОЛЬНЫХ ПСОРИАЗОМ В ПРОЦЕССЕ ИГЛОТЕРАПИИ	140
Расулова М.М., Мейлиев А.М. КОМПЛЕКСНАЯ ЭХОГРАФИЯ В ОПРЕДЕЛЕНИИ СТЕПЕНИ НАСТОРОЖЕННОСТИ НА ЗЛОКАЧЕСТВЕННЫЙ ПРОЦЕСС КИСТОЗНО-СОЛИДНЫХ УЗЛОВЫХ ОБРАЗОВАНИЙ ЩИТОВИДНОЙ ЖЕЛЕЗЫ	143

ADVANTAGES OF ULTRASONOGRAPHY IN INFLAMMATORY AND DEGENERATIVE DISEASES OF THE HIP JOINT

Madumarova Z.Sh.¹, Xodjibekov M.X.², Nazarova G. U.¹, Xamidova G.J.¹, Adilova G. R.¹.

SON BUGIMINING YANGILISHI VA DEGENERATIV KASALLIKLARIDA ULTRASONOGRAFIYANI AVTOZYATLARI

Madumarova Z.Sh.¹, Xodjibekov M.X.², Nazarova G. U.¹, Xamidova G.J.¹, Adilova G. R.¹.

ПРЕИМУЩЕСТВА УЛЬТРАЗВУКОВОЙ ДИАГНОСТИКИ ПРИ ВОСПАЛИТЕЛЬНО-ДЕГЕНЕРАТИВНЫХ ЗАБОЛЕВАНИЯХ ТЕДРОСТНОГО СУСТАВА

Мадумарова З.Ш.¹, Ходжибеков М.Х.², Назарова Г.У.¹, Хамидова Г.Ж.¹, Адилова Г.Р.¹.

¹Andijan State Medical Institute, Andijan city, Uzbekistan

²Tashkent Medical Academy, Tashkent, Uzbekistan

Ushbu maqola son qo'shimchasining yallig'lanish va degenerativ kasalliklarini tashxislashda ultratovush tekshiruvini qo'llashga bag'ishlangan. Maqolada osteoartrroz (OA), revmatoid artrit va femur boshining aseptik nekrozi kasalliklarida ultratovush tekshiruvidan foydalanishning dolzarbligi, shuningdek, ultratovushli Doppler sonografiyasi asosida yallig'lanish va degenerativ jarayonlarni differentsial baholash muhokama qilinadi. Uzoq vaqt davomida oddiy rentgenografiya osteoartrit (OA) uchun mos yozuvlar texnikasi hisoblangan. So'nggi paytlarda ultratovush tekshiruvini vizualizatsiya qilishning innovatsion usuli hisoblanadi. Ultratovushdan foydalanish turli xil anatomik tuzilmalarni batafsil ta'kidlaydi va bo'g'im ichidagi va tashqaridagi o'zgarishlarni aniqlaydi.

Kalit so'zlar: Koksoartrroz, koksit, revmatoid artrit, oseoartrit aseptik nekroz, ultratovush, son bo'g'imlari, diagnostika.

Данная статья посвящена применению УЗИ в диагностике воспалительно-дегенеративных заболеваний тазобедренного сустава. В статье обсуждается актуальность применения УЗИ при заболевании остеоартрозом (OA), ревматоидным артритом и асептическим некрозом головки бедренной кости, а также дифференциальная оценка воспалительно-дистрофических процессов на основе данных ультразвуковой доплерографии. Долгое время простой рентген считался эталонным методом остеоартроза (OA). В последнее время ультразвуковая диагностика является инновационным методом визуализации этого заболевания. Использование ультразвука очень подробно выделяет различные анатомические структуры и обнаруживает внутри- и внесуставные изменения.

Ключевые слова: коксоартроз, коксит, ревматоидный артрит, остеоартроз, асептический некроз, УЗИ, тазобедренные суставы, диагностика.

Hip joint disease is one of the urgent problems of modern orthopedics, as it contributes to the rapid development of severe anatomical and functional inferiority of the musculoskeletal system, in particular in the elderly. According to WHO, more than ten percent of the world's population suffers from joint diseases. In terms of the frequency of lesions, the hip joint ranks first (42.7%), the second is the knee (33.3%), the third is the shoulder (10.8%), and the remaining joints account for 13.2% [1].

The differential diagnosis of lesions of the hip joint is difficult due to its deep occurrence and the presence of large muscle masses around the joint. In this regard, it is not possible to assess the external changes in the joint, it is very difficult to perform its puncture and arthroscopy. The differential diagnosis of coxarthrosis and coxitis at an early stage is especially difficult [2]. In this regard, the issue of differential diagnosis of diseases of the hip joint of dystrophic and inflammatory origin is relevant.

The ultrasound method, being non-invasive, reproducible and relatively affordable, can be widely used to assess both the accumulation of fluid inside the joint, in the joint bags, and to assess the thickness of the synovial membrane and erosive changes [3,4]. Modern ultrasound equipment makes it possible to evaluate both

superficial periarticular and intra-articular tissues that make up the joint.

Purpose of the study: Improving the Efficiency of Radiation Diagnosis of Inflammatory and Degenerative Diseases of the Hip Joint Based on the Ultrasound Method.

Materials and methods of research.

The total number of patients examined was 138, of which 15 (13.9%) were men and 93 were women (86.1%). The patients were divided into groups and subgroups. Group I included patients with dystrophic diseases (coxarthrosis stage I-III), a total of 82 people. Group II included 10 patients with coxarthrosis formed as a result of aseptic necrosis of the femoral head. Of these, men 5 (50%) people, women 5 (50%) people. Group III with inflammatory diseases included patients with rheumatoid arthritis, in the amount of 12 people. Of these, 4 men (33.3%) people, women 8 (66.7%) people.

All patients in the period from 2018 - 2020. were treated by an orthopedist in the ASMI clinic, and an ultrasound examination was carried out in the radiology department of the ASMI clinic in Andijan.

Ultrasound examination was carried out on digital multifunctional scanners "Sonoscape S-22" (China) and "Mindray DC3" (China). For the most clear visualization,

a study was used with convex and linear sensors, in the frequency range of 7-12 MHz.

Comprehensive ultrasound examination included survey scanning of the hip joint in gray scale mode, examination of the shape and contour of the femoral head, determination of the presence of effusion, measurement of parameters of the joint capsule, thickness of the hypoechoic layer of hyaline cartilage, examination of the state of muscles, ligaments and bones adjacent to the joint.

When evaluating the structures of the hip joint according to the standard method from the anterior approach, the bone landmarks were the upper edge of the acetabulum and the semicircle of the femoral head, where hypoechoic hyaline cartilage, the articular capsule of the hip joint were visualized (Fig. 1).

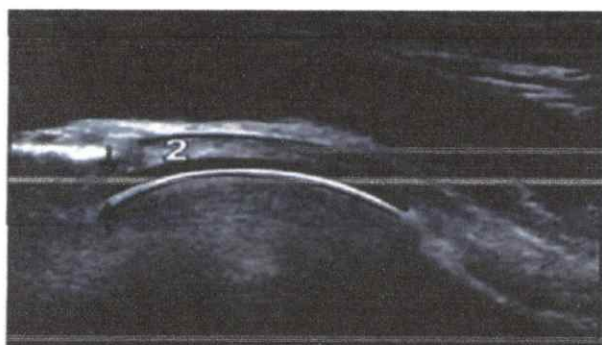


Fig. 1. Sonogram of the structural elements of the hip joint is normal. The arrows in the diagram show the measurement of the thickness of the hypoechoic layer of hyaline cartilage. 2 - fibrous capsule.

In patients of all groups, the regional blood flow in the lateral circumflex arteries of the thigh was assessed. The assessment of blood flow was carried out using color Doppler mapping and pulsed wave spectral Doppler, while assessing: peak blood flow velocity (PSV), end-diastolic blood flow velocity (DPV), resistance index (IR).

Research results

When analyzing the revealed sonographic and Dopplerographic diagnostic criteria for the stages of the pathological process, in patients of group I, it was revealed that the thickness of the hypoechoic layer of hyaline cartilage decreases from normal values of 2.4 mm to 1.3 mm as the stages of the disease increase in patients of subgroup IA, to 0.9 mm in subgroup IB and thins to 0.8 mm in subgroup I C. At stage III of coxarthrosis, the thickness of the hypoechoic layer of hyaline cartilage is 0.85 mm, and with coxarthrosis formed as a result of aseptic necrosis of the femoral head, cartilage in the necrosis zone is not visualized. In rheumatoid arthritis, there was an increase in the thickness of the fibrous capsule, up to 3.4 mm, in contrast to 2.23 mm with unchanged joints, and an important sign was the identification of normal sizes of hyaline cartilage. At the same time, the sizes of osteophytes increased as the stage of coxarthrosis increased from 4.2 mm to 10.1 mm. Thus, in stage III coxarthrosis, the size of osteophytes was 8.3 mm, and in coxarthrosis formed as a result of aseptic necrosis of the femoral head, it increased to 15.0 mm.

All patients with stages I-III of coxarthrosis revealed significant differences in the shape of the head of the hip joint, so if at stage I of the disease almost all (96%) of the examined patients had a spherical shape of the head, then at stage II of the disease only in 58% of cases a spherical shape was detected, and in 42% of cases - a moderately flattened shape of the head. At stage III, this sign increased and in 96% of cases it was found to be significantly flattened (Fig. 2).

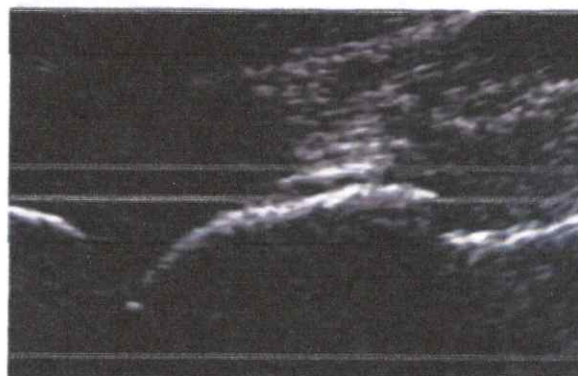


Fig.2. Sonogram of the hip joint in coxarthrosis (significantly flattened shape of the head).

When studying the joint cavity in patients with stage I coxarthrosis, effusion was practically absent (1% of cases), at stage II this sign was already detected in 10% of cases, and in patients with stage III coxarthrosis, effusion was visualized in 37% of cases. That is, as the disease progresses, the likelihood of effusion in the joint cavity increases.

When applying the method of ultrasonic dopplerography, a progressive decrease in the speed indicators of blood flow in the lateral circumflex arteries of the thigh was revealed as the stage of coxarthrosis increases, so the PVR decreases from 25.2 cm/s in the first stage of coxarthrosis to 16.6 cm/s in the third stage; CDS from 4.6 cm/s at the first stage to 2.1 cm/s at the III stage of coxarthrosis. In addition, if the PSS at stage II is 22.4 cm/s, and with coxarthrosis formed as a result of aseptic necrosis of the femoral head, it significantly decreases to an average of 17.8 cm/s. In rheumatoid arthritis, there was an increase in PSS of blood flow, on average, up to 28.0 cm/s, as well as an increase in DPV of blood flow, up to 8.1 cm/s. and a decrease in IR to 0.65, when comparing the values of groups with unchanged joints and stage II of coxarthrosis at 0.78 and 0.77, respectively.

Discussion

The thickness of the hyaline cartilage and fibrous capsule, the presence or absence of intra-articular effusion, the shape of the femoral head, the size of osteophytes (if any) are the main structural parameters on which the differential diagnosis of dystrophic and inflammatory diseases of the hip joint is based. In case of an inflammatory lesion of the hip joint, the leading sonographic criteria are: an increase in PVR to numbers - 32.0 cm/s, a CDP to - 10.3 cm/s, and a decrease in IR to numbers - 0.65, combined with an increase in the thickness of the fibrous capsules while maintaining the normal thickness of the hyaline cartilage. And the signs of

the presence of coxarthrosis are: a progressive decrease in the rate of blood flow in the lateral circumflex arteries of the thigh and progressive thinning of the hyaline cartilage, the presence of marginal osteophytes, a violation of the shape and contour of the femoral head. Coxarthrosis, formed as a result of aseptic necrosis of the femoral head, is characterized by a significant decrease in the rate of blood flow in the lateral circumflex arteries of the thigh (PRS up to digits - 17.8 cm/s, CDS up to digits - 3.7 cm/s) in combination with early and more complete thinning of the hyaline cartilage, more significant sizes of osteophytes, significant deformity of the femoral head, effusion in the joint cavity.

Conclusions

A number of undoubted advantages - non-invasiveness (unlike arthroscopy), accessibility, simplicity, cost-effectiveness (compared to CT and MRI) - provided the method of hip joint ultrasound with a priority among other instrumental methods for examining joints and soft tissues [5]. Ultrasound is highly informative in reflecting small details of the surface of bones, ligamentous tendon apparatus, and also allows you to identify and control inflammatory changes in tissues. The advantage of ultrasound over the X-ray method is safety, positionality, as well as the possibility of dynamic observation.

The most important features of a comprehensive ultrasound examination of the hip joints are: determination of the state of the joint capsule, the presence of effusion in the cavity of the hip joint, assessment of the sphericity and contour of the head, determination of the state of the hyaline cartilage and periarticular tissues, and using the Doppler method, the blood flow in the lateral circumflex arteries of the thigh is assessed, with the calculation of blood flow PSV, blood flow DPV and IR, which is quite important in the differentiation of inflammatory and degenerative processes.

References

1. Zhang, W. EULAR recommendations for knee and hip

osteoarthritis: a critique of the methodology / W. Zhang, M. Doherty // Br. J. Sports Med. - 2006. -Vol. 40.-p. 664-669.

2. Kovalenko, V.N. Osteoporosis. Practical guidance /N. Kovalenko, O.P. Bortkevich. - K.: Morion, 2003. - 448 p.

3. Khabirov, R.A. Ultrasound differential diagnosis of degenerative and inflammatory joint lesions / R.A. Khabirov, M.G. Tuxhatulin, E.R. Volkova // Nauch. - pract. rheumatology. - 2001. - No. 3. -p. 125.

4. Yaremenko, O.B. Modern algorithm for diagnosing rheumatoid arthritis / O.B. Yaremenko // Clinical Immunology. Allergology. Infectology. - Kiev, 2006. - No. 2. - p. 54-58.

5. Saltykova, V.G. Possibilities of ultrasound diagnostics in injuries and diseases of large joints / V.G. Saltykova, A.K. Morozov // Proceedings of the All-Russian Congress of Radiation Diagnostics. - M., 2007.-p. 316-317.

6. Divakov M.G., Boloboshko K.B. Early ultrasound diagnosis of osteochondropathy of the femoral head // News of Radiation Diagnostics. 1999; 2:12-13.

ADVANTAGES OF ULTRASONOGRAPHY IN INFLAMMATORY AND DEGENERATIVE DISEASES OF THE HIP JOINT

Madumarova Z.Sh., Xodjibekov M.X.,

Nazarova G. U., Xamidova G.J., Adilova G. R.

This article is devoted to the application of ultrasonography in the diagnosis of inflammatory and degenerative diseases of the hip joint. The article discusses the relevance of the use of ultrasound in the disease of osteoarthritis (OA), rheumatoid arthritis and aseptic necrosis of the femoral head, as well as the differential assessment of inflammatory and degenerative processes based on ultrasound Doppler sonography. For a long time, a simple X-ray was considered the reference technique of osteoarthritis (OA). Recently, ultrasonography is an innovative method for visualizing this disease. The use of ultrasound highlights the various anatomical structures in great detail and detects intra- and extra-articular changes.

Key words: Coxoarthrosis, coxitis, rheumatoid arthritis, osteoarthritis aseptic necrosis, ultrasonography, hip joints, diagnostics.