



Case Report

# Endoscopic transnasal transsphenoidal management of sellar/suprasellar arachnoid cyst: A case report and literature review

Maruf Matmusaev<sup>1,2</sup>, Tadashi Watanabe<sup>3</sup>, Kenichiro Iwami<sup>3</sup>, Tokhir Akhmediev<sup>4</sup>

<sup>1</sup>Department of Neurosurgery, Nagoya University Graduate School of Medicine, <sup>2</sup>Department of Skull Base Surgery, Republican Specialized Scientific Practical Medical Center of Neurosurgery, Tashkent, Uzbekistan, <sup>3</sup>Department of Neurosurgery, Aichi Medical University, Nagoya, Japan, <sup>4</sup>Department of Neurosurgery, Tashkent Medical Academy, Tashkent, Uzbekistan.

E-mail: \*Maruf Matmusaev - marufmatmusayev@gmail.com; Tadashi Watanabe - monasonayumikotadashi@gmail.com; Kenichiro Iwami - iwamins@gmail.com; Tokhir Akhmediev - tohir1209@mail.ru



**\*Corresponding author:**

Maruf Matmusaev,  
Department of Skull Base  
Surgery, Republican Specialized  
Scientific Practical Medical  
Center of Neurosurgery,  
Tashkent, Uzbekistan.

marufmatmusayev@gmail.com

Received : 08 December 2022

Accepted : 24 March 2023

Published : 07 April 2023

**DOI**

10.25259/SNI\_1102\_2022

**Quick Response Code:**



## ABSTRACT

**Background:** Arachnoid cysts (ACs) are collections of cerebrospinal fluids (CSFs) that develop within the arachnoid layer of the meninges. Sellar ACs are comparatively rare. In general, ACs account for approximately 1% of all intracranial mass lesions, and sellar ACs are 3% of all intracranial ACs. An endoscopic transnasal transsphenoidal approach for the treatment of ACs by fenestrating the cyst's wall and connecting with the subarachnoid space is the most optimal option.

**Case Description:** A 74-year-old woman whose sellar AC was diagnosed on magnetic resonance imaging a year ago was admitted to our hospital with complaints of bitemporal hemianopia and diminished visual acuity in the past 2 months. Sellar AC was diagnosed based on the clinical history and presentation, as well as neurologic, endocrinologic, and ophthalmologic examinations, including visual acuity and visual field examination, and additional imaging findings. The patient with a sellar/suprasellar AC was treated by an endoscopic transnasal transsphenoidal approach with cyst drainage and perforation of the lamina terminalis. Postoperatively, the visual disturbances improved markedly. No surgery-related complications occurred.

**Conclusion:** The endoscopic transnasal transsphenoidal approach remains a minimally invasive and preferred approach for the treatment of sellar/suprasellar ACs. Hermetically reconstructing the sellar floor is an effective method to prevent CSF leakage.

**Keywords:** Cerebrospinal fluid leak, Endonasal transsphenoidal surgery, Sellar/suprasellar arachnoid cyst

## INTRODUCTION

Arachnoid cysts (ACs) are collections of cerebrospinal fluids (CSFs) that develop within the arachnoid layer of the meninges. The cysts can develop at any place in the subarachnoid space along the cerebrospinal axis.<sup>[9]</sup> Sellar ACs are comparatively rare. In general, ACs account for approximately 1% of all intracranial mass lesions, and 3% of intracranial ACs are sellar ACs.<sup>[25,27,33]</sup> The most typical symptoms of ACs are visual disturbances; others are headaches and pituitary dysfunction.<sup>[8,9,33,44]</sup>

This is an open-access article distributed under the terms of the Creative Commons Attribution-Non Commercial-Share Alike 4.0 License, which allows others to remix, transform, and build upon the work non-commercially, as long as the author is credited and the new creations are licensed under the identical terms.

©2023 Published by Scientific Scholar on behalf of Surgical Neurology International

The purpose of the surgery for sellar ACs is to relieve symptoms and prevent complications. An endoscopic transnasal transsphenoidal approach for the treatment of ACs by fenestrating the cyst's wall and connecting with the subarachnoid space is the most optimal option.

A postoperative CSF leakage is a major complication of endoscopic transsphenoidal surgery (TS).<sup>[19,44]</sup> Serious complications of sellar ACs have also been reported, including visual loss,<sup>[42]</sup> meningitis,<sup>[26]</sup> and intracranial abscess.<sup>[22]</sup>

Many endoscopic neurosurgeons have reported different reconstructions of the skull base to prevent CSF leakage after endoscopic TS. Using fat graft, fascia lata, sphenoidal mucosa,<sup>[2]</sup> collagen sponge packing, and nasal septal flap<sup>[15]</sup> have been mentioned as effective in the prevention of CSF leakage after surgery.

Dural suturing is considered the safest method for the reconstruction of the skull base according to reports from some authors.<sup>[2,18,30,44,46]</sup> A continuous and tight dural suturing technique for reconstruction of the skull base is effective and usually does not require additional procedures such as lumbar drain placement and nasal septal flap insertion.<sup>[19]</sup>

Endoscope use in minimally invasive neurosurgery of the sellar and parasellar lesions has become an effective tool due to the panoramic views, bright lighting, and no blocks or dead corner in the surgical field. Moreover, an angled endoscope has the advantage of inspection beyond anatomic barriers and regions that will not allow a conventional operative microscope.<sup>[20,24,29]</sup>

In this paper, we describe a case of symptomatic sellar AC treated by endoscopic TS using fenestration in the subarachnoid space to prevent CSF leakage by continuous dural suturing with 6-0 monofilament sutures using an abdominal fat graft.

## CASE DESCRIPTION

A 74-year-old woman whose sellar AC was diagnosed on magnetic resonance imaging (MRI) a year ago was admitted to our hospital with complaints of bitemporal hemianopia and diminished visual acuity in the past 2 months. Her medical history revealed that she had chronic arterial hypertension. Sellar AC was diagnosed based on the clinical history and presentation and neurologic, endocrinologic, and ophthalmologic examinations, including visual acuity and visual field examination, and additional imaging findings.

The pituitary function was assessed using standard hormonal tests, such as the levels of thyroid-stimulating hormones and thyroxine (free-T3 and free-T4), growth hormones and insulin-like growth factor-1, plasma adrenocorticotropic hormones and serum cortisol, prolactin, luteinizing

hormones, and follicular-stimulating hormones. The patient's basal serum anterior pituitary hormone levels were within normal limits.

Visual function assessment involved measuring visual acuity using standard visual field testing. Visual field tests revealed bitemporal hemianopia and diminished visual acuity.

The radiologic diagnosis of a sellar AC is provided essentially by an MRI scan. MRI identified a well-defined, homogeneous, cystic sellar lesion with suprasellar extension and thin walls. The pituitary gland and stalk appeared stretched over the borders of the cyst and compressed against the dorsum sellae. No calcifications or solid areas were identified. On the MRI, a cystic lesion with dimensions of 30 × 15 × 17 mm and cystic mass content appeared isointense to the CSF. The optic chiasm (OCh) was compressed [Figure 1].

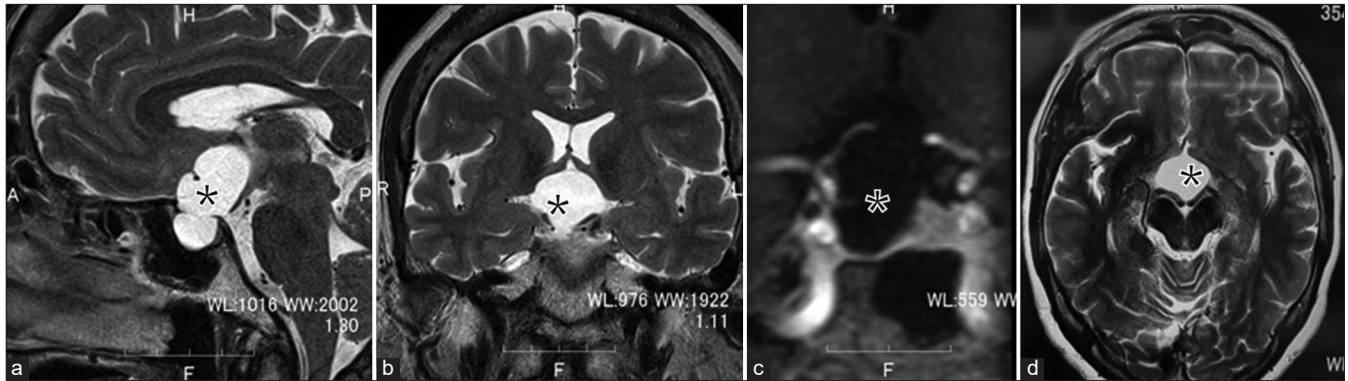
## Surgical procedures

An endoscopic endonasal approach is considered the first-line treatment for this lesion. The necessary tools for performing surgery are: 4 mm in diameter, 18 cm in length, with 0°, 30°, and 70° rigid endoscopes (Karl Storz, Tuttlingen, Germany), which are held by a floor-standing pneumatic holder (Uniarm [Mitaka Kohki, Tokyo, Japan]). They are designed to move smoothly and steadily.

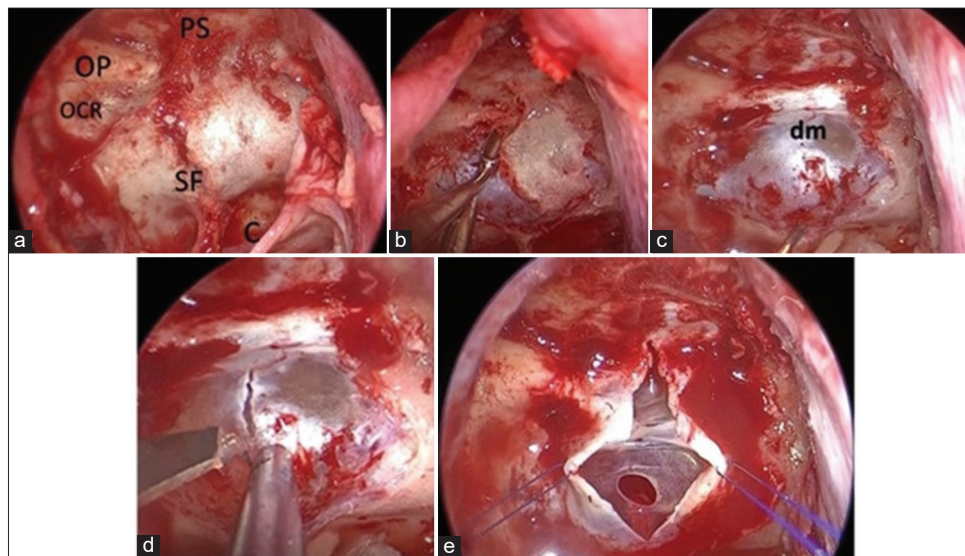
Under general anesthesia the patient was placed supine position with head raised 20° and fixed on a circle pillow. Extended endoscopic endonasal transsphenoidal approach with the navigational guidance was performed to the cystic sellar lesion.

After applying the nasal decongestant, the Ear, nose, and throat (ENT) surgeon started the operation from the left nostril. A submucosal-transseptal approach was performed. A mucosal incision was made near the mucosal junction, the nasal septum resected, the anterior wall of the sphenoid sinus opened, the septum removed, and the left sphenoid sinus mucosa turned downward. After accessing the sella, the neurosurgeon started the next step of the procedure with the assistance of the ENT surgeon and guiding endoscope. The septum was drilled, and the sella turcica, sellar tuberculum, and planum sphenoidale were drilled out after confirming the navigation. The upper part of the optic canal was carefully drilled out with a 3 mm drill. After a wide sphenoidotomy and sellar bone opening, a vertical dural incision was made, dural leaves lateralized to the sides using two Prolene 6.0 sutures, and then the AC was confirmed [Figures 2a-e] A clear, nonmucinous fluid similar in color to CSF was drained out at the moment of the incision, using suction and irrigation.

When the walls of the AC were opened, the pituitary gland, pituitary stalk, and OCh were visualized. The anterior communicating artery (Acom), right anterior cerebral artery



**Figure 1:** Preoperative pituitary magnetic resonance imaging showing an intrasuprasellar Arachnoid cyst. (a-c) Sagittal and coronal views reveal a large hyperintense and well-delineated sellar lesion (asterisk) with significant suprasellar extension. (d) Axial view. \*This lesion occupies the whole sella turcica.



**Figure 2:** Sellar stage. (a and b) Opening of the sellar floor, tuberculum sella, and planum sphenoidale were removed. (c) After opening the sellar floor, the dura mater was exposed. (d and e) Vertical incision of the dura mater using a surgical knife. Dural leaves were lateralised to the sides using two Prolene 6.0 sutures, and an Arachnoid cyst was confirmed. OP: Optic prominence, OCR: Opto-carotid recess, SF: Sellar floor, PS: Planum sphenoidale, C: Clivus, dm: Dura mater.

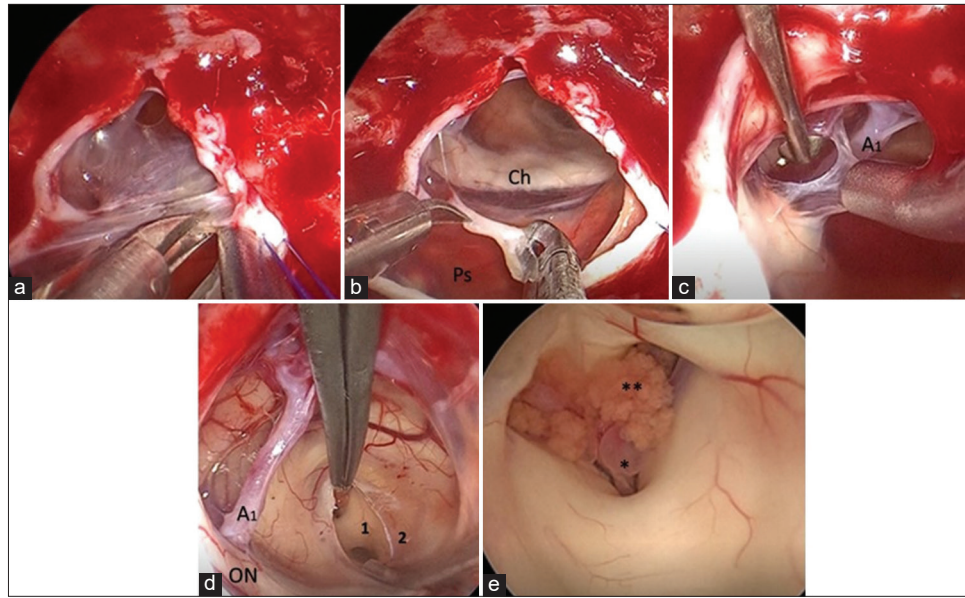
(A1), and OCh were also clearly observed [Figures 3a and b]. The wall of the cyst on the side of sella turcica was further incised and excised totally. The cyst wall specimen was sent for pathology. The arachnoid membrane in front of the right A1 was also opened [Figure 3c]. The subarachnoid space in the cystic wall was fenestrated using bipolar coagulation and sharp scissors. This step was performed carefully to avoid injuring the Acom and A1 segment of the anterior cerebral artery behind the arachnoid membrane.

Next, the thinned lamina terminalis was identified. This membrane was coagulated by bipolar and fenestrated using cautery and scissors. Then, the cavity of the third ventricle was inspected, and the massa intermedia, foramen of Monro,

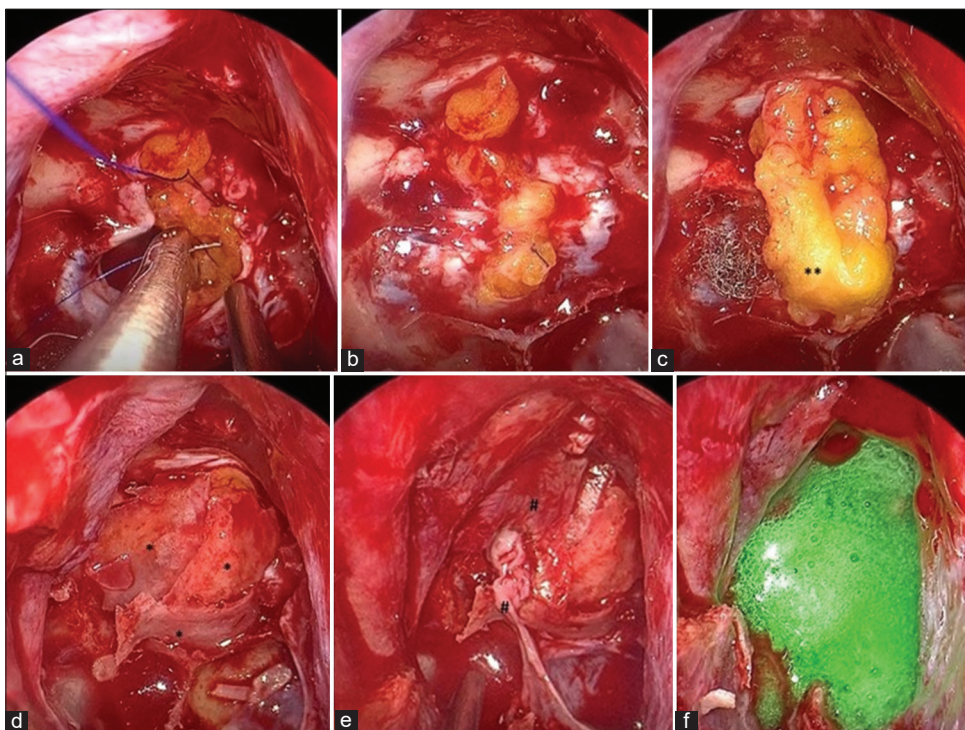
and choroid plexus, as well as thalamic veins, were visualized [Figures 3d and e]. CSF circulation was restored.

After confirming a good passage of CSF through the fenestration, the dura was closed. For closure, abdominal fat was taken and sutured continuously with 6-0 Prolene to the edges of the dura. We used another piece of compressed fat above the incision line as an onlay-graft. Then, the bony septum was divided into three pieces and laid on the fat graft and the sphenoid sinus mucosa and the upper right septal mucosa were overlaid to reconstruct the bony defect finally fixed with a dural sealant [Figures 4a-f].

The patient underwent endoscopic endonasal surgery, and the lesion was decompressed and fenestrated. Postoperative



**Figure 3:** Intraoperative images.(a) Excision of the left anterior part of the cyst wall. (b) Tissue collection. The pituitary stalk, optic chiasm, and right anterior cerebral artery (A1) were identified. (c) The anterior cyst wall was gradually dissected and removed from the right A1. (d) The lamina terminalis was coagulated by bipolar and fenestrated using cautery and scissors. (e) Foramen of Monroe (Wet field). Ch: Optic chiasm, Ps: Pituitary stalk, ON: Optic nerve. 1: Massa intermedia, 2: Lamina terminalis, \*Thalamic veins, \*\*Choroid plexus.



**Figure 4:** Reconstruction technique. Multilayer technique. Intraoperative views. (a) The view during the dural suturing. Continuous dural suture with abdominal fat, (b) The view after dural suturing, (c) Onlay fat. The dural opening is completely covered using fat, (d) Bone fragments are applied to the fat tissue, (e) The mucous membrane of the sphenoid sinus and right septum is used for the reconstruction of the sellae, (f) Synthetic dural sealant. \*Bony septum fragments, \*\*Abdominal fat, #Sphenoid sinus and the upper right septal mucosa.

patient's condition was without complications. Her visual disturbances were markedly improved and a pathological examination of the walls confirmed the diagnosis of an AC. No new endocrine abnormalities, CSF leak, meningitis, or neurological symptoms occurred. Follow-up (FU) MRI revealed a reduced size of the mass [Figure 5]. During the postoperative FU period (24 months), there was no further recurrence.

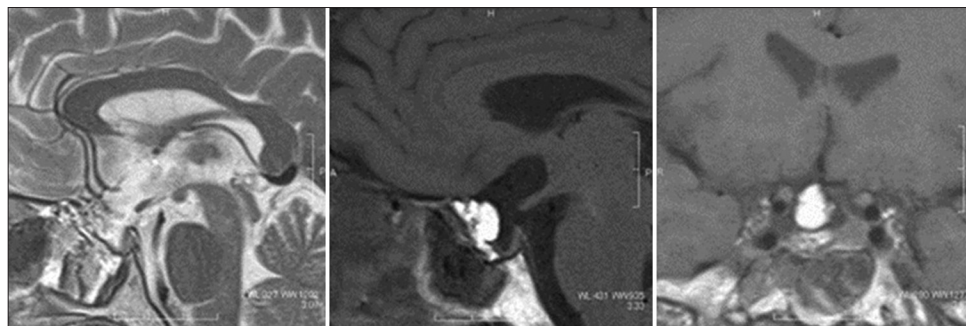
## DISCUSSION

In normal conditions, there is no arachnoid tissue below the diaphragma sellae, and the pathophysiology of the development of sellar/suprasellar ACs remains controversial. Several theories may explain and suggest the formation of sellar/suprasellar ACs. It has been suggested that sellar/suprasellar ACs arise from a defect in the diaphragm sellae, through which the basal arachnoid membrane prolapses. Consequently, sellar ACs begin as an intrasellar arachnoid diverticulum, forming a cyst by a narrowing of the diaphragm defect or adhesion formation between the arachnoid layers.<sup>[1,4,9,16,25]</sup> This defect may close due to meningitis, hemorrhage, or inflammatory event that isolates the AC.<sup>[9,12]</sup> According to another hypothesis of Meyer *et al.*, intrasellar ACs are created between the arachnoid layers just as other intracranial ACs. This diverticulum either

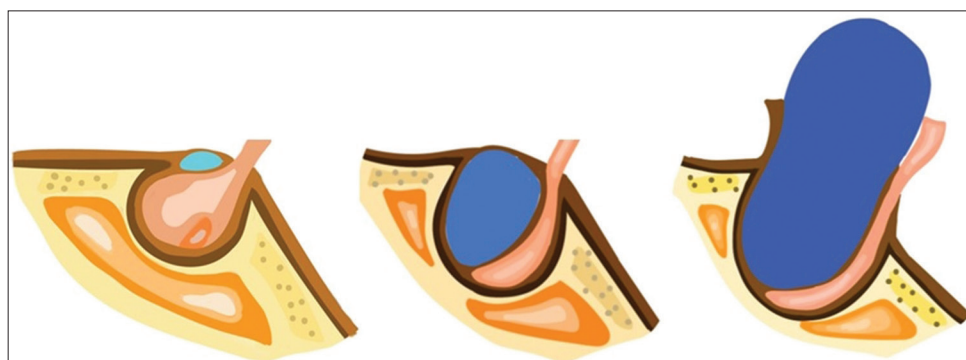
arises above the diaphragm, extends through its aperture, or develops from the subdiaphragmatic arachnoid layer.<sup>[26]</sup> Regardless of the mechanism, intrasellar ACs arise in front of the pituitary stalk, and as they expand, they compress the pituitary gland all the way down to the sellar floor [Figure 6]. Afterward, they expand into the suprasellar cistern.<sup>[31]</sup> The symptoms of sellar/suprasellar ACs are associated with the mass effect on the surrounding structures. The most common symptoms are headache and visual disturbance. The headaches may result from stretching of the diaphragma dura, while compression of the OCh causes a visual disturbance, presenting typically as bitemporal hemianopia. Due to the pituitary gland's compression, endocrine disorders are related to the gonadotroph axis.<sup>[1,9,12,17,40]</sup>

Radiologically, sellar/suprasellar ACs are diagnosed mainly by MRI scans. The main characteristics of MRI scans of sellar/suprasellar ACs are cystic lesions with suprasellar extension, balloon-shape, good-delineation, homogeneity, no contrast enhancement and calcification, molding without invading the cavernous sinus, intensity similar to CSF, hypointense T1-weighted signal, and a hyperintense T2-weighted signal on the MRI images.<sup>[9,10,12]</sup>

In the radiological differential diagnosis of sellar/suprasellar cystic lesions, Rathke's cleft cysts or craniopharyngiomas



**Figure 5:** Postoperative magnetic resonance imaging shows that the sellar arachnoid cyst has markedly decreased in size. The intrasellar part of the cyst covered by normal pituitary tissue is evident, and chiasma is not compressed. Fat graft is visualized as hyperintensity on T1 sagittal and coronal images.



**Figure 6:** Intrasellar arachnoid cyst illustrated schematically.

should be considered, being significant for preoperative planning. The differential diagnosis for sellar/suprasellar ACs in adults is summarized in Table 1.

The defining characteristics of craniopharyngiomas on the MRI are heterogeneous, mixed (mostly solid and cystic), calcified, and contrast-enhanced imaging features. The solid portion contains a hypointense T1-weighted signal, while the cystic portion's signal is changeable.<sup>[23,40,41]</sup> In comparison with craniopharyngiomas, Rathke's cleft cyst and AC have smooth contours and homogeneous lesions. Rathke's cleft cysts are located in the midline, beginning between the anterior and posterior pituitary. The majority of Rathke's cysts demonstrate some contrast enhancement, rare calcification of the cyst, and changeable T1-weighted and T2-weighted signals; it does not enhance but might exhibit an enhancing rim of compressed pituitary tissue surrounding the cyst.<sup>[23]</sup> The signal characteristics of the cystic fluid of craniopharyngiomas and Rathke's cleft cysts can vary from hypo- to hyperintense depending on relative concentrations of cholesterol, triglycerides, and protein.<sup>[10]</sup> Likewise, AC indicates no contrast enhancement, and the pituitary gland can be identified flattened against the sellar walls.<sup>[31]</sup>

The indications for surgery for sellar/suprasellar ACs include pituitary dysfunction, visual disturbance, and severe headaches. The surgery for the treatment of sellar ACs aims at the fenestration of the cyst wall to communicate between the cyst and subarachnoid space, as well as the decompression of the visual apparatus and the pituitary gland. Adequate therapy is the excision of the cyst wall, which will allow histological analysis to identify the lesion's pathology. Total removal of the walls of the cyst, to prevent damage to the pituitary gland is unnecessary.

Several surgical approaches have been described for treating sellar ACs, such as transcranial (pterional, frontotemporal, orbitofrontal, or subfrontal) and transsphenoidal (endoscopic or microscopic) approaches.<sup>[1,5,17,21,25,28,33,44]</sup> Aljuboori *et al.* used the orbitofrontal approach in the treatment of sellar ACs because of the minimal frontal lobe retraction, adequate space for cyst fenestration and a lower risk of CSF leakage than TS.<sup>[1]</sup> Shim and colleagues have described a transventricular endoscopic fenestration of intrasellar AC.<sup>[40]</sup>

Percutaneous ventriculocystostomy,<sup>[35]</sup> and cystoperitoneal shunting have been reported in the literature for the treatment of sellar ACs in pediatric patients. Although a cystoperitoneal shunt is considered one of the treatment options of choice for large cysts in pediatric patients, it is associated with early shunt dysfunction, subdural hemorrhage, and long-term shunt dependency.<sup>[3,36,40,43]</sup> For pure suprasellar ACs, endoscopic fenestration is suggested as the first choice therapy due to the low rate of complications compared with other methods.<sup>[39,40]</sup> However, transcranial approaches are recommended for the fenestration of large

Table 1: Differential diagnosis and defining characteristics of sellar/suprasellar ACs.

Pathology	Age at presentation, years	Symptoms or signs at presentation	Contrast enhancing?	Cystic	Calcification	Growth pattern	T <sub>1</sub> MRI characteristics		T <sub>2</sub> MRI characteristics	
							Solid	Cyst	Solid	Cyst
Craniopharyngioma	Bimodal (5–10 and 50–60 yrs)	Vision loss, HA, small stature, hypopituitarism, DI	Most	Most	Most	Idiosyncratic	Hypointense	Hyperintense	Variable*	Variable*
Rathke's cleft cyst	Young to middle aged adults	Vision loss, HA, small stature, hypopituitarism, DI	Some	Yes	Rare	Idiosyncratic	Hyperintense (if nodule present)	Hyperintense (if nodule present)	Variable*	Variable* (if nodule present)
AC	All ages	Asymptomatic, HA	No	Yes	No	No growth	N/A	N/A	Hypointense <sup>†</sup>	Hypointense <sup>†</sup>

CSF: Cerebrospinal fluid, DI: Diabetes insipidus, HA: Headache, N/A: Not applicable, \*\*Depending on the relative concentrations of cholesterol, protein, and triglycerides, the signal characteristics of Rathke's cleft cysts and craniopharyngiomas can range from hypo- to hyperintense; MRI: Magnetic resonance imaging, ACs: Arachnoid cysts. <sup>†</sup>The signal intensity of ACs tends to mirror that of CSF on all sequences, yrs: years, N/A: Not applicable

**Table 2:** Reported cases of sellar/suprasellar arachnoid cysts.

Authors	No of patients	Mean age, years	Sex	Clinical presentation	Surgical approach	Reconstruction method	Complications	Recurrence	Outcome
Benedetti <i>et al.</i> 1977 <sup>[5]</sup>	1-2	50	1 M 1 F	Headache, vision loss (2)	Subfrontal	NS	None	No recurrence at 12 and 6 mos	Improved visual acuity and headache Death from septic shock
Leo <i>et al.</i> 1979 <sup>[22]</sup>	3	60	F	Hemianopia	Microscopic TS	NS	Pituitary abscess	-	Improved visual acuity
Harter <i>et al.</i> 1980 <sup>[13]</sup>	4	24	M	Decreased visual acuity	Microscopic TS	NS	None	No recurrence at 8 mos	Improved visual acuity
Spaziante <i>et al.</i> 1981 <sup>[42]</sup>	5-7	55	3 F	Panhypopituitarism (1), headache (2), gross obesity (1), decreased visual acuity (2)	Microscopic TS	Yes, no mention of the material used	Blindness (prolapse of the optic chiasm into sella) that required 2 <sup>nd</sup> surgery for packing (1) CSF leakage, meningitis required 2 <sup>nd</sup> surgery (repacking) (1) None (1) None	No FU mentioned (2) No recurrence at 3 mos	Blindness persisted (1) Improved headache Partially improved visual acuity
Fujiwara <i>et al.</i> 1984 <sup>[11]</sup>	8	58	M	Decreased visual acuity	Microscopic TS	Packing with muscle and fat	None	No	Improved visual acuity
Baskin and Wilson, 1984 <sup>[4]</sup>	9-16	Mean 42.4	6 M 2 F	Headache: 4, hypopituitarism: 4, incidental: 4	Microscopic TS	Packing fat; nasal cartilage	1 case of CSF leak closed with LD; 2 cases of CSF leak and meningitis, 2 <sup>nd</sup> surgery (repacking and LP shunt)	No	Most cases of headache improved, hypopituitarism did not improve
Meyer <i>et al.</i> 1987 <sup>[26]</sup>	17-29	Mean 46	5 M 8 F	Headaches (7), vision loss (7), galactorrhea (3), impotence (2), infertility (1), hyperprolactinaemia (4)	Microscopic TS	Packing with muscle and fat; with a plate of nasoseptal bone or cartilage	1 death from Klebsiella meningitis Worth of normal pituitary function-2	No recurrence at 4.5 years	All patients with visual loss improved and anterior pituitary dysfunction was normalised. 2 patients with preoperative anterior pituitary dysfunction did not improve. Hyperprolactinemia was normalised. Improved visual acuity
Hasegawa <i>et al.</i> <sup>[14]</sup>	30	53	M	Decreased visual acuity	Microscopic TS	Autologous muscle, fascia, and adipose tissue; cartilage, chemical glue	CSF leakage and meningitis treated by LD	Recurrence after post-op 46 days. 2 <sup>nd</sup> surgery required (the right Sylvian approach).	Improved visual acuity

(Contd...)

Table 2: (Continued).

Authors	No of patients	Mean age, years	Sex	Clinical presentation	Surgical approach	Reconstruction method	Complications	Recurrence	Outcome
Hornig and Zervas 1992 <sup>[16]</sup>	31	57	M	Decreased visual acuity	Microscopic TS	Packing with fat	None	No recurrence at 6 years	Improved visual acuity
Tanaka et al. 1995 <sup>[47]</sup>	32	44	M	Decreased visual acuity. Panhypopituitarism	Microscopic TS	Filled with Gelfoam and repaired with bone flap	DI	No FU mentioned	Improved visual acuity. Panhypopituitarism improved
Nomura et al. 1996 <sup>[31]</sup>	33	57	M	Decreased visual acuity	Microscopic TS	NS	CSF leakage, meningitis required 2 <sup>nd</sup> surgery (repacking and VP shunt)	No FU mentioned	Improved visual acuity
Saeki et al. 1999 <sup>[8]</sup>	34	62	M	Decreased visual acuity	Microscopic TS	Fascia lata, adipose tissue, nasal bony septum, fibrin glue	CSF leakage, required 2 <sup>nd</sup> surgery (LD and repacking)	No FU mentioned	Improved visual acuity
Miyamoto et al. 1999 <sup>[27]</sup>	35–36	Mean 63	1 M 1 F	Headaches (2), decreased visual acuity (2)	Microscopic TS (1). Frontotemporal craniotomy (1)	Muscle, fibrin glue, bony septum	None	No FU mentioned	Improved visual acuity and headache
Shin et al. 1999 <sup>[41]</sup>	37–41	Mean 53	2 M 3 F	Headaches (3), decreased visual acuity (3), hypopituitarism (3)	Microscopic TS	NS	None	Mean FU 33±17 months with 1 case recurrence at 99 mos	Improved visual acuity, headache, and hypopituitarism
Weil, 2001 <sup>[48]</sup>	42	74	F	Decreased visual acuity	Sublabial transseptal transnasal	Abdominal fat graft, nasal bone, tissue adhesive	None	No recurrence at 6 mos	Improved visual acuity
Murakami et al. 2003 <sup>[28]</sup>	43	48	M	Decreased visual acuity	Microscopic TS	Adipose tissue, bony septum	None	Recurrence after post-op 4 years. 2 <sup>nd</sup> surgery required (the right Sylvian approach)	Improved visual acuity after 1 <sup>st</sup> surgery. Represented at 4 years with decreased visual acuity. Resolved after the second surgery
Yasuda et al. 2005 <sup>[49]</sup>	44	67	M	Headaches, decreased visual acuity and hypopituitarism	Endonasal transsphenoidal surgery	Adipose tissue; cartilage, fibrin glue	None	No recurrence at 6 mos	Headache and visual acuity improved and hypopituitarism did not improve

(Contd...)



Table 2: (Continued).

Authors	No of patients	Mean age, years	Sex	Clinical presentation	Surgical approach	Reconstruction method	Complications	Recurrence	Outcome
Dubuisson <i>et al.</i> (2007) <sup>[9]</sup>	45–53	Mean 45	5 M 4 F	Headaches (2), decreased visual acuity (3), hypopituitarism (5), incidental (2), hyperprolactinemia (3), panhypopituitarism (1)	Microscopic TS	Adipose tissue, nasoseptal bone, biological glue	1 permanent DI, 2 CSF leak that required 2 <sup>nd</sup> surgery	No recurrence at a mean of 11 years	All patients with visual loss and 1 patient with headache improved. Hyperprolactinemia was normalised. Four patients with hypopituitarism, improved. Panhypopituitarism did not improve
Cavallo <i>et al.</i> , (2008) <sup>[6]</sup>	54–63	Mean 48.6	4 M 6 F	Headaches (2), decreased visual acuity (7), impotence (3), hyperprolactinaemia (2)	Endoscopic endonasal TS or microscopic TS assisted by endoscope	Adipose tissue and/or collagen sponge	1 case with CSF leak, 1 case with CSF leak and meningitis that required 2 <sup>nd</sup> surgery	Mean length of FU 36.9 mos. 1 recurrence at 16 mos required 2 <sup>nd</sup> surgery	All patients with decreased visual acuity and 1 patient's headaches improved. Hyperprolactinemia was normalised. Impotence did not improve
McLaughlin <i>et al.</i> , 2012 <sup>[25]</sup>	64–71	Mean 57	2 M 6 F	Headache (4), hypopituitarism (4), vision loss (4)	Endoscopic endonasal TS or microscopic TS assisted by endoscope	Fat graft, titanium micromesh, collagen sponge, tissue glue (either Tisseal or DuraSeal)	None	Mean FU 32 mos. 1 patient had symptomatic recurrence at 3 mos and required 2 <sup>nd</sup> surgery. 1 patient of asymptomatic partial recurrence at 29 mos	All patients with vision loss or headaches improved. Three patients with hypopituitarism partially improved
Park <i>et al.</i> , 2013 <sup>[34]</sup>	72	53	F	Headache, diabetes insipidus	Microscopic TS	Fat graft, Gelfoam, nasoseptal bone	CSF leakage, treated by LD with Duraseal™ (Covidien, Waltham, MA, USA) sealant application to the operation site via a nasal endoscope	No recurrence at 3 mos	No improvement in DI

(Contd...)

Table 2: (Continued).

Authors	No of patients	Mean age, years	Sex	Clinical presentation	Surgical approach	Reconstruction method	Complications	Recurrence	Outcome
Shim <i>et al.</i> , 2013 <sup>(40)</sup>	73–78	Mean 45	2 M 4 F	Decreased visual acuity (6), headache (2), hypopituitarism (4)	Transventricular endoscopic fenestration	NS	None	No recurrence at 12 mos	All patients with vision loss or headache improved. 3 of 4 patients endocrinological problem improved. 1 patient with DI no improved.
Oyama <i>et al.</i> , 2014 <sup>(33)</sup>	79–84	Mean 59	3 M 3 F	Decreased visual acuity (6)	TS cyst cysternostomy with a keyhole dural opening	Fascia lata, fat, dural suturing, fibrin glue	One CSF leak and meningitis treated by LD	1 recurrence at 42.2 mos	All patients with decreased visual acuity improved
Su <i>et al.</i> , 2015 <sup>(44)</sup>	85–87	Mean 51	1 M 2 F	Decreased visual acuity (3), headache (1)	Endoscopic endonasal cyst drainage cysternostomy	Dural suturing, sellar bone, a nasal septum bone, or artificial absorbable plate, BioGlue	None	No recurrence at 4–50 mos	Symptoms improved in all patients
Güdük <i>et al.</i> , 2016 <sup>(12)</sup>	88	49	M	Headache	Endoscopic transnasal TS	NS	None	No recurrence at 12 mos	Headache improved.
Ovenden <i>et al.</i> , 2019 <sup>(32)</sup>	89	45	F	Decreased visual acuity	Endoscopic transnasal TS	Duragen, nasoseptal bone, fibrin glue	Pituitary abscess that required reoperation	No recurrence at 6 mos	Decreased visual acuity improved after 2 <sup>nd</sup> surgery
Roca <i>et al.</i> , 2019 <sup>(37)</sup>	90–99	NS	NS	NS	Endoscopic transnasal TS	Abdominal fat graft	2 CSF leak that required 2 <sup>nd</sup> surgery	NS	NS
Tafreshi <i>et al.</i> , 2020 <sup>(45)</sup>	100–101	NS	NS	Headache (2), vision loss (2)	Endoscopic transnasal TS	Fat graft, fascia lata, fibrin glue	1 CSF leak	NS	Symptoms improved in all patients
d'Artigues <i>et al.</i> , 2021 <sup>(7)</sup>	102–118	49.5	5 M 12 F	Headache (8), visual disorder (11), hypopituitarism (3)	Endoscopic transnasal TS	Fat graft, surgical glue	2 CSF leak that required 2 <sup>nd</sup> surgery	1 recurrence at 24 mos	Improved visual function (10) and worsened (1) and improved headache (7), new DI (2), Hypopituitarism not improved-(3)
Kalyvas <i>et al.</i> , 2022 <sup>(21)</sup>	119–128	54.5	3 M 7 F	Headache (1), visual symptoms (8), hypopituitarism (2), hyperprolactinemia (3)	Endoscopic transnasal TS	Gelfoam, nasoseptal bone, fibrin glue	New DI (1), new hypopituitarism (1)	1 recurrence at 54 mos	Improved visual function (8) and worsened (1), improved headache (1), 1 patient with hypopituitarism improved, hyperprolactinemia was normalized

NS: Not specified, CSF: Cerebrospinal fluid, DI: Diabetes insipidus, LD: Lumbar drainage, FU: Follow-up, TS: Transsphenoidal surgery, Post-op: postoperative, M: Male, F: Female

intrasellar ACs with suprasellar extension.<sup>[17,25,27,40]</sup> The choice of surgical approach (transsphenoidal or transcranial) in the treatment of patients with intrasellar/sellar ACs remains controversial.<sup>[28,33]</sup>

In the treatment of sellar ACs, the endoscopic transsphenoidal approach is less invasive than transcranial approaches. Moreover, the endoscope provides better visualization of the supra- and parasellar spaces.<sup>[6,33,45]</sup>

Due to its advantages, the transsphenoidal transnasal approach using a microscope or endoscope is the most reasonable option for the treatment of sellar ACs. Below is described the work of several authors who have applied the method of TS in the treatment of these cysts.<sup>[4,9,16,17,22,26,27,42]</sup>

In most clinical cases, until recently, the microscopic transsphenoidal approach was used more often, but Cavallo *et al.* mentioned the advantage of the endoscope in the transsphenoidal treatment of sellar cystic lesions. Due to its panoramic view, the endoscope allows a much wider visualization of the suprasellar cistern and the entire cavity, which enables better examination of the cyst cavity, by studying all the walls of the cyst, to exclude signs of a cystic tumor.<sup>[6]</sup>

In the treatment of intrasellar arachnoid cyst by TS, the intrasellar part of the cyst is drained, to prevent CSF leakage and recurrence, sellar floor is filled with fat or muscle.

A preoperative sagittal view of an MRI of the brain must be carefully examined to determine the position of the pituitary stalk and the relationship between the vascular structures behind the dorsum sellae.<sup>[44]</sup>

Oyama *et al.* described the method based on an extended TS for supra- and parasellar lesions using a microscope. This work described a keyhole dural incision wide enough to safely perform a cyst cisternostomy using an angled endoscope. The dural defect was reconstructed using fascia lata and six to eight sutures with 6-0 nylon monofilament. Moreover, the use of the 30° or 70° angled thin endoscope enables the determination of the position of the Acom complex and the optic apparatus, to avoid iatrogenic damage. One patient had CSF leakage and meningitis, which were successfully treated with conservative therapy with lumbar drainage (LD) and intravenous antibiotics. Out of the seven cases, there was no recurrence, and no reoperation was required for CSF leakage. Preoperative visual disturbance improved after surgery.<sup>[33]</sup>

The clinical presentation of 128 cases with sellar/suprasellar ACs is summarized in Table 2.<sup>[4,7,9,11-14,16,21,22,25-28,31-34,37,38,40-42,44,45,47-49]</sup> The 50 males and 66 females were aged 16–80. Headache 44 patients and visual disturbance 78 patients were the complaints of most patients. Endocrine symptoms were encountered in a minority of cases: Complaints were of the gonadotropic axis, including menstrual

irregularities, infertility, decreased libido, or impotence. 23 patients demonstrated hypopituitarism. Five patients demonstrated panhypopituitarism, and twelve demonstrated hyperprolactinemia. Six incidental cases of the cyst were noted while X-ray examinations had been performed because of head trauma or epilepsy and upper limb paraesthesia. X-rays showed a sellar abnormality. Most commonly, treatment of these lesions by a transsphenoidal approach using an endoscope or microscope has been reported.

Postoperative CSF leakage is a major complication of TS. Eighteen of the 128 reported cases developed CSF leakage, with most of them requiring second surgery or LD.<sup>[4,6,7,9,14,31,33,34,37,38,42,45]</sup> In addition, serious complications have been reported, including two deaths from *Klebsiella meningitis*<sup>[26]</sup> and septic shock,<sup>[22]</sup> and postoperative visual loss<sup>[42]</sup> due to prolapse of the OCh into the sellar cavity. The patient was reoperated to refill the sellar floor, but the vision did not improve. Complications after TS for the AC are more common than those reported after surgery on pituitary adenomas.<sup>[40]</sup> The careful hermetic reconstruction of the sellar floor prevents complications such as CSF leakage. In addition to this complication, in previously reported cases, there was an improvement in the following preoperative symptoms: Vision, headache, and to some extent, endocrine abnormalities after surgery in the majority of patients.

In most cases, the surgical treatment of sellar/suprasellar ACs is successful, but according to some sources, there are reports of recurrence.<sup>[6,14,25,28,33,41]</sup> McLaughlin *et al.* Reported two recurrences among eight patients. During the reoperation, the vast majority of fat was noticed to be reabsorbed, and there is a wide communication between the subarachnoid space and the cavity of the AC.<sup>[25]</sup> Long-term observation is required after cyst surgery due to frequent recurrence.<sup>[28]</sup>

## CONCLUSION

The endoscopic transnasal transsphenoidal approach remains a minimally invasive and the preferred approach for the treatment of sellar/suprasellar ACs. To maintain the patency of CSF flow through the AC, the lamina terminalis was perforated in addition to the anterior wall fenestration. This perforation can prevent the recurrence of the AC. Hermetically reconstructing the sellar floor and continuous dural suturing with fat graft is effective in preventing CSF leakage and does not require additional procedures such as the placement of a lumbar drain and the insertion of a nasal septal flap.

## Declaration of patient consent

Patient's consent not required as patient's identity is not disclosed or compromised

## Financial support and sponsorship

Nil.

## Conflict of interest

There are no conflict of interest.

## REFERENCES

- Aljuboori Z, Burke W, Yeo H, McCallum A, Clark J, Williams B. Orbitofrontal approach for the fenestration of a symptomatic sellar arachnoid cyst. *Surg Neurol Int* 2020;11:10.
- Amano K, Hori T, Kawamata T, Okada Y. Repair and prevention of cerebrospinal fluid leakage in transsphenoidal surgery: A sphenoid sinus mucosa technique. *Neurosurg Rev* 2016;39:123-31; discussion 131.
- Aoki N, Sakai T. Intraoperative subdural hematoma in a patient with arachnoid cyst in the middle cranial fossa. *Childs Nerv Syst* 1990;6:44-6.
- Baskin DS, Wilson CB. Transsphenoidal treatment of non-neoplastic intrasellar cysts. A report of 38 cases. *J Neurosurg* 1984;60:8-13.
- Benedetti A, Carbonin C, Colombo F. Possible aetiopathogenetic correlation between primary empty sella and arachnoid cyst. *Acta Neurochir (Wien)* 1977;38:269-78.
- Cavallo LM, Prevedello D, Esposito F, Laws ER Jr, Dussick JR, Messina A, *et al.* The role of the endoscope in the transsphenoidal management of cystic lesions of the sellar region. *Neurosurg Rev* 2008;31:55-64; discussion 64.
- d'Artigues J, Graillon T, Boissonneau S, Farah K, Amodru V, Brue T, *et al.* Fully endoscopic endonasal approach for the treatment of intrasellar arachnoid cysts. *Pituitary* 2022;25:191-200.
- Dawkins RL, Hackney JR, Riley KO. Penetration of an optic nerve by a sellar/suprasellar arachnoid cyst. *World Neurosurg* 2016;87:662.e7-11.
- Dubuisson AS, Stevenaert A, Martin DH, Flandroy PP. Intrasellar arachnoid cysts. *Neurosurgery* 2007;61:505-13.
- Elliott RE, Tanweer O, Rubin BA, Koslow M, Mikolaenko I, Wisoff JH. Suprasellar hamartoma and arachnoid cyst. *World Neurosurg* 2013;80:e401-7.
- Fujiwara M, Bitoh S, Hasegawa H, Ohtsuki H. A case of intrasellar arachnoid cyst. *No Shinkei Geka* 1984;12 Suppl 3:331-7.
- Güdük M, HamitAytar M, Sav A, Berkman Z. Intrasellar arachnoid cyst: A case report and review of the literature. *Int J Surg Case Rep* 2016;23:105-8.
- Harter LP, Silverberg GD, Brant-Zawadzki M. Intrasellar arachnoid cyst: Case report. *Neurosurgery* 1980;7:387-90.
- Hasegawa M, Yamashita T, Yamashita J, Kuroda E. Symptomatic intrasellar arachnoid cyst: Case report. *Surg Neurol* 1991;35:355-9.
- Horiguchi K, Murai H, Hasegawa Y, Hanazawa T, Yamakami I, Saeki N. Endoscopic endonasal skull base reconstruction using a nasal septal flap: Surgical results and comparison with previous reconstructions. *Neurosurg Rev* 2010;33:235-41.
- Hornig GW, Zervas NT. Slit defect of the diaphragma sellae with valve effect: Observation of a "slit valve". *Neurosurgery* 1992;30:265-7.
- Iqbal J, Kanaan I, Al Homsy M. Non-neoplastic cystic lesions of the sellar region presentation, diagnosis and management of eight cases and review of the literature. *Acta Neurochir (Wien)* 1999;141:389-97.
- Ishii Y, Tahara S, Oyama K, Kitamura T, Teramoto A. Easy slip-knot: A new simple tying technique for deep sutures. *Acta Neurochir (Wien)* 2011;153:1543-5; discussion 1545.
- Ishikawa T, Takeuchi K, Nagata Y, Choo J, Kawabata T, Ishizaki T, *et al.* Three types of dural suturing for closure of CSF leak after endoscopic transsphenoidal surgery. *J Neurosurg* 2019;131:1625-31.
- Jho HD, Carrau RL. Endoscopy assisted transsphenoidal surgery for pituitary adenoma. Technical note. *Acta Neurochir (Wien)* 1996;138:1416-25.
- Kalyvas A, Milesi M, Leite M, Yang K, St Jacques L, Vescan A, *et al.* Endoscopic treatment of sellar arachnoid cysts via a simple cyst-opening technique: Long-term outcomes from a single center. *World Neurosurg* 2022;161:e625-34.
- Leo JS, Pinto RS, Hulvat GF, Epstein F, Kricheff II. Computed tomography of arachnoid cysts. *Radiology* 1979;130:675-80.
- Mangussi-Gomes J, Gentil AF, Filippi RZ, Momesso RA, Handfas BW, Radvany J, *et al.* Sellar and suprasellar arachnoid cyst. *Einstein (Sao Paulo)* 2019;17:eAI4269.
- Matmusaev M, Kumar RS, Yamada Y, Nagatani T, Kawase T, Tanaka R, *et al.* Endoscopic microvascular decompression for hemifacial spasm. *Asian J Neurosurg* 2020;15:833-8.
- McLaughlin N, Vandergrift A, Ditzel Filho LF, Shahlaie K, Eisenberg AA, Carrau RL, *et al.* Endonasal management of sellar arachnoid cysts: Simple cyst obliteration technique. *J Neurosurg* 2012;116:728-40.
- Meyer FB, Carpenter SM, Laws ER Jr. Intrasellar arachnoid cysts. *Surg Neurol* 1987;28:105-10.
- Miyamoto T, Ebisudani D, Kitamura K, Ohshima T, Horiguchi H, Nagahiro S. Surgical management of symptomatic intrasellar arachnoid cysts-two case reports. *Neurol Med Chir (Tokyo)* 1999;39:941-5.
- Murakami M, Okumura H, Kakita K. Recurrent intrasellar arachnoid cyst. *Neurol Med Chir (Tokyo)* 2003;43:312-5.
- Nagata Y, Watanabe T, Nagatani T, Takeuchi K, Chu J, Wakabayashi T. The multiscope technique for microvascular decompression. *World Neurosurg* 2017;103:310-4.
- Nishioka H, Izawa H, Ikeda Y, Namatame H, Fukami S, Haraoka J. Dural suturing for repair of cerebrospinal fluid leak in transnasal transsphenoidal surgery. *Acta Neurochir (Wien)* 2009;151:1427-30.
- Nomura M, Tachibana O, Hasegawa M, Kohda Y, Nakada M, Yamashita T, *et al.* Contrast-enhanced MRI of intrasellar arachnoid cysts: Relationship between the pituitary gland and cyst. *Neuroradiology* 1996;38:566-8.
- Ovenden CD, Almeida JP, Oswari S, Gentili F. Pituitary abscess following endoscopic endonasal drainage of a suprasellar arachnoid cyst: Case report and review of the literature. *J Clin Neurosci* 2019;68:322-8.
- Oyama K, Fukuhara N, Taguchi M, Takeshita A, Takeuchi Y, Yamada S. Transsphenoidal cyst cisternostomy with a keyhole dural opening for sellar arachnoid cysts: Technical note. *Neurosurg Rev* 2014;37:261-7.

34. Park KH, Gwak HS, Hong EK, Lee SH. Inflamed symptomatic sellar arachnoid cyst: Case report. *Brain Tumor Res Treat* 2013;1:28-31.
35. Pierre-Kahn A, Capelle L, Brauner R, Sainte-Rose C, Renier D, Rappaport R, *et al.* Presentation and management of suprasellar arachnoid cysts. Review of 20 cases. *J Neurosurg* 1990;73:355-9.
36. Rappaport ZH. Suprasellar arachnoid cysts: Options in operative management. *Acta Neurochir (Wien)* 1993;122:71-5.
37. Roca E, Penn DL, Safain MG, Burke WT, Castlen JP, Laws ER. Abdominal fat graft for sellar reconstruction: Retrospective outcomes review and technical note. *Oper Neurosurg (Hagerstown)* 2019;16:667-74.
38. Saeki N, Tokunaga H, Hoshi S, Sunada S, Sunami K, Uchino F, *et al.* Delayed postoperative CSF rhinorrhea of intrasellar arachnoid cyst. *Acta Neurochir (Wien)* 1999;141:165-9.
39. Shim KW, Lee YH, Park EK, Park YS, Choi JU, Kim DS. Treatment option for arachnoid cysts. *Childs Nerv Syst* 2009;25:1459-66.
40. Shim KW, Park EK, Lee YH, Kim SH, Kim DS. Transventricular endoscopic fenestration of intrasellar arachnoid cyst. *Neurosurgery* 2013;72:520-8.
41. Shin JL, Asa SL, Woodhouse LJ, Smyth HS, Ezzat S. Cystic lesions of the pituitary: Clinicopathological features distinguishing craniopharyngioma, Rathke's cleft cyst, and arachnoid cyst. *J Clin Endocrinol Metab* 1999;84:3972-82.
42. Spaziante R, de Divitiis E, Stella L, Cappabianca P, Donzelli R. Benign intrasellar cysts. *Surg Neurol* 1981;15:274-82.
43. Stein SC. Intracranial developmental cysts in children: Treatment by cystoperitoneal shunting. *Neurosurgery* 1981;8:647-50.
44. Su Y, Ishii Y, Lin CM, Tahara S, Teramoto A, Morita A. Endoscopic transsphenoidal cisternostomy for nonneoplastic sellar cysts. *Biomed Res Int* 2015;2015:389474.
45. Tafreshi AR, Du R, Rutkowski MJ, Donoho DA, Shiroishi MS, Liu CJ, *et al.* Differential clinical presentation, intraoperative management strategies, and surgical outcomes after endoscopic endonasal treatment of cystic sellar masses. *World Neurosurg* 2020;133:e241-51.
46. Takeuchi K, Nagatani T, Wakabayashi T. How I do it: Shoelace watertight dural closure in extended transsphenoidal surgery. *Acta Neurochir (Wien)* 2015;157:2089-92.
47. Tanaka Y, Hayashi S, Nakai M, Ryujin Y, Uematsu Y, Nakai K, *et al.* Intrasellar arachnoid cyst: A case report. *No Shinkei Geka* 1995;23:801-6.
48. Weil RJ. Rapidly progressive visual loss caused by a sellar arachnoid cyst: Reversal with transsphenoidal microsurgery. *South Med J* 2001;94:1118-21.
49. Yasuda K, Saitoh Y, Okita K, Morris S, Moriwaki M, Miyagawa J, *et al.* Giant intrasellar arachnoid cyst manifesting as adrenal insufficiency due to hypothalamic dysfunction-case report. *Neurol Med Chir (Tokyo)* 2005;45:164-7.

**How to cite this article:** Matmusaev M, Watanabe T, Iwami K, Akhmediev T. Endoscopic transnasal transsphenoidal management of sellar/suprasellar arachnoid cyst: A case report and literature review. *Surg Neurol Int* 2023;14:131.

## Disclaimer

The views and opinions expressed in this article are those of the authors and do not necessarily reflect the official policy or position of the Journal or its management. The information contained in this article should not be considered to be medical advice; patients should consult their own physicians for advice as to their specific medical needs.